

Fetal Skeletal Lethal Dysplasia: Case Report

Displasia Esquelética Letal Fetal: Relato de Caso

Alexandre Mello Savoldi^{1,2,3} Maria Auxiliadora Monteiro Villar^{1,2,3} Heloisa Novaes Machado^{2,4}
 Juan C. Llerena Júnior^{1,2,3,5,6}

¹Center for Medical Genetics and Center for Rare Diseases, Instituto Nacional Fernandes Figueira (IFF), Fundação Oswaldo Cruz (Fiocruz), Rio de Janeiro, RJ, Brazil

²Latin American Collaborative Study of Congenital Malformations (ECLAMC), Hospital A05, Instituto Nacional Fernandes Figueira (IFF), Fiocruz, Rio de Janeiro, RJ, Brazil

³Reference Center for Osteogenesis Imperfecta (CROI), Instituto Nacional Fernandes Figueira (IFF), Fiocruz, Rio de Janeiro, RJ, Brazil

⁴Pathological Anatomy Service, Instituto Nacional Fernandes Figueira (IFF), Fundação Oswaldo Cruz (Fiocruz), Rio de Janeiro, RJ, Brazil

⁵Instituto Nacional de Genética Médica Populacional (Inagemp), Rio de Janeiro, RJ, Brazil

⁶Fundação Arthur Sá Erp, Faculdade de Medicina de Petrópolis, Rio de Janeiro, RJ, Brazil

Address for correspondence Juan Clinton Llerena Jr., MD, PhD, Instituto Nacional Fernandes Figueira, IFF/Fiocruz, Av. Rui Barbosa, 716, 22.250-020 - Rio de Janeiro, RJ, Brasil (e-mail: llerena@iff.fiocruz.br).

Rev Bras Ginecol Obstet 2017;39:576–582.

Abstract

Keywords

- ▶ pregnancy
- ▶ skeletal dysplasia
- ▶ osteogenesis imperfecta
- ▶ prenatal period
- ▶ genetic syndromes

The clinical management and decision-making in pregnancies in which there is suspicion of lethal fetal malformations during the prenatal period, such as lethal skeletal dysplasia (SD), demand a multidisciplinary approach coordinated by an experienced physician. Based on the presentation of a case of osteogenesis imperfecta type IIA, we offer and discuss recommendations with the intention of organizing clinical and laboratory investigations aiming toward the clinical management, prognosis, and etiological diagnosis of these malformations, as well as genetic counselling to patients who wish to become pregnant.

Resumo

Palavras-chave

- ▶ gravidez
- ▶ displasia esquelética
- ▶ osteogênese imperfeita
- ▶ período pré-natal
- ▶ síndromes genéticas

O manejo clínico e a tomada de decisões médicas em gestantes com suspeita de malformação letal em um feto no período pré-natal, tal qual uma displasia esquelética letal, demandam uma abordagem multidisciplinar coordenada por um médico experiente. Baseado na apresentação de um caso de osteogênese imperfeita tipo IIA, recomendações são apresentadas e discutidas com a intenção de organizar as investigações clínicas e laboratoriais visando o manejo clínico, o prognóstico, e o diagnóstico etiológico dessas malformações, e o aconselhamento genético para as pacientes que desejam engravidar.

Introduction

Skeletal dysplasias (SDs), or osteochondrodysplasias (OCDs), are a group of bone disorders with clinical and etiological

heterogeneous characteristics. They affect the bone tissue and cartilage, resulting in changes in the growth, shape and development of the skeletal system. The OCDs can be very rare; however, as a group, their prevalence is estimated at

received
 December 13, 2016
 accepted
 April 4, 2017
 published online
 August 7, 2017

DOI <https://doi.org/10.1055/s-0037-1603943>.
 ISSN 0100-7203.

Copyright © 2017 by Thieme Revinter Publicações Ltda, Rio de Janeiro, Brazil

License terms



around 2.4 per 10,000 live births^{1,2}, with the lethal SD forms corresponding to 0.95-1.5 per 10,000 births.¹⁻³ It is known that there are more than 456 entities classified into 40 categories by their cardinal features (radiological findings, molecular etiology, inheritance), among which 40% can be already detected in the perinatal period, representing 9 deaths per 1,000 births.^{1,4}

Osteogenesis imperfecta type II (OI type II) comprises 14% of lethal SDs, and is the second most common cause, among thanatophoric dysplasia (26%) and the achondrogenesis (9%) group, which represents 40-60% of all lethal SDs.^{1,5-7} Osteogenesis imperfecta type II is a genetic disorder of the connective tissue characterized by severe bone fragility, susceptibility to severe deformities, and the occurrence of several pathological fractures, with predominance of de novo autosomal dominant inheritance caused by mutations in genes *COL1A1* and *COL1A2*.⁸ Multiple fractures are frequent in utero, and perinatal death occurs in the majority of cases,⁹ where most prenatal diagnosis are suspected primarily by early fetal ultrasound, and confirmed by skeletal radiography, autopsy and, less frequently, by molecular tests.

Due to the suspicion of a presumptive diagnosis of SD based on early gestational ultrasound findings, a range of clinical diagnosis with different outcomes may be considered. Based on the severity of the condition, such considerations and observations can impose difficulties to an appropriate clinical management of these fetuses, the pregnant women, and their families regarding genetic counselling.

In face of a medical emergency for the fetus with a presumed lethal SD, and the presence of a rather uniform gestational ultrasound phenotype among lethal SDs, clinical management guidelines become crucial. They may assist

physicians to define proper etiological diagnosis and clinical prognosis, as well as genetic counselling, once few of these genetic disorders may present with considerable recurrence risks.

This article aims, through the presentation of a clinical case of a lethal SD with radiological features (OI type IIA), to review the most common lethal SDs in the perinatal period, highlight their clinical and radiologic features, and compare the reported case with the literature. Furthermore, recommendations for the clinical management of similar cases are discussed.

Clinical Case Description

A 33-year-old pregnant woman in her 6th pregnancy, with 5 previous vaginal deliveries, was referred to our outpatient prenatal clinic due to a malformation in her fetus detected by an ultrasound in the Family Care Clinic. Her family history was unremarkable. A prenatal ultrasound fetal biometry at 23 weeks of pregnancy revealed an estimated fetal weight of 505 g and shortening of the long bones, so the hypothesis of an SD was considered. At 39 weeks of pregnancy, an ultrasound revealed an estimated fetal weight of 815 g and fetal malformations characterized by hypotelorism, short and saddled nose, micrognathia with redundancy of soft tissue in the face and neck, very short ribs, and narrow thoracic cage (→ Fig. 1a). Furthermore, it was possible to observe skeletal abnormalities with shortening of the limbs more pronounced in the femora and humeri. Fetal hypocalcification of the skull was evident, and complete and normal visualization of the encephalon, cerebral hemispheres, ventricles and the posterior fossa was apparently present. A fetal

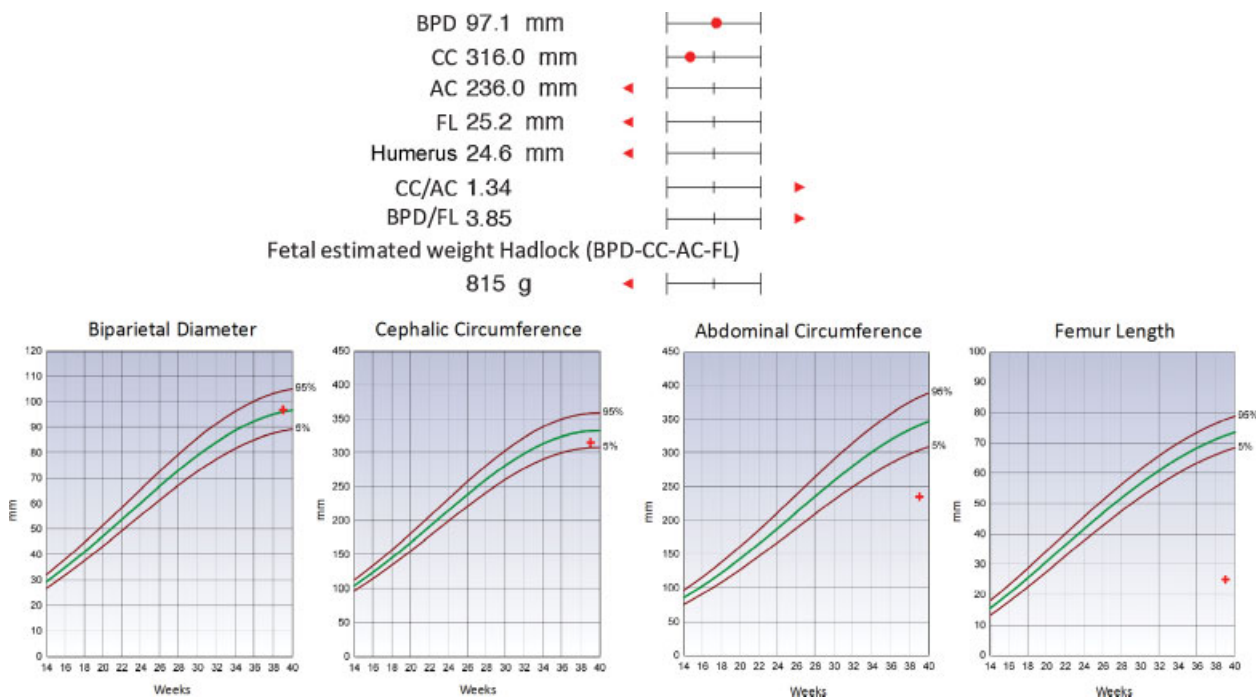


Fig. 1 Obstetric ultrasound and fetal development quantile curves of OI type IIA - 38 weeks.

echocardiography showed normal cardiac activity, with a thoracic diameter well below the third percentile, in addition to the presence of a mild to moderate tricuspid regurgitation. The small thoracic diameter suggested a high probability of severe pulmonary hypoplasia.

A history of Zika virus infection was suspected when the mother was 20 weeks and 4 days pregnant due to clinical manifestations described as arthralgia during 10 days, moderate fever, and erythematous exanthema spots on the body. Real-time polymerase chain reaction (PCR) for Zika virus could not be performed.

At 39 weeks and 3 days of gestational age, the patient delivered a singleton male live newborn with facial malformation and very short limbs. The Apgar score was 1 for the 1st minute of life, and 0 for the 5th minute. The newborn died due to cardiorespiratory arrest 15 minutes after birth. A post-mortem examination of the baby was performed after we obtained the parents' authorization, and it included skeletal X-ray scans. Genetic molecular tests were not performed (►Fig. 2).

The anatomopathological study revealed a deformed neonate boy measuring 38 cm (below the 3rd percentile) and weighing 1,800 g (below the 3rd percentile), with extreme shortening of all members. The skull was very soft, with no cranium ossification, and visualization of the meninges was evident. A narrow thoracic cage was present, and the shortening and deformities of the limbs were significant. The internal examination did not reveal any specific findings, except an important pulmonary hypoplasia (►Fig. 2).

The radiographic images of the skeleton showed extreme shortening and deformity of the long bones with severe loss of ossification, especially on the skull. The bones, in general, presented an abnormal morphology, with "crumpled"

humeri and femora, abnormally shaped ribs containing numerous fractures ("pearl appearance"), and a vertebral column with flattened vertebrae (platyspondylia) (►Fig. 2).

Based on the clinical and radiological evidences, the patient was diagnosed as having OI type IIA (lethal form) (►Figs. 1, 2, 3).

Discussion

The lethal forms of SD represent a group of genetic disorders that are clinically and genetically heterogeneous, and whose cardinal manifestations are observed in the perinatal period with severe and prominent phenotypic features. The majority of deaths result from respiratory insufficiency due to pulmonary hypoplasia, with 23% of stillbirths and 32% of babies not surviving the first week of life.^{1,4} In a clinical routine basis, the diagnosis of lethal SD occurs more frequently in the second trimester of gestation, through ultrasound findings (85%) and changes related to bone mineral density, including pathological fractures, growth deficiency, rib abnormalities, bowing or shortening of the long bones, and abnormal skull ossification, can be observed.¹⁰ However, the ultrasonography findings do not always point to a specific SD, which may lead to an imprecise diagnosis, uncertainties and high expectations from the healthcare professionals and parents. In addition, due to the low incidence of lethal SDs, the presence of variable phenotypes, overlapping features and the lack of a positive family history, it is difficult to achieve a specific etiological diagnosis and, therefore, a clinical prognosis may be uncertain to access.

In the presence of an ultrasound finding indicative of a possible lethal SD, complementary tests can be of clinical

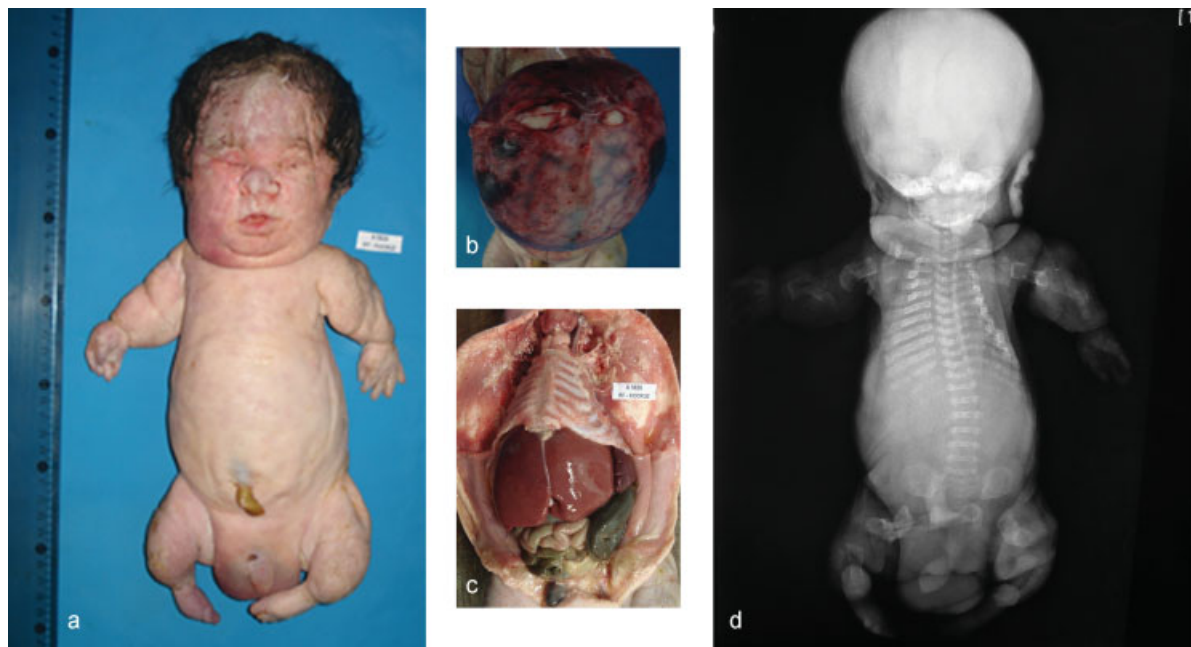

Fig. 2 (a) Patient ectoscopy: very short and deformed long bones; excess and wrinkled skin on a deformed face and neck; (b) non-ossification of the skull with transparent meninges; (c) extremely small thoracic cage; (d) typical babygram X-ray scan of a patient with a case of osteogenesis imperfecta type II.

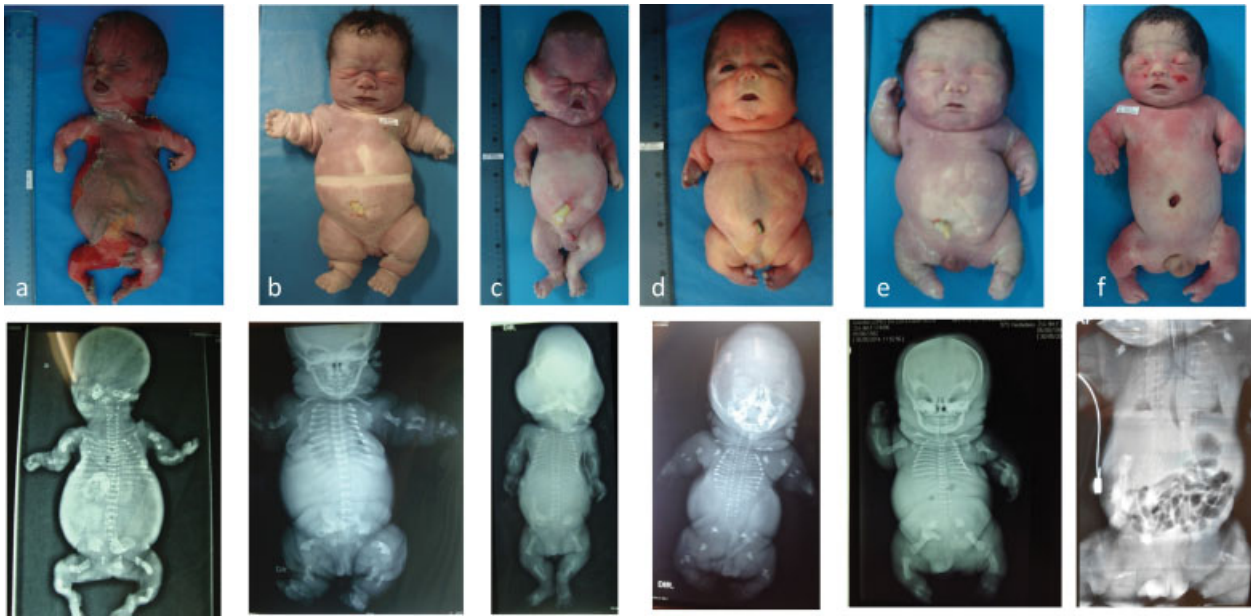


Fig. 3 Most common types of lethal skeletal dysplasias: (a) osteogenesis imperfecta type IIA; (b) thanatophoric dysplasia type I; (c) thanatophoric dysplasia type II (observe the “cloverleaf” skull); (d) achondrogenesis type I; (e) fibrochondrogenesis; (f) hypophosphatasia.

relevance to document each case, such as three-dimensional (3D) ultrasound, magnetic resonance imaging with 3D reconstruction, and invasive methods for collecting material for molecular investigation through DNA extraction from the amniotic fluid or cordocentesis.¹¹ In spite of being useful and of facilitating the visualization of the anatomical structures, there are exams that might be harmful to the fetus on account of the exposure to radiation, such as computed tomography, and others that present limitations in their interpretation due to the overlapping of fetal and maternal structures, such as the X-ray. However, the latter plays an extremely important role in the definition of phenotypic features in the post-natal period, especially when an SD is suspected. In addition to radiography, autopsy and collecting material for molecular investigation through fetal DNA analysis are ideal. Even so, in the absence of confirmatory genetic tests, a range of differential diagnoses of lethal SDs must be considered based on the clinical and radiological findings (► Fig. 3).

The most common lethal SDs are thanatophoric dysplasia, OI type II, and the achondrogenesis group, which comprise 40 to 60% of the cases (► Fig. 3). In a study conducted from 2010 to 2014, patients with a suspicion of SD were registered through the epidemiological birth defects program called Latin American Collaborative Study of Congenital Malformations (ECLAMC, in the Portuguese acronym).¹² The clinical and radiological examinations, as well as photographs, were evaluated when available based on a methodology with modifications proposed by Barbosa-Buck et al.¹³ Three different diagnostic evidence levels (DELs) were established: DEL-1 (good quality X-rays and/or positive genotype, and/or follow-up clinical information defining the diagnosis); DEL-2 (satisfactory description of the clinical and radiological examinations to establish one or more probable diagnoses);

and DEL-3- (clinical data and images with just enough quality to classify them as SDs).

Among 5,460 births, 1,452 newborns (26.6%) showed birth defects (2010–2014 ECLAMC survey, National Institute Fernandes Figueira). Among them, 32 babies (2%) had a suspicion of SD. The ultrasonographic diagnosis was suggestive in 93.7% of the pregnancies, and lethality during the prenatal period occurred in 81.2% of cases. In 50% of them, lethality was suspected after gestational ultrasounds. Out of 18 cases classified as DEL-1, 10 were of thanatophoric dysplasia (31.2%), 4 were of OI type II (12.5%) and there were 4 other cases each of diastrophic dysplasia, Verma-Naumoff syndrome, achondrogenesis and fibrochondrogenesis (► Table 1).^{14,15} Among the DEL-2 group, 6 cases had the following preliminary diagnosis: fibrochondrogenesis or Schneckbecken dysplasia; opsismodysplasia; diastrophic dysplasia group (atelosteogenesis); hypochondroplasia; hypochondrogenesis; and campomelic dysplasia (OMIM, 2016).¹⁶

Currently, with the increasing advance in molecular diagnosis, diagnostic hypotheses can be precisely confirmed or excluded, thereby improving the accuracy of the genetic counselling. Hence, the importance of detailed clinical records of SD cases, including clinical and epidemiological data, radiographs, photographs, and storage of biological material (paraffin block-embedded tissue for DNA extraction, for example) is essential. Gene sequencing or exome sequencing for a panel of genes related to SD are now available.¹⁷

Once an experienced clinician in lethal SDs confirms the diagnosis, genetic counselling can be properly offered to the families.¹⁸ In an autosomal dominant inheritance disease, the risk of recurrence for an affected parent can be as high as 50%; for parents who are not affected, the risk is negligible, as in OI type II or in the thanatophoric dysplasia group, unless

Table 1 Clinical, radiological and genetic characteristics in different lethal skeletal dysplasias^{14,15}

Diagnosis (Online Mendelian Inheritance in Man [OMIM])	Clinical features	Radiographic characteristics	Gene	Mode of inheritance
Fibrochondrogenesis I (# 228520)	Rhizomelia, omphalocele, medial cleft palate, abnormal and flat nose	Enlarged metaphysis of the long bones, vertebrae in “pear” shape	<i>COL11A1</i>	AR (recessive)
Fibrochondrogenesis II (# 614524)	Midface hypoplasia, small and anteverted nostrils, short long bones, normal size of hands and feet, small thorax	Enlarged metaphysis of the long bones, short long bones, hypoplastic posterior vertebrae body, small thorax	<i>COL11A2</i>	AD (dominant) AR
Atelosteogenesis type I (# 108720)	Hypertelorism, flat nose, hypoplastic median face, equinovarus, and polydramnia	Absent humerus and fibula, 11 ribs, hypoplastic ischium pubis, delayed proximal and medial phalangeal ossification	<i>FLNB</i>	AD
Atelosteogenesis type II (# 256050)	Hypertelorism, flat nose, cleft palate, short neck, “sandal” gap between 1 and 2 toes, ulnar deviation of the thumbs	Platyspondylia, cervical kyphos, short ribs, dysplastic vertebrae, bifid humerus, glenoid hypoplasia	<i>SLC26A2</i>	AR
Atelosteogenesis type III (# 108721)	Polydactyly, narrow auditory conduit, hydrocephalus, low set ears	Better vertebrae ossification, uniformed ossified fibula, metacarpals and phalanges	<i>FLNB</i>	AD
Boomerang dysplasia (# 112310)	Hypertelorism, flat nose, hypoplastic nasal septum, short neck with loose skin, brachydactyly, hypoplastic nails	Delayed cranium ossification, “boomerang” shape of the femur	<i>FLNB</i>	AD
Short-rib syndrome type I (# 208500)	Preaxial polydactyly, syndactyly, hypoplastic penis and imperforate anus	Metaphyseal irregularities of the long bones with terminal “spikes,” small iliac bone, horizontal acetabular shaft, short and horizontal ribs	<i>Not defined</i>	AR
Short-rib syndrome type II	Medial cleft face, cleft palate, low set ears, brachydactyly, abnormal genitalia	Narrow thorax, short and horizontal ribs, highly inserted clavicle, oval tibia, premature ossification of humeral epiphysis	<i>IFT80</i>	AR
Short-rib syndrome type III (# 613091)	Short limbs, narrow and cylindrical thorax, short stature	Bowed femur and tibia, enlarged metaphysis with “spikes,” square iliac bone	<i>DYNC2H1</i>	DR (digenic recessive) AR
Short-rib syndrome type IV (# 613819)	Short stature, short limbs, narrow and cylindrical thorax	Short and horizontal ribs, highly inserted clavicles and small scapulae, bowed radius and humerus	<i>TTC21B</i>	AR

there is the possibility of occurrence of germinal mosaicism.¹⁹ When an autosomal recessive inheritance condition is established, such as hypophosphatasia or achondrogenesis, the parents are necessarily carriers, thus a 25% chance of recurrence may occur.

In the study by Barbosa-Buck et al,¹³ the association of advanced paternal age with de novo SD cases was shown, especially in the thanatophoric dysplasia group. In the pres-

ence of advanced paternal age, there is a higher risk of occurrence of new mutations (de novo) per generation compared with advanced maternal age, especially in men, due to the large number of cell divisions during spermatogenesis.¹⁴

If the diagnosis of an SD is certain, it is essential to assess whether it is classified as lethal, since we should instruct parents as to the severity of the condition. In the present case, the diagnosis of OI type IIA was established at the

postnatal period, due to radiological features consistent with the disease, such as extreme osteoporosis, presence of multiple fractures, “crumpled long bones,” absence of calcification of the skull, and blue sclera. Osteogenesis imperfecta type II, the most severe phenotype, has an incidence of ~ 1 to 2 cases per 100,000 live births,²⁰ and its effects can already be observed in the uterus. Based on subtle radiographic differences, Sillence et al²¹ subdivided the OI type II disorder into three further groups. Type IIA is characterized by short, broad crumpled femora and continuously beaded ribs; type IIB, by short, broad crumpled femora, but normal ribs or ribs with incomplete beading; and type IIC, by long, thin, inadequately modeled, rectangular long bones with multiple fractures, and thin, beaded ribs.¹⁵

The newborns with lethal SDs survive during a few days after birth, and rarely survive for more than one year; the treatment involves intensive support and ventilatory assistance. More than 60% of affected newborns die on the first day of life, and 80% die within a week.⁸ In most cases, death usually occurs from respiratory failure related to severe pulmonary hypoplasia, rib fractures or unstable thoracic cage, but it can also be caused by pneumonia, hemorrhages in the central nervous system, and associated malformations. The treatment should focus on the relief of the symptoms and on support. The importance of medical assistance aiming at the quality of life of the baby through a palliative treatment to relieve the pain by means of potent analgesics should be emphasized. As the majority of newborns die in the perinatal period, rapid and effective assistance is essential for the patients' comfort, with minimal handling due to the risk of fractures when it is the case, such as in this report of OI type IIA.

With the same importance, we must emphasize the relevance of medical documentation as much as radiological plates and photographs, especially in cases in which no etiological diagnosis has been established with certainty. The anatomopathological study is recommended in cases in which there is presence or suspicion of associated congenital malformations, such as polydactyly. Findings of internal malformations suggested by gestational ultrasound should be confirmed, and they contribute to the differential diagnosis of the lethal cases associated with congenital malformations, such as the short-rib polydactyly group¹⁵ (→ **Table 1**).

The prognosis of a lethal SD, due to the severity of the condition, is quite limited. The physician must be used to talking to parents about the possibility of a lethal case, which itself requires great sensitivity and empathy. The use of simple and accessible language facilitates the decision-making in the management and treatment of such cases. As there may be implications in the course of pregnancy and during the postnatal care, the parents should receive multidisciplinary support and adequate guidance regarding the continuation of pregnancy, the risks of recurrence for new pregnancies and the postnatal care, respecting the culture, religion and the laws of each community.

Clinical management and decision-making in cases in which a lethal disease is suspected in the prenatal period, such as a lethal SD, demands a multidisciplinary approach

coordinated by an experienced physician. Firstly, a “clinical descriptive” approach, instead of a “need for diagnosis” approach, is mostly recommended. Secondly, all efforts in collecting good quality documentation, including X-ray plates and photographic material, are essential. Thirdly, biological samples (amniotic fluid, blood, paraffin block-embedded tissue) for DNA extraction and posterior gene sequencing (exome panel or Sanger gene sequencing) should be stored; and, lastly, autopsy, including post-mortem X-ray plates, once the multiple congenital malformations suspected should be pursued. The genetic counselling for a case of lethal SD will be enormously enriched with the precise knowledge of the recurrence risks if each of these recommendations is fulfilled.

Acknowledgments

This case report and photographic documentation were approved for publication by the Ethical Committee Board of one of our institutions, under protocol numbers CAAE 0022.0.008.000-08 (*osteogenesis imperfecta*) and CAEE 59488716.1.1001.5269 (*ECLAMC*).

References

- 1 Camera G, Mastroiacovo P. Birth prevalence of skeletal dysplasias in the Italian Multicentric Monitoring System for Birth Defects. *Prog Clin Biol Res* 1982;104:441-449
- 2 Rasmussen SA, Bieber FR, Benacerraf BR, Lachman RS, Rimoin DL, Holmes LB. Epidemiology of osteochondrodysplasias: changing trends due to advances in prenatal diagnosis. *Am J Med Genet* 1996;61(01):49-58
- 3 Andersen PE Jr. Prevalence of lethal osteochondrodysplasias in Denmark. *Am J Med Genet* 1989;32(04):484-489
- 4 Orioli IM, Castilla EE, Barbosa-Neto JG. The birth prevalence rates for the skeletal dysplasias. *J Med Genet* 1986;23(04):328-332
- 5 Krakow D, Alanay Y, Rimoin LP, et al. Evaluation of prenatal-onset osteochondrodysplasias by ultrasonography: a retrospective and prospective analysis. *Am J Med Genet A* 2008;146A(15):1917-1924
- 6 Tretter AE, Saunders RC, Meyers CM, et al. Antenatal diagnosis of lethal skeletal dysplasias. *Am J Med Genet* 1998;75(05):518-522
- 7 Källén B, Knudsen LB, Mutchinick O, et al. Monitoring dominant germ cell mutations using skeletal dysplasias registered in malformation registries: an international feasibility study. *Int J Epidemiol* 1993;22(01):107-115
- 8 Basel D, Steiner RD. Osteogenesis imperfecta: recent findings shed new light on this once well-understood condition. *Genet Med* 2009;11(06):375-385
- 9 Huber MA. Osteogenesis imperfecta. *Oral Surg Oral Med Oral Pathol Oral Radiol Endod* 2007;103(03):314-320
- 10 Krakow D, Williams J III, Poehl M, Rimoin DL, Platt LD. Use of three-dimensional ultrasound imaging in the diagnosis of prenatal-onset skeletal dysplasias. *Ultrasound Obstet Gynecol* 2003; 21(05):467-472
- 11 Ruano R, Molho M, Roume J, Ville Y. Prenatal diagnosis of fetal skeletal dysplasias by combining two-dimensional and three-dimensional ultrasound and intrauterine three-dimensional helical computer tomography. *Ultrasound Obstet Gynecol* 2004;24(02):134-140
- 12 Castilla EE, Orioli IM. ECLAMC: the Latin-American collaborative study of congenital malformations. *Community Genet* 2004; 7(2-3):76-94
- 13 Barbosa-Buck CO, Orioli IM, da Graça Dutra M, Lopez-Camelo J, Castilla EE, Cavalcanti DP. Clinical epidemiology of skeletal dysplasias in South America. *Am J Med Genet A* 2012;158A(05): 1038-1045

- 14 Toriello HV, Meck JM. Professional Practice and Guidelines Committee. Statement on guidance for genetic counseling in advanced paternal age. *Genet Med* 2008;10(06):457–460
- 15 Jones KL, Jones MC, Del Campo M. *Smith's recognizable patterns of human malformation*. 7th ed. Philadelphia: Elsevier Saunders; 2013
- 16 OMIM® Online Mendelian Inheritance in Man [Internet]. Baltimore: McKusick-Nathans Institute of Genetic Medicine/Johns Hopkins University; 2016 [cited 2017 Jan 12]. Available from: <https://omim.org/>
- 17 Bonafe L, Cormier-Daire V, Hall C, et al. Nosology and classification of genetic skeletal disorders: 2015 revision. *Am J Med Genet A* 2015;167A(12):2869–2892
- 18 Krakow D, Lachman RS, Rimoin DL. Guidelines for the prenatal diagnosis of fetal skeletal dysplasias. *Genet Med* 2009;11(02):127–133
- 19 Comstock JM, Putnam AR, Sangle N, Lowichik A, Rose NC, Opitz JM. Recurrence of achondrogenesis type 2 in sibs: Additional evidence for germline mosaicism. *Am J Med Genet A* 2010;152A(07):1822–1824
- 20 van Dijk FS, Cobben JM, Kariminejad A, et al. Osteogenesis imperfecta: a review with clinical examples. *Mol Syndromol* 2011;2(01):1–20
- 21 Silience DO, Barlow KK, Garber AP, Hall JG, Rimoin DL. Osteogenesis imperfecta type II delineation of the phenotype with reference to genetic heterogeneity. *Am J Med Genet* 1984;17(02):407–423