

# Effectiveness of Transjugular Intrahepatic Portosystemic Shunt in Variceal Bleeding: An Audit from a Tertiary Care Center in North India

Arun Gupta<sup>1</sup> Ajay Mehta<sup>2</sup> Nitin Mishra<sup>1</sup> Rajendra Bansal<sup>1</sup> Ajit Yadav<sup>1</sup>

<sup>1</sup>Department of Interventional Radiology, Sir Ganga Ram Hospital, New Delhi, India

<sup>2</sup>Department of Radiology, Postgraduate Institute of Medical Sciences and Research, Chandigarh, India

Address for correspondence Arun Gupta, MD, Department of Interventional Radiology, Sir Ganga Ram Hospital, New Delhi, India (e-mail: [irdrarungupta@gmail.com](mailto:irdrarungupta@gmail.com)).

J Clin Interv Radiol ISVIR 2017;1:150–155.

## Abstract

Variceal bleeding is one of the most feared complications of cirrhosis and portal hypertension. Transjugular intrahepatic portosystemic shunt (TIPS) is an effective minimally invasive option to achieve adequate decompression of the portal system. The aim of the study was to assess the efficacy and complications of TIPS in patients presenting with variceal bleed. It was a retrospective study done in a tertiary care center in North India in cirrhotic patients with acute or recurrent variceal bleed who underwent TIPS from April 2010 to October 2013. All the patients were followed up till April 2014. We could successfully implant TIPS in 100% of our patients with 100% success rate in controlling variceal bleeding immediately and during the follow-up period. Our primary patency rate was 94.5% and overall patency rate was 100%. Major TIPS-related complication was hepatic encephalopathy in 20% of patients; 7 of 22 patients died during the follow-up period. TIPS is a safe and effective procedure for control of acute or recurrent variceal bleed. Emerging evidence in favor of early TIPS is further going to expand its indication in variceal bleed. Hepatic encephalopathy was the major procedure-related complication in our study consistent with previous literature reports.

## Keywords

- ▶ TIPS
- ▶ variceal bleed
- ▶ encephalopathy

## Introduction

Variceal bleeding is one of the grave complications of cirrhosis and is associated with significant morbidity and mortality. Approximately 30 to 70% patients with cirrhosis would have gastroesophageal varices with approximately one-third developing variceal bleed.<sup>1</sup>

Treatment options include control of bleeding locally with endoscopic techniques along with vasoactive drugs and antibiotics and reduction in portal pressure using either surgically created shunts or transjugular intrahepatic portosystemic shunt (TIPS).<sup>2,3</sup>

Endoscopic treatments are preferred initially. However, these fail to control bleeding in as many as 10 to 15% cases.<sup>4,5</sup>

TIPS can be highly effective alternative in such cases but can carry high mortality in the presence of poor liver function.<sup>6</sup>

The study was performed to assess the safety and effectiveness of TIPS in patients with variceal bleeding in a tertiary care center in North India.

## Materials and Methods

It is a retrospective study and included patients who underwent TIPS from April 2010 to October 2013. All the patients were followed up till April 2014. Cirrhotic patients with acute or recurrent variceal bleeding unresponsive to medical and endoscopic therapy were included in the study. Exclusion criteria included congestive heart failure, uncontrolled

received  
March 27, 2017  
accepted after revision  
May 1, 2017  
published online  
September 1, 2017

DOI <https://doi.org/10.1055/s-0037-1603888>.  
ISSN 2457-0214.

Copyright © 2017 by Indian Society of Vascular and Interventional Radiology

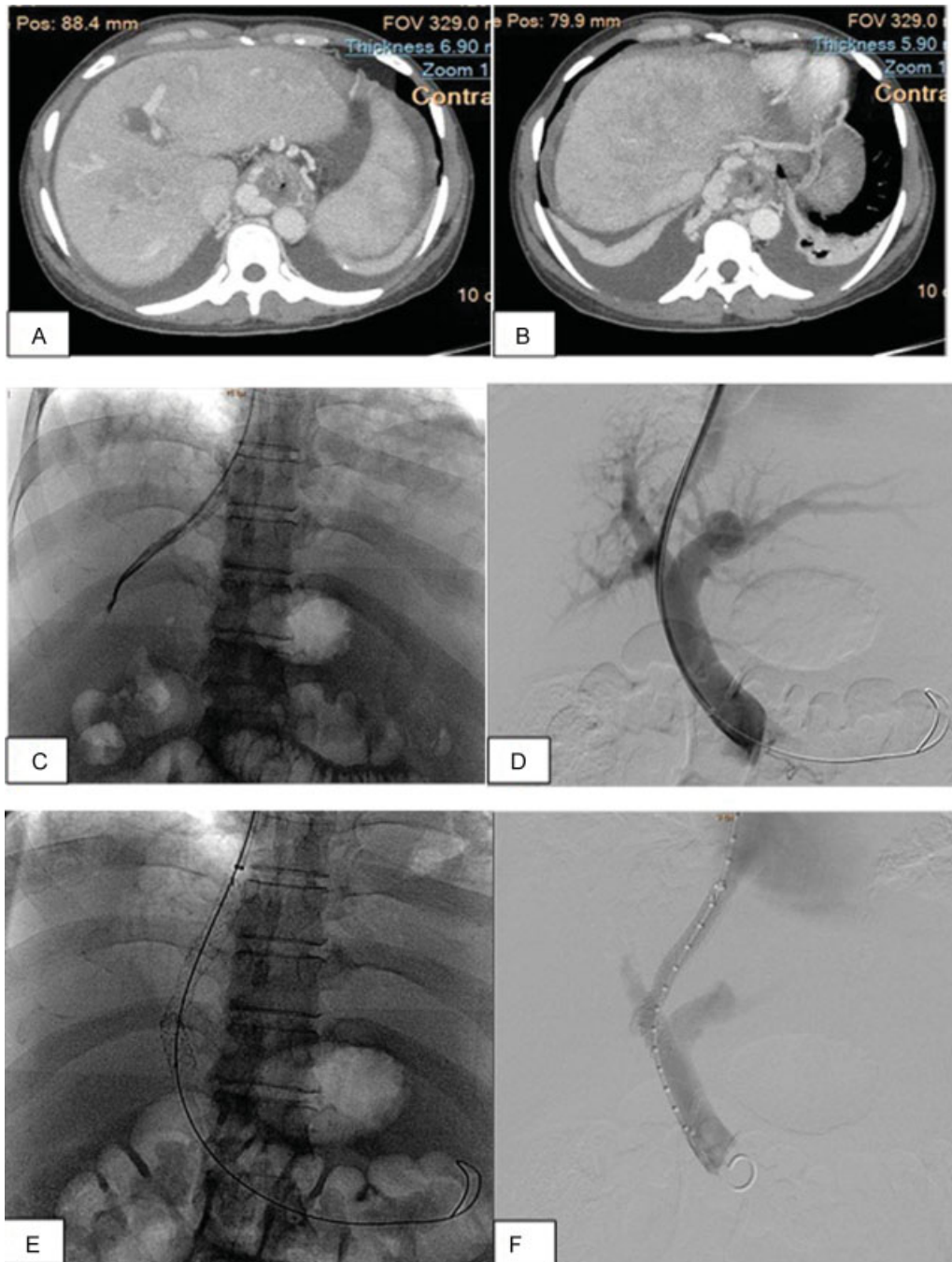
License terms



systemic infection or sepsis, severe coagulopathy (international normalized ratio [INR] >5), thrombocytopenia (< 20,000), portal vein thrombosis, and presence of hepatocellular carcinoma (HCC). Written informed consent was obtained prior to the procedure either from the patient or next of kin. All patients underwent complete blood count and coagulation screening tests and received broad-spectrum antibiotics. Any existing coagulopathy was corrected prior

to procedure. Preprocedure diagnostic workup also included ultrasound of the abdomen and computed tomographic (CT) venography if possible to assess for portal vein thrombosis and hepatoma. Elective and emergency TIPS placement was attempted who met inclusion criteria depending on the clinical evaluation.

The procedure (→Fig. 1) was performed in the angiography suite using a flat panel detector-based angiography



**Fig. 1** A 35-year-old woman follow-up case of CLD-cryptogenic, portal hypertension, recurrent upper GI bleeding (A, B) CT scan in portovenous phase shows heterogeneous enhancement of the hepatic parenchyma with partial atrophy of right lobe and lobulated irregular outlines suggestive of CLD with splenomegaly, ascites with multiple periesophageal, perigastric, and perisplenic collaterals. (C) Venogram image showing selective cannulation of right hepatic vein. (D) Portovenogram image showing dilated main portal vein and passage of guide wire across the RHV into RPV. (E) DSA image showing opening of the stent across the IVC, liver parenchyma, and portal vein. (F) Post stent check venogram showing free passage of contrast across the stent.

system (Philips ALLURA FD 20, Amsterdam, The Netherlands) using Doppler ultrasound (Logic E 9, General Electric, Boston, Massachusetts, United States) by interventional radiologist with 8 years of experience using Gore Viatorr stents (Gore, Newark, Delaware, United States).

Patients were followed for at least 6 months according to a standard protocol that included assessment of the following parameters:

1. Cessation of demonstrable gastrointestinal bleeding, that is, hematemesis, melena, or hematochezia.
2. Assessment of shunt patency with Doppler ultrasound.<sup>7</sup> Ultrasound criteria for shunt dysfunction included the following:
  - a. No flow, consistent with shunt thrombosis or occlusion
  - b. Peak shunt velocity:  $< 90$  or  $> 190$  cm/s
  - c. Change in peak shunt velocity: decrease of  $> 40$  cm/s or increase of  $> 60$  cm/s
  - d. Main portal vein velocity  $< 30$  cm/s
  - e. Reversal of flow in hepatic vein (HV) away from inferior vena cava (IVC), suggesting hepatic vein stenosis
3. Functional assessment of shunt.<sup>8</sup>
  - a. Primary patency was defined as a patent stent without reintervention.
  - b. Primary assisted patency—patent stent after reintervention but without occlusion at any time.
  - c. Secondary patency—patent stent after occlusion.
  - d. Shunt occlusion—the absence of flow at USG or angiography.
  - e. Definitive shunt loss was defined as an untreated or untreatable shunt occlusion.
4. Complications—postprocedure complications were divided into short ( $< 1$  week) and long term ( $> 1$  week).
5. Survival rate

All patients were given the option for orthotopic liver transplantation. Survival was assessed from the date of the procedure till the end of the study or death of the patient or liver transplant (whichever was earlier). The cause of death was noted for each patient. Assessment of stent function was performed with Doppler ultrasound at 1 week, 1 month, and 3 months after the TIPS placement, and regular follow-up was done at 3-month interval during the first year and every 6 months thereafter. Only the patients for whom follow-up for at least 12 months was available were included in the analysis. Patients were assessed clinically for symptoms and laboratory abnormalities. Statistical analysis was performed by the SPSS program for Windows, version 17.0 (IBM Corporation, Armonk, New York, United States).

## Results

Total 22 patients with variceal bleed were included in the study. Out of the 22 patients, 19 were males and 3 were females with the mean age of  $55.18 \pm 10.74$  years (range: 34–70 years). Fourteen patients were in Child-Pugh B category and 8 in Child-Pugh C. Mean number of endoscopic sessions prior to TIPS were 2.8. Twelve patients had TIPS

created electively whereas emergency TIPS was performed in 10 patients. In all the 22 patients, hepatic venous pressure gradient (HVPG) was measured before and after TIPS. Mean pressure gradient between the portal vein and the IVC before TIPS was  $27.25 \pm 8.15$  and that after TIPS was  $11.5 \pm 4.90$  ( $p < 0.001$ ). None of the patients had recurrent variceal bleeding following TIPS.

Two (2/22, 9%) patients died within the first week of the procedure due to sepsis. One patient died within 12 months and one had liver transplant within 12 months. The remaining 18 patients were followed for shunt patency. The 1-year primary patency was 94.5%. The 1-year secondary patency rate was 100%.

The frequency of late complications included liver failure in five (25%) patients, encephalopathy in four (20%), shunt dysfunction in one (5%), and renal failure in one (5%) patient. Out of the 22 patients, 7 died during the follow-up period. Two (28.7%) patients were in Child-Pugh B and remaining five (72.3%) belonged to Child-Pugh C. Kaplan-Meier survival curves based on Child-Pugh score showed higher mortality in Child-Pugh C class patients compared with Child-Pugh B class patients (► Fig. 2).

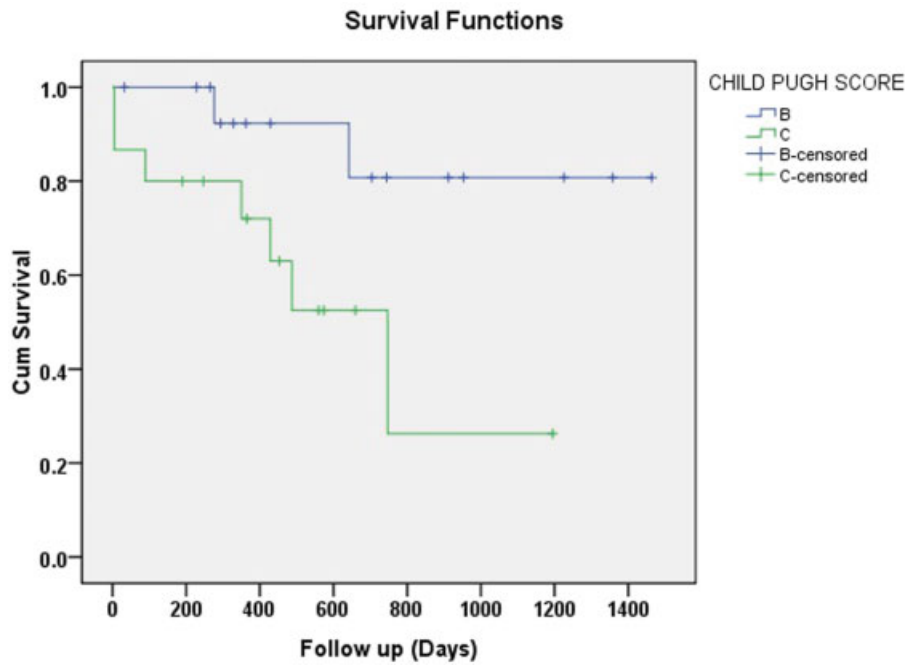
Eighteen (81.8%) patients had MELD (model for end-stage liver disease) score  $\leq 18$ , 3 (13.6%) had score between 19 and 25 and one (4.5%) patient had score  $> 26$ . Kaplan-Meier survival curves showed higher mortality in patients with MELD score  $> 18$ , compared with patients with score  $\leq 18$  (► Fig. 3).

## Discussion

Hepatic transplantation is not yet very popular in India owing to its high cost and poor availability of organ donors. TIPS remains an effective method of treating portal hypertension and its complications. The procedure has gained popularity because of its relative noninvasiveness and effectiveness in relieving portal hypertension and its complications such as intractable ascites, hydrothorax, and variceal bleeding.

Several factors have been postulated to cause a sudden increase in the portal pressure, such as excessive alcohol intake, postprandial increase in splanchnic circulation, and bacterial infection leading to acute variceal bleed. Presence of large varices with red signs,<sup>9</sup> HVPG  $> 20$  mm Hg,<sup>10</sup> and underlying severe liver disease<sup>11</sup> are associated with an increased risk of variceal bleeding. Initial management includes endoscopic and pharmacologic therapy and balloon tamponade. TIPS or surgically created shunt act as “rescue therapies” in case of refractory variceal bleeding.<sup>12</sup>

We could successfully create TIPS in all 22 patients in our cohort. Mean hepatic venous pressure decreased from  $27.25 \pm 8.15$  to  $11.5 \pm 4.90$  following TIPS. All 22 patients had cessation of any demonstrable variceal bleeding immediately post-TIPS without recurrence during the course of follow-up. Our results are similar to those reported in multiple other studies.<sup>13,14</sup> Furthermore, a study done by Boyer and Haskal<sup>15</sup> showed that the risk of rebleeding was 18%, 7%, and 1% when the reduction in the initial HVPG was 0%, 25 to

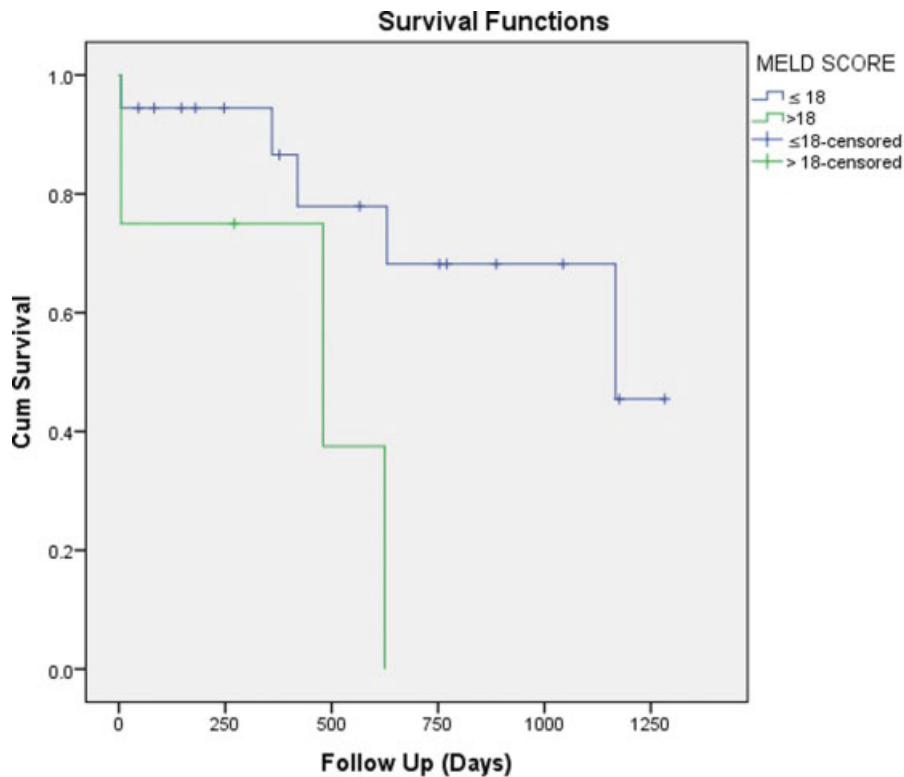


**Fig. 2** Survival according to Child-Pugh B and C class patients.

50%, and > 50%, respectively. Thus, pressure reduction of > 50% of the initial pressure signifies adequate decompression, which could be achieved in all of our patients.

Though TIPS is mainly used as rescue therapy in uncontrollable bleeding varices, recent data show that early TIPS place-

ment within 72 hours of variceal bleed in Child-Pugh C (10–13) cirrhosis and Child-Pugh B patients with acute variceal bleed had lower incidence of failure to control bleeding or rebleeding rate compared with endoscopic and pharmacological therapies alone (93 vs. 53%,  $p < 0.001$ ).<sup>16</sup> A randomized controlled



**Fig. 3** Survival according to MELD (model for end-stage liver disease) score.

trial also showed improved 1-year actuarial survival in early TIPS group compared with endoscopy-plus-pharmacotherapy group (86 vs. 61%,  $p < 0.001$ ).<sup>17</sup> This is further supported by a recent meta-analysis of four controlled trials that showed lower mortality and lower rate of clinically significant bleeding in 1 year.<sup>18</sup> Currently Baveno V consensus recommends TIPS within 72 hours in high-risk patients who are more prone to treatment failure after pharmacologic and endoscopic therapy.<sup>19</sup> However, the strongest evidence for placement of TIPS (level 1A) is in secondary prophylaxis of variceal bleeding.<sup>20,21</sup> Recent meta analyses showed threefold decrease in the risk of rebleeding compared with the endoscopic therapies, though there was no difference in all-cause mortality and there was more than twofold increase in rate of hepatic encephalopathy with TIPS.<sup>20,21</sup>

None of the patients in our cohort had intraprocedural intra-abdominal hemorrhage. This is a severe complication of TIPS that leads to rapid and fatal hemorrhagic shock. The incidence of such lethal complications has been reported to be around 4%.<sup>22</sup> Familiarity with the anatomy of the portal venous system is essential to avoiding such complications. In cirrhotic patients, the liver is shrunken and part of the right and left portal vein may lie outside the liver parenchyma. Puncture of the bare wall of right portal vein or hepatic capsule in the presence of ascites can lead to catastrophic abdominal hemorrhage and rapid deterioration of the patient. Absence of intracavitary hemorrhage in our study can be attributed to the routine use of ultrasound guidance for portal vein puncture and insistence on intrahepatic puncture 2 cm before the bifurcation of the right portal vein. Newer techniques and modifications to guide safe puncture such as electromagnetically guided creation of shunt,<sup>23</sup> image fusion-guided puncture using preprocedural 3D CT angiography, and real-time fluoroscopy<sup>24</sup> and endoscopic ultrasound (EUS)-guided puncture<sup>25</sup> are being developed and may prove promising in the future to further reduce intraprocedural hemorrhagic complication.

Two patients in our study died within 1 week of the procedure due to sepsis. Major late complications were liver failure in 25% patients and hepatic encephalopathy in 20% of patients. Our data are consistent with previous other studies that showed hepatic encephalopathy to be the most common complication attributable to placement of TIPS, seen in 15 to 48% patients.<sup>26</sup> Hepatic encephalopathy is usually a transient phenomenon, which decreases in frequency and intensity over time and can be effectively treated using dietary modifications and medications. Moreover, 3 to 7% patients who do not respond may require reduction or occlusion of the shunt.<sup>27</sup> All our patients could be medically managed without requirement of shunt reduction or occlusion. An interesting endovascular advancement in the management of refractory hepatic encephalopathy is placement of hour glass-shaped stent.<sup>28</sup> This leads to reduction in shunt flow leading to rapid improvement in patient's clinical condition with potential to modify shunt diameter, depending on the clinical condition of the patient.

The primary and secondary shunt patency rates in our study were 94.5% and 100%, respectively. The primary and

secondary patency rates in previous studies using polytetrafluoroethylene (PTFE)-covered stent grafts are reported to be around 76 to 84% and 98 to 100%, respectively.<sup>29-31</sup> Previously used bare metal stents were more prone to occlusions due to inadvertent bile duct puncture and formation of biliary-TIPS fistula. Higher shunt patency rate in our patients could be attributed to the utmost care taken while placing the stent at HV-IVC junction.

The cumulative survival rate in our study was 86.4% after 1 year, which is similar to that reported in previous studies.<sup>32</sup> In our study, mortality rate was higher in Child-Pugh C (72.3%) patients compared with Child-Pugh B (28.7%) patients, owing to already deranged liver function in Child-Pugh C patients. Mortality rate was also higher in patients with MELD score  $> 18$  (75%) compared with patients with score  $\leq 18$  (28.8%). The MELD score was found to be better predictor of post-TIPS mortality compared with the Child-Pugh score.<sup>33</sup> Other factors that increase the risk of post-TIPS mortality include serum bilirubin  $> 3$  mg/dL, preexisting encephalopathy, alanine transaminase (ALT) level  $> 100$  IU/L, and variceal hemorrhage requiring urgent TIPS placement. A recent retrospective study and randomized controlled trial analyzed the effect of TIPS placement in the right versus left portal vein and found that TIPS placed to the left portal vein was associated with lower mortality and reduced risk of hepatic encephalopathy.<sup>34,35</sup>

## Conclusion

TIPS is a safe and effective method of controlling acute refractory variceal bleeding. In addition, recent evidence emphasizing the role of early TIPS in the management of variceal bleeding and improved survival will further expand the role of TIPS in variceal bleeding. In our study hepatic encephalopathy was the major complication attributable to TIPS. Though none of our patients required shunt revision for hepatic encephalopathy, new adaptable stent design that could be individualized to the patient and placement of TIPS through the left portal vein may further decrease the incidence of hepatic encephalopathy. Also, routine use of ultrasound for portal vein puncture to prevent intraperitoneal hemorrhage and placement of stent at the HV-IVC junction to prevent outflow tract stenosis improves outcomes.

## References

- 1 Italian N; North Italian Endoscopic Club for the Study and Treatment of Esophageal Varices. Prediction of the first variceal hemorrhage in patients with cirrhosis of the liver and esophageal varices. A prospective multicenter study. *N Engl J Med* 1988;319(15):983-989
- 2 Garcia-Tsao G, Sanyal AJ, Grace ND, Carey WD; Practice Guidelines Committee of American Association for Study of Liver Diseases; Practice Parameters Committee of American College of Gastroenterology. Prevention and management of gastroesophageal varices and variceal hemorrhage in cirrhosis. *Am J Gastroenterol* 2007;102(9):2086-2102
- 3 de Franchis R; Franchis de. Evolving consensus in portal hypertension. Report of the Baveno IV consensus workshop on

- methodology of diagnosis and therapy in portal hypertension. *J Hepatol* 2005;43(01):167–176
- 4 Bosch J, Abraldes JG, Berzigotti A, Garcia-Pagan JC. Portal hypertension and gastrointestinal bleeding. *Semin Liver Dis* 2008;28(01):3–25
  - 5 D'Amico G, De Franchis R; Cooperative Study Group. Upper digestive bleeding in cirrhosis. Post-therapeutic outcome and prognostic indicators. *Hepatology* 2003;38(03):599–612
  - 6 Azoulay D, Castaing D, Majno P, et al. Salvage transjugular intrahepatic portosystemic shunt for uncontrolled variceal bleeding in patients with decompensated cirrhosis. *J Hepatol* 2001;35(05):590–597
  - 7 Owens CA, Bartolone C, Warner DL, et al. The inaccuracy of duplex ultrasonography in predicting patency of transjugular intrahepatic portosystemic shunts. *Gastroenterology* 1998;114(05):975–980
  - 8 ter Borg PC, Hollemans M, Van Buuren HR, et al. Transjugular intrahepatic portosystemic shunts: long-term patency and clinical results in a patient cohort observed for 3–9 years. *Radiology* 2004;231(02):537–545
  - 9 Bepko K, Inokuchi K, Koyanagi N, et al. Prediction of variceal hemorrhage by esophageal endoscopy. *Gastrointest Endosc* 1981;27(04):213–218
  - 10 Loffroy R, Estivalet L, Cherblanc V, et al. Transjugular intrahepatic portosystemic shunt for the management of acute variceal hemorrhage. *World J Gastroenterol* 2013;19(37):6131–6143
  - 11 North Italian Endoscopic Club for the Study and Treatment of Esophageal Varices. Prediction of the first variceal hemorrhage in patients with cirrhosis of the liver and esophageal varices. A prospective multicenter study. *N Engl J Med* 1988;319(15):983–989
  - 12 Qin JP, Jiang MD, Tang W, et al. Clinical effects and complications of TIPS for portal hypertension due to cirrhosis: a single center. *World J Gastroenterol* 2013;19(44):8085–8092
  - 13 García-Villarreal L, Martínez-Lagares F, Sierra A, et al. Transjugular intrahepatic portosystemic shunt versus endoscopic sclerotherapy for the prevention of variceal rebleeding after recent variceal hemorrhage. *Hepatology* 1999;29(01):27–32
  - 14 Boyer TD, Haskal ZJ. American Association for the Study of Liver Diseases Practice Guidelines: the role of transjugular intrahepatic portosystemic shunt creation in the management of portal hypertension. *J Vasc Interv Radiol* 2005;16(05):615–629
  - 15 Boyer TD, Haskal ZJ; American Association for the Study of Liver Diseases. The role of transjugular intrahepatic portosystemic shunt in the management of portal hypertension. *Hepatology* 2005;41(02):386–400
  - 16 García-Pagán JC, Di Pascoli M, Caca K, et al. Use of early-TIPS for high-risk variceal bleeding: results of a post-RCT surveillance study. *J Hepatol* 2013;58(01):45–50
  - 17 García-Pagán JC, Caca K, Bureau C, et al; Early TIPS (Transjugular Intrahepatic Portosystemic Shunt) Cooperative Study Group. Early use of TIPS in patients with cirrhosis and variceal bleeding. *N Engl J Med* 2010;362(25):2370–2379
  - 18 Deltente P, Trépo E, Rudler M, et al. Early transjugular intrahepatic portosystemic shunt in cirrhotic patients with acute variceal bleeding: a systematic review and meta-analysis of controlled trials. *Eur J Gastroenterol Hepatol* 2015;27(09):e1–e9
  - 19 de Franchis R; Baveno V Faculty. Revising consensus in portal hypertension: report of the Baveno V consensus workshop on methodology of diagnosis and therapy in portal hypertension. *J Hepatol* 2010;53(04):762–768
  - 20 Burroughs AK, Vangeli M. Transjugular intrahepatic portosystemic shunt versus endoscopic therapy: randomized trials for secondary prophylaxis of variceal bleeding: an updated meta-analysis. *Scand J Gastroenterol* 2002;37(03):249–252
  - 21 Zheng M, Chen Y, Bai J, et al. Transjugular intrahepatic portosystemic shunt versus endoscopic therapy in the secondary prophylaxis of variceal rebleeding in cirrhotic patients: meta-analysis update. *J Clin Gastroenterol* 2008;42(05):507–516
  - 22 Tripathi D, Helmy A, Macbeth K, et al. Ten years' follow-up of 472 patients following transjugular intrahepatic portosystemic shunt insertion at a single centre. *Eur J Gastroenterol Hepatol* 2004;16(01):9–18
  - 23 Isfort P, Penzkofer T, Wilkman C, et al. Feasibility of electromagnetically guided transjugular intrahepatic portosystemic shunt procedure. *Minim Invasive Ther Allied Technol* 2017;26(01):15–22
  - 24 Rouabah K, Varoquaux A, Caporossi JM, et al. Image fusion-guided portal vein puncture during transjugular intrahepatic portosystemic shunt placement. *Diagn Interv Imaging* 2016;97(11):1095–1102
  - 25 Buscaglia JM, Dray X, Shin EJ, et al. A new alternative for a transjugular intrahepatic portosystemic shunt: EUS-guided creation of an intrahepatic portosystemic shunt (with video). *Gastrointest Endosc* 2009;69(04):941–947
  - 26 Rössle M. TIPS: 25 years later. *J Hepatol* 2013;59(05):1081–1093
  - 27 Bai M, Qi X, Yang Z, et al. Predictors of hepatic encephalopathy after transjugular intrahepatic portosystemic shunt in cirrhotic patients: a systematic review. *J Gastroenterol Hepatol* 2011;26(06):943–951
  - 28 Fanelli F, Salvatori FM, Rabuffi P, et al. Management of refractory hepatic encephalopathy after insertion of TIPS: long-term results of shunt reduction with hourglass-shaped balloon-expandable stent-graft. *AJR Am J Roentgenol* 2009;193(06):1696–1702
  - 29 Hausegger KA, Karnel F, Georgieva B, et al. Transjugular intrahepatic portosystemic shunt creation with the Viatorr expanded polytetrafluoroethylene-covered stent-graft. *J Vasc Interv Radiol* 2004;15(03):239–248
  - 30 Vignali C, Bargellini I, Grosso M, et al. TIPS with expanded polytetrafluoroethylene-covered stent: results of an Italian multicenter study. *AJR Am J Roentgenol* 2005;185(02):472–480
  - 31 Rossi P, Salvatori FM, Fanelli F, et al. Polytetrafluoroethylene-covered nitinol stent-graft for transjugular intrahepatic portosystemic shunt creation: 3-year experience. *Radiology* 2004;231(03):820–830
  - 32 Sahagun G, Benner KG, Saxon R, et al. Outcome of 100 patients after transjugular intrahepatic portosystemic shunt for variceal hemorrhage. *Am J Gastroenterol* 1997;92(09):1444–1452
  - 33 Kamath PS, Wiesner RH, Malinchoc M, et al. A model to predict survival in patients with end-stage liver disease. *Hepatology* 2001;33(02):464–470
  - 34 Bai M, He C-Y, Qi X-S, et al. Shunting branch of portal vein and stent position predict survival after transjugular intrahepatic portosystemic shunt. *World J Gastroenterol* 2014;20(03):774–785
  - 35 Chen L, Xiao T, Chen W, et al. Outcomes of transjugular intrahepatic portosystemic shunt through the left branch vs. the right branch of the portal vein in advanced cirrhosis: a randomized trial. *Liver Int* 2009;29(07):1101–1109