

Reversible Rapid Neck Swelling Following Carotid Artery Stenting: A Case Report

Shyamkumar N. Keshava¹ Thomas Mammen¹ Edwin Stephen² Sunil Agarwal²

¹Department of Radiology, Christian Medical College, Vellore, Tamil Nadu, India

²Department of Vascular Surgery, Christian Medical College, Vellore, Tamil Nadu, India

Address for correspondence Shyamkumar N. Keshava, MBBS, DMRD, DNB, FRACR, FRANZCR, Department of Radiology, Christian Medical College, Ida Scudder Road, Vellore 632004, Tamil Nadu, India (e-mail: aparna_shyam@cmcvellore.ac.in).

J Clin Interv Radiol ISVIR 2017;1:43–45.

Abstract

We report a case of rapid neck swelling from diffuse enlargement of the parotid gland that developed following stenting of the common carotid artery for significant stenosis in a postradiation scenario. Hyperperfusion was considered as the possible mechanism. The pathology and differential diagnoses are discussed. It was conservatively managed and there was significant reduction in the swelling within three days.

Keyword

► carotid artery stenting

Introduction

Carotid artery stenting for high-risk stenotic lesions associated with radiotherapy-induced arteritis is an accepted practice.¹ Radiation-induced stenoses of the carotid artery are associated with fibrosis of the arterial layers and tissue planes that renders their surgical treatment difficult.² The complications associated with this entity are usually related to stroke.

Case Report

A 63-year-old man, who was on follow-up for squamous cell carcinoma of the base of the tongue status postradiation therapy 3 years prior, presented for color Doppler examination of the neck vessels. He was asymptomatic for neurologic deficits and was being treated for radiation-induced hypothyroidism and xerostomia. Clinical examination revealed no neck masses or nodes. Chest radiograph revealed fibrosis in both lung apices. Duplex study of the neck vessels (Toshiba Medical Systems Corporation, Xario, Japan) demonstrated diffuse long segment wall thickening of bilateral common carotid arteries with 80% stenosis. Laboratory work-up was negative for inflammatory markers. He was started on 75 mg of oral acetyl salicylic acid per day, and a repeat examination performed 3 months later revealed progression of the stenosis to 90% bilaterally. We planned for bilateral carotid artery stenting in a staged manner.

The left common carotid artery was treated first. He was given a loading dose of clopidogrel 300 mg orally, 2 hours prior to the procedure. The procedure was performed under local anesthesia. A digital subtraction angiography of the left

common carotid artery demonstrated multiple segments of narrowing (►Fig. 1) involving the common carotid artery, with the narrowest portion measuring 90%, just below the carotid artery bifurcation. The distal most segments of the common carotid artery and the internal carotid artery were normal. The external carotid artery branches were uniformly narrowed. The contrast iohexol (Omnipaque, Nycomed Imaging AS, Oslo, Norway) was injected with hand, each injection approximately 2 to 4 mL during the procedure. Subsequently, a 7-F, 45-cm long sheath (Arrow International, Reading, Pennsylvania, United States) was placed within the left common carotid artery. A bolus intravenous injection of heparin 5,000 U was given. An 8 mm × 8 cm self-expanding stent Protégé GPS EV3 (EV3, Plymouth, Minnesota, United States) was placed across the abnormal segments of left common carotid artery over a 0.035-inch guidewire (Terumo Corporation, Somerset, New Jersey). A distal protection device was not used. Angioplasty was performed using a 7 mm × 6 cm balloon (Cook Medical Inc., Bloomington, Indiana, United States). There was adequate restoration of the lumen (►Fig. 2) on postangioplasty angiography. There were no intracranial emboli on postprocedure cerebral angiography.

Approximately 1 hour after the procedure, patient developed left neck swelling (►Fig. 3). His blood pressure was 90/60 mm Hg. A color Doppler examination of the neck vessels revealed a patent left common carotid artery and the stent. There was no hematoma around the left common carotid artery. The left parotid gland showed diffuse swelling with edema. He also complained of mild head ache. A reperfusion injury was considered as the possible mechanism

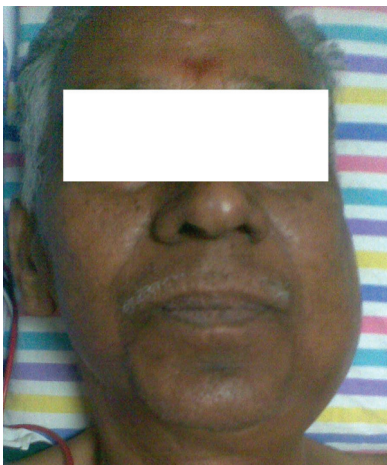

Fig. 1 Photograph of the patient's face showing the ipsilateral (left) parotid region swelling.

and he was managed conservatively. A magnetic resonance imaging with magnetic resonance angiography (MRA) confirmed the findings (►**Fig. 4**). In addition, there was also diffuse soft tissue swelling in the left upper neck, especially in the tonsillar region. The swelling was stable and gradually reduced by the next day. Within 3 days, there was significant reduction of the swelling.

Discussion

Extracranial carotid artery stenosis is a known complication of external irradiation to the head and neck region. Angioplasty and stent placement have low rates of complications and restenosis in the treatment of radiation-associated carotid occlusive disease.³ The reported procedural stroke rate was 4%.³

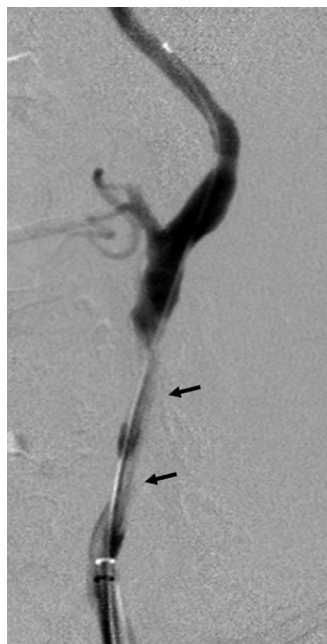

Fig. 2 An angiogram of the left common carotid artery before the procedure, showing multiple segments of strictures (arrows).

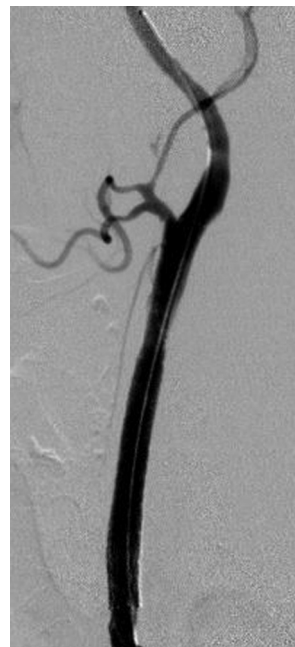

Fig. 3 An angiogram following left common carotid artery stenting and angioplasty showing restoration of the lumen.

Acute neck swelling, immediately after carotid artery stenting, requires evaluation to rule out arterial rupture. There is suggestion of a higher chance of arterial injury related to carotid stenting for radiation-induced strictures. In a case report by Bates and Almekhi et al, a 56-year-old male who underwent carotid stenting for a radiation-induced carotid artery stenosis developed two aneurysmal dilations: one at the proximal edge of the stent that was successfully treated with a stent graft and a second aneurysm proximal to the stent graft for which he ultimately underwent venous bypass covered by a free-muscle graft.⁴

The neck swelling in our patient was related to parotid gland swelling. Hyperperfusion of the parotid gland was considered as the possible etiology based on multiple reasons. First, the patient had clinical manifestations of a hyperperfusion to the brain represented by a transient headache and fall in blood pressure. Second, unlike internal carotid artery stenting, the site of stenosis and stenting in our case was in the common carotid artery, which can lead to hyperperfusion of both external and internal carotid artery territories. Third, the external carotid artery branches in this patient were uniformly smaller prior to the procedure, which could be due to a compensatory mechanism to redirect more blood to the intracranial region. The external carotid branches were above the level of radiation therapy field. In addition, the MRA performed 1 day following stenting showed restoration of the size of external carotid artery branches. Hyperperfusion syndrome is an uncommon but potentially serious complication of extracranial and intracranial carotid angioplasty and stenting procedures. Meyers et al documented a 5% incidence of hyperperfusion syndrome following carotid angioplasty and stenting in a group of 140 cases.⁵ The incidence of intraparenchymal cerebral hematoma is 3.8% following carotid stenting.⁶ No clinical manifestations in the

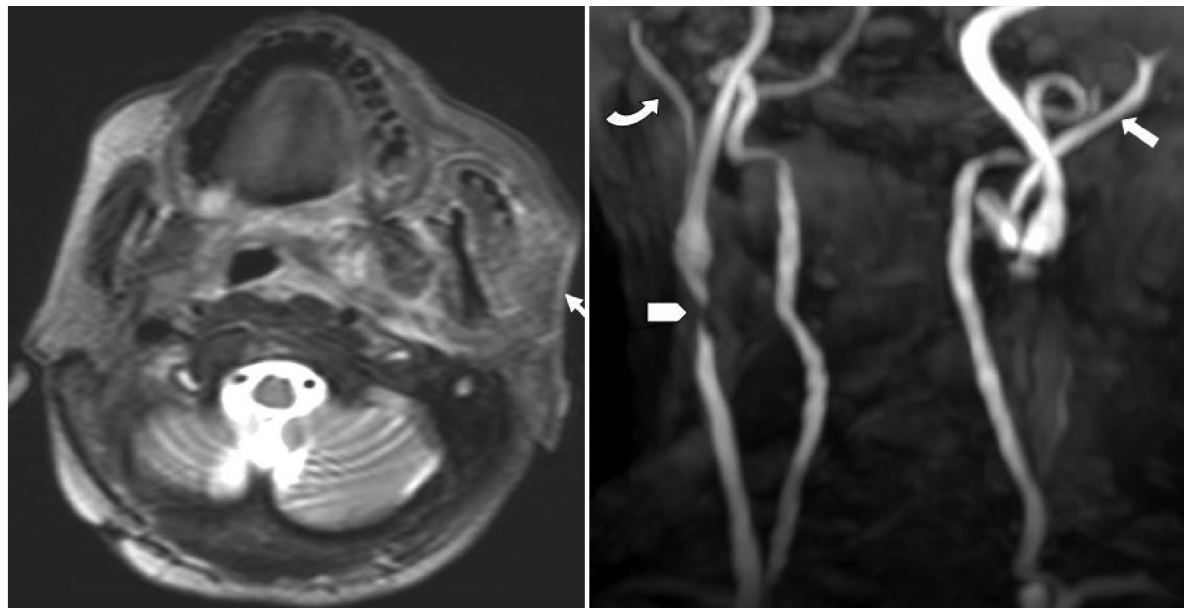


Fig. 4 (A) T2-weighted axial magnetic resonance imaging showing diffuse swelling of left parotid (arrow) as well as other soft tissues, especially in the tonsillar region. (B) Magnetic resonance angiography demonstrating increase in the caliber of the left external carotid branches (arrow), compared with the right (curved arrow). Radiation induced stricture on the right side (arrow head), nonvisualized left common carotid artery secondary to stent-induced artifacts.

external carotid artery territory are reported, possibly because of the higher location of the stenting. Guidewire perforation of an external carotid arterial branch was not considered as a possibility of neck swelling because the guidewire was positioned in the internal carotid artery during the procedure and its tip was always visible during the procedure. In addition, there was no focal hematoma identified on imaging. "Iodide mumps" is the swelling of the submandibular, sublingual, and/or parotid glands is an uncommon complication to intravascular administration of contrast material.⁷ Parotitis following carotid stenting also has been reported.⁸ However, this condition usually involves the salivary glands bilaterally unlike in this case. Patient did not have any swelling during prior procedures that involved use of iodinated contrast materials.

In summary, a patient with a rapidly developing neck swelling after carotid artery intervention requires immediate attention as the etiology could be an arterial perforation or rupture, especially during therapy for a radiation-induced carotid artery stricture. Parotid and other soft tissue swelling in the neck region is a very rare manifestation from common carotid artery stenting. A possible hyperperfusion mechanism was considered as an etiology. This is self-limiting, and no active intervention is required for this entity.

References

- 1 Protack CD, Bakken AM, Saad WE, Illig KA, Waldman DL, Davies MG. Radiation arteritis: a contraindication to carotid stenting? *J Vasc Surg* 2007;45(1):110–117
- 2 Houdart E, Mounayer C, Chapot R, Saint-Maurice JP, Merland JJ. Carotid stenting for radiation-induced stenoses: a report of 7 cases. *Stroke* 2001;32(1):118–121
- 3 Harrod-Kim P, Kadkhodayan Y, Derdeyn CP, Cross DT III, Moran CJ. Outcomes of carotid angioplasty and stenting for radiation-associated stenosis. *AJNR Am J Neuroradiol* 2005;26(7):1781–1788
- 4 Bates MC, Almekhi A. Carotid stenting for symptomatic radiation-induced arteritis complicated by recurrent aneurysm formation. *Catheter Cardiovasc Interv* 2004;63(4):507–511
- 5 Meyers PM, Higashida RT, Phatouros CC, et al. Cerebral hyperperfusion syndrome after percutaneous transluminal stenting of the craniocervical arteries. *Neurosurgery* 2000;47(2):335–343, discussion 343–345
- 6 Morrish W, Grahovac S, Douen A, et al. Intracranial hemorrhage after stenting and angioplasty of extracranial carotid stenosis. *AJNR Am J Neuroradiol* 2000;21(10):1911–1916
- 7 Christensen J. Iodide mumps after intravascular administration of a nonionic contrast medium. Case report and review of the literature. *Acta Radiol* 1995;36(1):82–84
- 8 Kohat AK, Jayantee K, Phadke RV, Muthu R, Singh V, Misra UK. Beware of parotitis induced by iodine-containing contrast media. *J Postgrad Med* 2014;60(1):75–76