Listeria monocytogenes Brain Abscess within a Metastatic Intracerebellar Space-Occupying Lesion in a Patient with Carcinoma Lung: First Case Report from India

Arun Oommen[1] Molly Johny[2] Thara Pratap[3] Renu Suresh Paul[4] Jily P. Chinnan[2] Muhammed Jasim Abdul Jalal[5]

[1] Department of Neurosurgery, VPS Lakeshore Hospital, Kochi, Kerala, India
[2] Department of Microbiology, VPS Lakeshore Hospital, Kochi, Kerala, India
[3] Department of Radiology, VPS Lakeshore Hospital, Kochi, Kerala, India
[4] Department of Pathology, VPS Lakeshore Hospital, Kochi, Kerala, India
[5] Department of Rheumatology and Internal Medicine, VPS Lakeshore Hospital, Kochi, Kerala, India

Address for correspondence Muhammed Jasim Abdul Jalal, MBBS, DNB, Department of Rheumatology and Internal Medicine, VPS Lakeshore Hospital, Kochi, Kerala 682040, India (e-mail: jasimabduljalal@yahoo.com).

Indian J Neurosurg 2017;6:129–134.

Abstract

Listeria monocytogenes infections are rare. Neonates and geriatric population, pregnant women, and diabetic and immunocompromised patients are at higher risk for invasive listeriosis. Early recognition of *Listeria* brain abscess remains a major challenge. Here, we describe a case of intratumoral abscess with *L. monocytogenes* in a patient with intracerebellar metastasis from poorly differentiated adenocarcinoma lung. Right cerebellar tumor with a thick-walled purulent cavity was resected. Histopathologic examination revealed acute inflammation consistent with abscess and showed metastatic poorly differentiated adenocarcinoma. Cultures of the abscess fluid grew *L. monocytogenes*. She responded well to ampicillin-gentamycin therapy and the surveillance imaging done on the seventh postoperative day showed clearance of the abscess. The patient is further being planned for radiotherapy in regard to metastasis. *Listeria* abscess within a metastatic tumor is very rare and only one case is reported as of our knowledge. *Listeria* abscess being reported within an intracerebellar metastatic space-occupying lesion is for the first time.

Keywords
- *Listeria monocytogenes* brain abscess
- brain abscess within a metastasis
- intracerebellar brain abscess

Background

Listeria monocytogenes infections are rare, yet they carry significant morbidity and mortality rates. This makes early recognition and timely treatment of the infection crucial for improving patient outcomes. Neonates and geriatric population, pregnant women, and diabetic and immunocompromised patients are at higher risk for invasive listeriosis. Central nervous system (CNS) involvement can be seen in up to 55% of patients, usually in the form of meningitis or meningoencephalitis. More rarely, *Listeria* brain abscesses have been reported,[1] and early recognition of the nature of these lesions remains a major challenge.

received
March 8, 2017
accepted
April 21, 2017
published online
May 19, 2017

DOI https://doi.org/10.1055/s-0037-1603326.
ISSN 2277-954X.

© 2017 Neurological Surgeons' Society of India

License terms

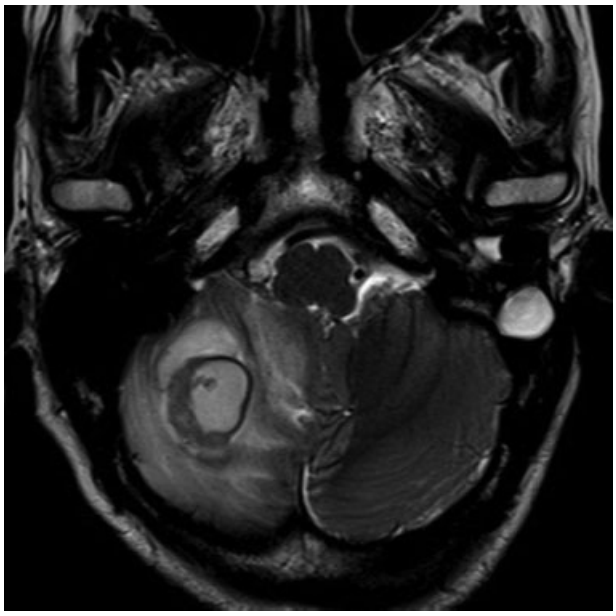

Fig. 1 Axial T2W sequences demonstrate cystic lesion with hyperintense contents and variable thickened hypointense rim.

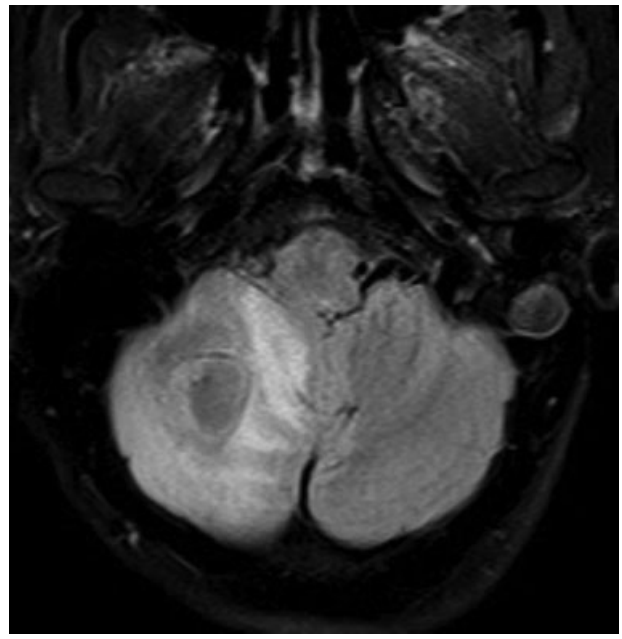

Fig. 2 FLAIR sequence shows perilesional edema.

Indeed, the neuroradiologic appearance of these abscesses is not different from that of other types of brain abscesses and may also mimic primary or metastatic brain tumors. In addition, clinical manifestations of CNS infection (e.g., fever, headache, encephalopathy, meningeal signs, focal neurologic deficits, seizures, and hyponatremia) are nonspecific, and it is difficult to identify a link between neurologic presentations and the ingestion of food contaminated by *Listeria*, a food-borne pathogen, as the onset of symptoms can be as late as 1 month or more after pathogen exposure.[2]

Here, we describe a case of intratumoral abscess with *L. monocytogenes* in a patient with intracerebellar metastasis from poorly differentiated adenocarcinoma lung.

Case Presentation

A 58-year-old woman with recently detected, poorly differentiated adenocarcinoma lung presented with headache and imbalance. She had occasional episodes of vomiting. There was no history of any seizures or weakness. Her past medical history was insignificant otherwise.

On examination, she was afebrile, conscious, and oriented. Her neurologic examination including cranial nerves, motor power, and gait was normal. The systemic examination was unremarkable. Hemogram, liver function, renal function, and coagulation profile were all within normal limits.

Magnetic resonance imaging (MRI) performed on 3T machine showed ring-enhancing, well-marginated, biloculated cystic lesion in the right cerebellar hemisphere; the lesion size was 2.1 × 2.0 cm. The cyst content was hypointense on T1 and hyperintense on T2-weighted images (►**Fig. 1**) with T2 hypointense rim. There was perilesional edema and minimal mass effect (►**Fig. 2**). The rim was irregular and showed varying thickness with enhancement in postcontrast study (►**Fig. 3**). The cyst contents showed diffusion restriction (►**Fig. 4A, B**). Magnetic resonance perfusion showed elevated rCBV (relative cerebral blood volume) (►**Fig. 5**) and magnetic resonance spectroscopy showed high choline/creatine ratio in the cyst wall.

A right suboccipital craniectomy was performed. Right cerebellar tumor (3 × 2 cm) with a 2- × 2-cm-sized thick-walled purulent cavity was resected. Abscess had a thick capsule. The pus was sent for microscopy and culture, and the patient was empirically started on intravenous ceftizoxime, metronidazole, and amikacin. Specimens

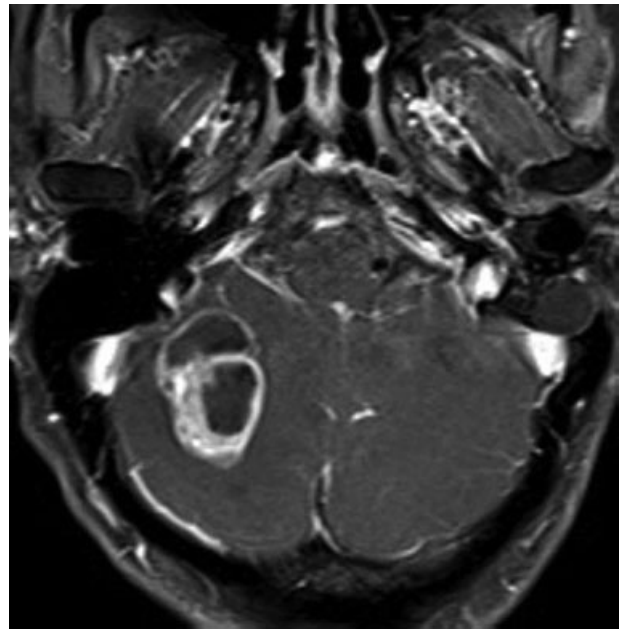

Fig. 3 Postcontrast axial T1W sequence shows ring-enhancing lesion with irregular thickened wall.

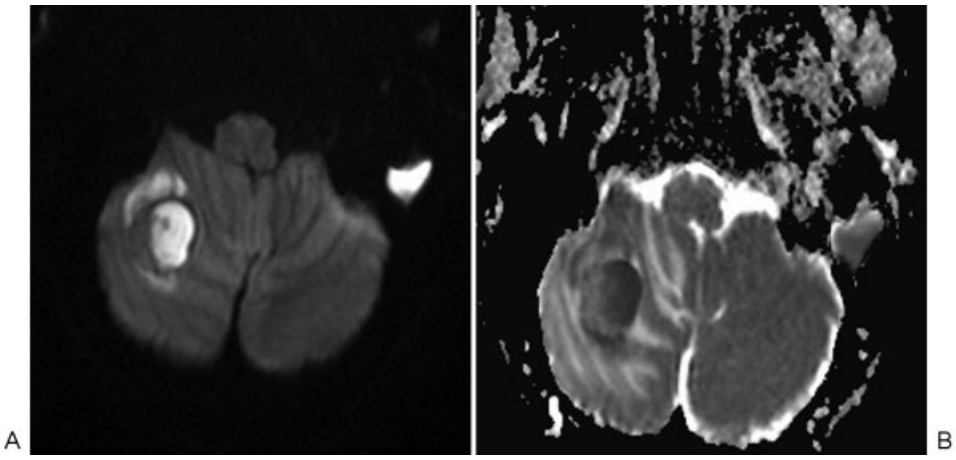

Fig. 4 (**A, B**) DW images demonstrate hyperintensity and ADC revealed hypointensity in the central region suggesting diffusion restriction.

sent for histopathologic examination revealed acute inflammation consistent with abscess and showed metastatic poorly differentiated adenocarcinoma. Cultures of the abscess fluid grew *L. monocytogenes* susceptible to ampicillin, penicillin G, gentamicin, and trimethoprim-sulfamethoxazole.

The antibiotic therapy was changed to ampicillin and gentamicin from the third postoperative day based on the pus culture report. The patient was discharged with advice to continue ampicillin and gentamicin for 6 weeks. However, the patient discontinued all medications by self after 2 weeks. Surveillance imaging was done on the seventh postoperative day, which showed clearance of the abscess. The patient is further being planned for radiotherapy in regard to metastasis.

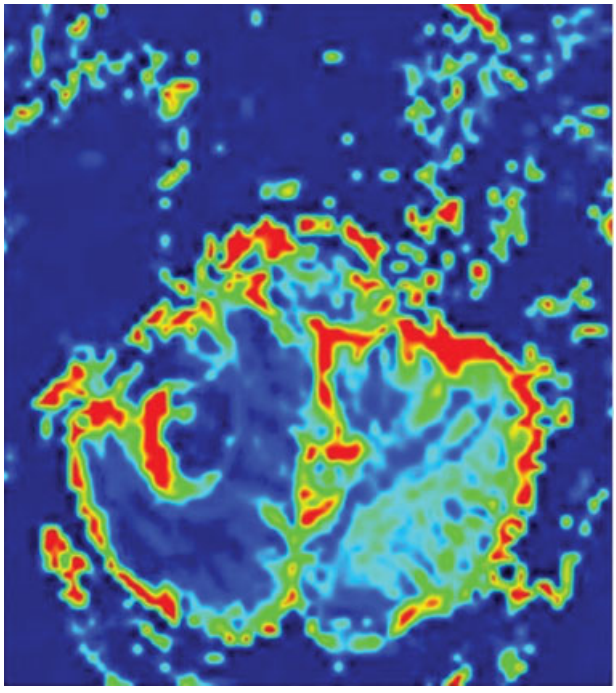

Fig. 5 MR perfusion map: High rCBV noted in the cyst wall, suggesting neo-angiogenesis.

Microbiology

Direct smear of the pus from brain abscess stained by Gram stain showed pus cells and occasional small gram-positive bacilli. The pus was inoculated onto blood agar, chocolate agar, MacConkey agar, and thioglycolate broth. After 24 hours of incubation, the culture showed moderate growth of small, round, translucent colonies with a narrow zone of β-hemolysis on blood agar. Gram stain of the colonies also showed small gram-positive bacilli. Tumbling (end over end) motility was seen in peptone water incubated at 25°C. The organism was catalase positive, bile-esculin positive, and showed umbrella-shaped motility pattern in semisolid agar incubated at 25°C. Vitek 2 confirmed the identification as *L. monocytogenes* (VITEK 2GP card). The isolate was sensitive to penicillin, ampicillin, cotrimoxazole, and gentamicin.

Histopathology and Immunohistochemistry

Biopsy showed a poorly differentiated carcinoma in a necrotic background with sheets of neutrophil polymorphs, consistent with abscess. Tumor cells were large with pleomorphic nuclei and formed solid islands and trabeculae. These tumor cells were positive for immunohistochemical markers cytokeratin, cytokeratin7, thyroid transcription factor 1, and napsin, which confirmed it as an adenocarcinoma of primary lung origin (►**Fig. 6–9**).

Discussion

L. monocytogenes is a nonsporing facultative small gram-positive bacillus, which causes infections rarely in healthy people but serious infections in the neonates, pregnant (maternal/fetal), elderly, and immunocompromised people or debilitated adults with underlying diseases.[3] Its main mode of transmission is contaminated food.[4] It is found in nature, soil and water, human and animal feces, and as a contaminant in food processing facilities. Ready-to-eat processed food ("deli meat," cheese and milk products

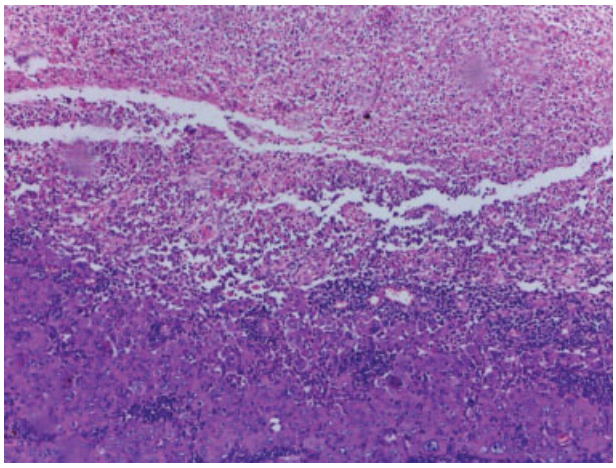

Fig. 6 Carcinoma cells in the lower part and sheets of neutrophil polymorphs in the upper part (hematoxylin and eosin stain ×10).

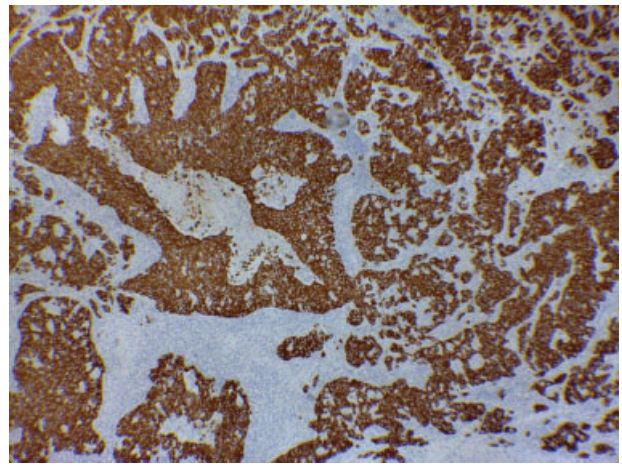

Fig. 8 Positive CK7 immunohistochemical staining in tumor cells (HRP streptavidin technique ×40).

from un-pasteurized milk) stored for long periods at refrigerator temperature, which favors growth of *Listeria*, forms a consistent source of *Listeria*. It is killed by cooking and pasteurization. Cell-mediated immunity is the host's primary defense mechanism against *L. monocytogenes* infection.[5] In the immunocompetent, gastrointestinal exposure to a high inoculum of *L. monocytogenes* can result in a self-limited, febrile diarrheal gastroenteritis with a median duration of 27 to 42 hours.[6] In the immunocompromised, gastrointestinal invasion can lead to bacteremia and seeding to various organs, particularly the CNS, where it can cause meningitis, meningoencephalitis, rhombencephalitis, or, much less commonly, brain abscesses.[4] Brain abscesses constitute approximately 10% of all *L. monocytogenes* CNS infections.[3] In an 8-year prospective multi-institutional study by Prasad et al, *L. monocytogenes* was isolated from 0.8% of brain abscesses; however, this study did not include an organ transplant population, which could potentially constitute a significant number of patients who acquire *Listeria* brain abscesses.[7] A retrospective study by Tattevin et al showed that *L. monocytogenes* accounted for 9% of brain abscesses in patients admitted to the intensive care unit, although patients with human immunodeficiency virus (HIV) were excluded from this study.[8]

Our patient's history of metastatic adenocarcinoma of the lung and immunocompromised status represent a well-established risk factor for *Listeria* CNS infection. *Listeria* abscess within a metastatic tumor is very rare and only one case is reported as of our knowledge (►**Table 1**). In 2013, Stöve et al reported a case of cerebral *Listeria* abscess in a 70-year-old woman with gastric cancer.[9] However, *Listeria* abscess being reported within an intracerebellar metastatic space-occupying lesion is for the first time (►**Table 1**).

L. monocytogenes gains access to the CNS by transporting across the blood-brain or blood-choroid barriers within circulating leukocytes by a phagocyte-facilitated (Trojan horse) mechanism, direct invasion of blood-brain or blood-choroid endothelial cells by extracellular blood-borne bacteria, or retrograde migration into the brain within the axons of cranial nerves.[10] Most cases of *Listeria* brain abscess occur in patients with underlying

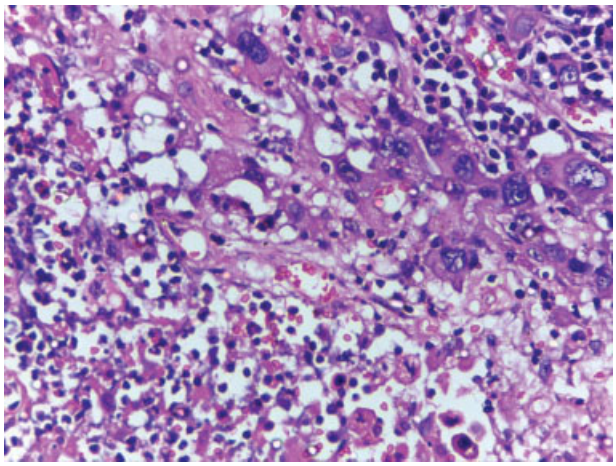

Fig. 7 Carcinoma cells in a background of sheets of neutrophil polymorphs (abscess) (hematoxylin and eosin stain ×40).

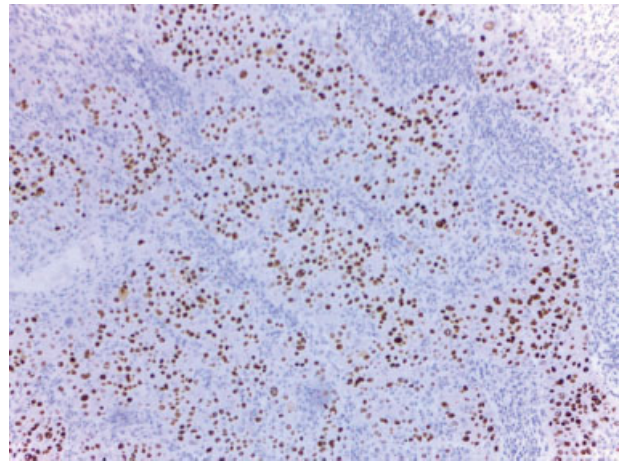

Fig. 9 Immunohistochemical staining for thyroid transcription factor1 showing positive staining in tumor nuclei and negative staining in background inflammatory cells (HRP streptavidin technique ×20).

Table 1 Clinical summary of abscesses coexisting with metastatic carcinoma

Author	Year	Age/sex	Region	Symptom	Organism	Outcome
Rodriguez et al.[21]	1986	28/M	Parietal	Fever, headache, nausea	*Salmonella enteritidis*	–
Ng and Lozano[22]	1996	79/F	Posterior fossa	Nausea, truncal ataxia	*Haemophilus parainfluenzae*	Death[a]
Kovacic et al.[23]	2004	66/M	Posterior fossa	Nystagmus, gait disturbance	*Propionibacterium acnes*	Death
	2004	72/M	Posterior fossa	Headache, gait disturbance	*Staphylococcus* spp.	Death[a]
Moiyadi and Shetty[24]	2010	36/F	Frontal	Elevated intracranial pressure	*Acinetobacter baumannii*	Favorable
Goto et al[25]	2012	58/M	Posterior fossa	Truncal ataxia	*Unidentified*	Favorable
Stöve et al[9]	2013	70/F	Parieto-occipital region	Disturbed consciousness	*Listeria monocytogenes*	Favorable
Present case	2016	58/F	Posterior fossa (intracerebellar)	Headache and imbalance	*L. monocytogenes*	Favorable

Abbreviations: F, female; M, male; spp., species.
[a]Neurologically favorable just after surgery but died due to systemic disease.

hematologic malignancies or in those receiving solid organ transplants.[11–13]

Listeria brain abscess is associated with positive blood culture in 85% patients and concomitant meningitis in nearly 25% patients.[12,13] The high rate of positive blood culture suggests that the pathogenesis of *Listeria* brain abscess is secondary to spread from invasion of blood stream.[13] Blood cultures are considered as a sensitive diagnostic tool for *Listeria* brain abscesses. In our case, the patient did not have any fever, and blood cultures were not done before the surgical intervention. The high vascularity of the metastatic lesion in the brain seen in the MRI of our patient probably contributed to the development of the abscess within the tumor.

The differential diagnosis of ring-enhancing lesions in conventional MRI other than necrotic tumor and abscess are high-grade glioma, granuloma, resolving hematoma, subacute infarction, demyelination, and CNS lymphoma in patients with AIDS.

Diffusion-weighted MRI, magnetic resonance spectroscopy, and magnetic resonance perfusion are advanced techniques that would provide important physiologic and metabolic information to differentiate between these lesions.

When a lesion demonstrates both ring enhancement and central restricted diffusion, the differential is very much narrowed. Although the most likely diagnosis is abscess, necrotic tumors need exclusion as there has been a few reported cases of necrotic tumors with restricted diffusion.[11,12] The possible explanation for diffusion restriction in abscess is increased protein concentration in the form of highly viscous mucin, cellularity, or intracellular hemoglobin states (intracellular oxy-, intracellular deoxy-, and intracellular methemoglobin).

Toh et al[14] showed that cerebral abscess wall possessed low rCBV due to poor vascularity of the capsular wall, whereas necrotic tumor possessed an elevated rCBV due to neo-angiogenesis. Kamble et al[15] have also showed that perfusion can differentiate between various ring-enhancing lesions.

Hence, overall features suggested cerebellar metastasis. Metastasis to the cerebellum is a frequent complication in patients with primary malignancy. Coexistence of abscess in a CNS metastasis is a rare event. Imaging may not identify both when they coexist. It is important to be aware that brain metastasis can also be infected.

Approximately 20% of all listeriosis patients succumb to infection despite early aggressive treatment, with particularly elevated case fatality rates in those who are immunocompromised or have an underlying illness or malignancy. Skogberg et al demonstrated 32% mortality in those with underlying disease or in those receiving immunosuppressant medications, whereas no deaths were observed in healthy patients.[16]

Goulet et al demonstrated up to 40% mortality among those with *L. monocytogenes* bacteremia complicating a malignancy, with the highest incidence of infection occurring in patients with chronic lymphocytic leukemia and liver cancer and the highest case fatality rate in those with lung and pancreatic cancers.[17] Our patient with the metastatic brain lesion and abscess within the tumor survived the infection with *L. monocytogenes*, probably due to the surgical intervention associated with drainage of the abscess followed by administration of recommended antibiotic regimen ampicillin along with gentamicin.

There are currently no large controlled trials comparing treatments for listeriosis. Generally, ampicillin is considered

the treatment of choice. Both penicillin and ampicillin are effective for therapy of *L. monocytogenes* infections, and high-dose intravenous ampicillin[18,19] is recommended for *Listeria* brain abscess. The addition of gentamicin should be considered for synergistic effect with ampicillin. For patients allergic to penicillin, trimethoprim-sulfamethoxazole that is bactericidal against *Listeria* in vitro is the drug of choice. Despite the broad range of in vitro activity of the third-generation cephalosporins, they are ineffective for therapy against *L. monocytogenes*. Hence in empiric therapy of meningitis (and other CNS infections) in the elderly and immunocompromised, addition of ampicillin to ceftriaxone is recommended and will cover *L. monocytogenes* as well. Vancomycin is ineffective despite being sensitive in vitro, and intraventricular administration may be effective. Chloramphenicol has been associated with an unacceptable failure rate in *Listeria* meningitis. Surgical drainage is indicated if the abscess is greater than 2.5 cm.[20] Patients with a *Listeria* brain abscess should receive treatment for at least 6 weeks and be followed by serial neurologic imaging, with MRI as the preferred modality.

Conflict of Interest
The authors have no conflict of interest relevant to this article to disclose.

Funding
The authors have no financial relationships relevant to this article to disclose.

Acknowledgments
We would like to thank Susy Paul (Microbiology) and Sarath (Radiology) for their help in completing this manuscript.

References

1 Bartt R. Listeria and atypical presentations of *Listeria* in the central nervous system. Semin Neurol 2000;20(03):361–373
2 Castro A, Hernández OH, Uribe CS, Guerra A, Urueña P. [Brainstem encephalitis and myelitis due to *Listeria monocytogenes*: a case report and literature review] [in Spanish]. Biomedica 2013;33(03):343–349
3 Vázquez-Boland JA, Kuhn M, Berche P, et al. Listeria pathogenesis and molecular virulence determinants. Clin Microbiol Rev 2001; 14(03):584–640
4 Lorber B. *Listeria monocytogenes*.. In: Bennett J, Dolin R, Blaser M, eds. Mandell, Douglas, and Bennett's Principles and Practice of Infectious Diseases. 8th ed. Philadelphia, PA: Elsevier/ Saunders; 2015:2383–2390
5 National Center for Emerging and Zoonotic Infectious Diseases. Division of food borne, water borne and environmental diseases. CDC 24/7. Saving lives, protecting people. Centers for Disease Control and Prevention; March 24, 2015
6 Dalton CB, Austin CC, Sobel J, et al. An outbreak of gastroenteritis and fever due to *Listeria monocytogenes* in milk. N Engl J Med 1997;336(02):100–105
7 Prasad KN, Mishra AM, Gupta D, Husain N, Husain M, Gupta RK. Analysis of microbial etiology and mortality in patients with brain abscess. J Infect 2006;53(04):221–227
8 Tattevin P, Bruneel F, Clair B, et al. Bacterial brain abscesses: a retrospective study of 94 patients admitted to an intensive care unit (1980 to 1999). Am J Med 2003;115(02):143–146
9 Stöve S, Feldmann A, Bäsecke J. [Cerebral listeria abscess in a patient with gastric cancer] [in German]. Dtsch Med Wochenschr 2013;138(14):737–739
10 Drevets DA, Bronze MS. *Listeria monocytogenes*: epidemiology, human disease, and mechanisms of brain invasion. FEMS Immunol Med Microbiol 2008;53(02):151–165
11 Duygulu G, Ovali GY, Calli C, et al. Intracerebral metastasis showing restricted diffusion: correlation with histopathologic findings. Eur J Radiol 2010;74(01):117–120
12 Hartmann M, Jansen O, Heiland S, Sommer C, Münkel K, Sartor K. Restricted diffusion within ring enhancement is not pathognomonic for brain abscess. AJNR Am J Neuroradiol 2001;22(09): 1738–1742
13 Eckburg PB, Montoya JG, Vosti KL. Brain abscess due to *Listeria monocytogenes*: five cases and a review of the literature. Medicine (Baltimore) 2001;80(04):223–235
14 Toh CH, Wei KC, Chang CN, Ng SH, Wong HF, Lin CP. Differentiation of brain abscesses from glioblastomas and metastatic brain tumors: comparisons of diagnostic performance of dynamic susceptibility contrast-enhanced perfusion MR imaging before and after mathematic contrast leakage correction. PLoS One 2014;9(10):e109172
15 Kamble RB, Jayakumar PN, Shivashankar R. Role of dynamic CT perfusion study in evaluating various intracranial space-occupying lesions. Indian J Radiol Imaging 2015;25(02): 162–166
16 Skogberg K, Syrjänen J, Jahkola M, et al. Clinical presentation and outcome of listeriosis in patients with and without immunosuppressive therapy. Clin Infect Dis 1992;14(04): 815–821
17 Goulet V, Hebert M, Hedberg C, et al. Incidence of listeriosis and related mortality among groups at risk of acquiring listeriosis. Clin Infect Dis 2012;54(05):652–660
18 Cone LA, Leung MM, Byrd RG, Annunziata GM, Lam RY, Herman BK. Multiple cerebral abscesses because of *Listeria monocytogenes*: three case reports and a literature review of supratentorial listerial brain abscess(es). Surg Neurol 2003; 59(04):320–328
19 Soares-Fernandes JP, Beleza P, Cerqueira JJ, et al. Simultaneous supratentorial and brainstem abscesses due to *Listeria monocytogenes*. J Neuroradiol 2008;35(03):173–176
20 Hof H, Nichterlein T, Kretschmar M. Management of listeriosis. Clin Microbiol Rev 1997;10(02):345–357
21 Rodriguez RE, Valero V, Watanakunakorn C. Salmonella focal intracranial infections: review of the world literature (1884–1984) and report of an unusual case. Rev Infect Dis 1986;8(01): 31–41
22 Ng WP, Lozano A. Abscess within a brain metastasis. Can J Neurol Sci 1996;23(04):300–302
23 Kovacic S, Bunc G, Krajnc I. Abscess formation within cerebellar metastatic carcinoma—report of two cases and review of the literature. Wien Klin Wochenschr 2004;116(Suppl 2):60–63
24 Moiyadi A, Shetty P. Abscess in a metastasis. J Neurosurg 2010; 112(02):474–475
25 Goto Y, Ebisu T, Mineura K. Abscess formation within a cerebellar metastasis: case report and literature review. Int J Surg Case Rep 2015;10:59–64