Trauma Imaging of the Acute Cervical Spine

Daniela Berritto, MD[1] Antonio Pinto, MD[2] Paul Michelin, MD, MSc[3] Xavier Demondion, MD, PhD[4] Sammy Badr, MD, MSc[4]

[1] Department of Radiology, Private Hospital "Villa dei Fiori," Acerra, Naples, Italy
[2] Department of Radiology, Cardarelli Hospital, Naples, Italy
[3] Department of Radiology, University Hospital of Rouen, Rouen, France
[4] Department of Musculoskeletal Radiology, CHU Lille, Lille, France

Address for correspondence Sammy Badr, MD, MSc, CHU Lille, Service d'imagerie musculosquelettique, rue Émile Laine, 59037 Lille, France (e-mail: sammy.badr@chru-lille.fr).

Semin Musculoskelet Radiol 2017;21:184–198.

Abstract

Among patients admitted in emergency departments for acute cervical spine trauma, only a few have a confirmed and significant injury requiring surgical intervention. Imaging plays a key role in screening for unstable lesions that can be responsible for devastating neurologic complications or death. The complex anatomy of the cervical spine is associated with a wide spectrum of osseous and ligamentous pathologies. This review focuses on the imaging features of the main cervical spine fractures that can be encountered in emergency radiology.

Keywords
- cervical spine
- trauma
- diagnostic imaging
- emergency radiology

Cervical spine trauma is a frequent condition encountered in emergency departments. Road traffic accidents, falls, and sports injuries (mainly equestrian events followed by rugby) are the most common causes of admission.[1] Patients with head trauma are more likely to have cervical spine injuries, a severe neurologic outcome, and an early mortality rate.[2–4] However, an intervention (surgical stabilization, halo, or cervical-thoracic orthosis) is required in $< 5\%$ of adult patients who did not match the National Emergency X-Radiography Utilization Study (NEXUS) low-risk criteria.[5] Therefore, imaging plays a key role in screening for unstable lesions and preventing devastating undiagnosed spinal injuries.

Imaging Strategy

Choosing the right initial imaging modality is challenging for clinicians and has been widely discussed. Clinical decision-making tools have been developed to help physicians (►**Table 1**).

For alert and asymptomatic patients in stable condition, the Canadian C-Spine Rule and the NEXUS low-risk criteria may be used to reduce the number of unnecessary radiographs.[6–8] Caution must be exercised, however, especially with the NEXUS low-risk criteria that do not have an age limitation. Medical history must also be taken into consideration, particularly if the patient has an ankylosing spinal disorder like spondyloarthritis (ankylosing spondylitis) because fractures can occur even from minor trauma.[9]

If cervical spine imaging is needed, the minimal radiographic assessment must include a three-view cervical spine series (odontoid, or "open-mouth," anteroposterior, and lateral), supplemented with computed tomography (CT) in case of inadequate radiographs, suspicious areas, or ill-defined structures.

Moreover, current literature provides more evidence to use CT first if available, especially for unconscious, intermediate-risk, and high-risk patients.[10] Its superior diagnostic performance, as well as time and cost-effectiveness analyses, have supported this assessment.[11–13] Recommendations from the American College of Radiology and the American Association of Neurological Surgeons approved these data and suggested CT as the primary modality for patients not meeting low-risk criteria,[10,14] supplemented with magnetic resonance imaging (MRI) if spinal cord compression or contusion is suspected or discoligamentous evaluation is required.[10]

In patients < 9 years of age, radiography is recommended as the first imaging modality, however, and use of cervical CT must be limited to selected cases.[15] MRI should also be

Issue Theme Emergency and Trauma in MSK Radiology; Guest Editor, Giuseppe Guglielmi, MD

DOI https://doi.org/10.1055/s-0037-1602713.
ISSN 1089-7860.

Table 1 NEXUS low-risk criteria[6] and Canadian C-spine rule[8]

NEXUS[6]	- **No**rmal level of alertness
	- **No** evidence of intoxication
	- **No** tenderness at the posterior midline of the cervical spine
	- **No** focal neurologic deficit
	- **No** clinically apparent pain that might distract the patient from the pain of a cervical spine injury
Canadian C-Spine Rule[8]	In alert (Glasgow Coma Scale = 15) patients (≥ 16 years old):
	- **No** high-risk factor:
	o Age ≥ 65 years old
	o Paresthesias in extremities
	o Dangerous mechanism
	- **Presence** of low-risk factor that allows safe assessment of range of motion:
	o Simple rear-end motor vehicle collision
	o Sitting position in emergency department
	o Ambulatory at any time
	o Delayed onset of neck pain
	o Absence of midline cervical tenderness
	- **Able** to actively rotate neck by 45 degrees left and right

Abbreviation: NEXUS, National Emergency X-Radiography Utilization Study.

considered because ligamentous and spinal cord injuries without radiologic abnormality are more common in the pediatric population.[15]

Radiographic Assessment

Lateral, anteroposterior, and odontoid views (►**Fig. 1**) must be appraised methodically after assessing their quality (ABC's method, proposed by Daffner and Harris[16]) as follows:

- *Quality:* All seven cervical vertebrae must be demonstrated, the cervicothoracic junction (apophyseal joints of C7–T1) visualized, and the mandible and articular facets superimposed (head and neck in a neutral position, with no rotation).
- ***A**lignment:* Bony alignment can be evaluated by drawing four lines on the lateral view (the anterior and posterior vertebral lines, and the spinolaminar and interspinous lines). On the anteroposterior view, spinous processes should be in midline and regularly spaced, with no focal displacement. On the odontoid view, lateral masses should also be aligned.
- ***B**one integrity:* Bony landmarks must be identified, with no loss of vertebral body height and no fracture line.
- ***C**artilage (joints):* No space abnormalities. In addition to specific indices, Daffner and Harris simplified radiographic interpretation by using the "rule of twos." The interlaminar (interspinous) space, interpedicle distance (transverse or vertical), unilateral or bilateral atlantoaxial offset, and the interfacetal joint width must not differ by > 2 mm.[16] The interlaminar distance is more reliable and accurate than the interspinous distance to explore hyperflexion injuries.
- ***S**oft tissue:* Retropharyngeal thickness should not exceed 7 mm in children and adults at the C2 level, and 14 mm (in children) or 22 mm (in adults) at the C6 level.[16]

The lateral view is the most important radiograph to acquire. Because nearly half of all cervical spine injuries affect C6 and C7,[2,3] the cervicothoracic junction must be seen, supplemented by additional views (swimmer's or oblique views) or by gently pulling down the shoulders. If plain radiographs are still inadequate or a lesion is suspected, CT imaging must be done.

Upper Cervical Spine Injuries (C0–C2)

Anatomy of the Occipitoatlantoaxial Joint Complex

The occipitoatlantoaxial joint complex (►**Fig. 2**) relies on several intrinsic ligaments. The tectorial membrane, the cruciate, and bilateral alar ligaments are the most important.[17,18]

The tectorial membrane is the craniocervical portion of the posterior longitudinal ligament, joining the upper cervical vertebrae with the anterior margin of the foramen magnum and limiting the extension of the occipitoatlantal joint. The cruciate ligament spans horizontally from the dens to the lateral masses of C1, and vertically to the anterior margin of the foramen magnum, just posterior to the apical ligament. The bilateral alar ligaments, inelastic structures, limit lateral tilt and rotation in tandem. They mainly consist of fibers joining the dens with the medial inferior aspect of the occipital condyles.

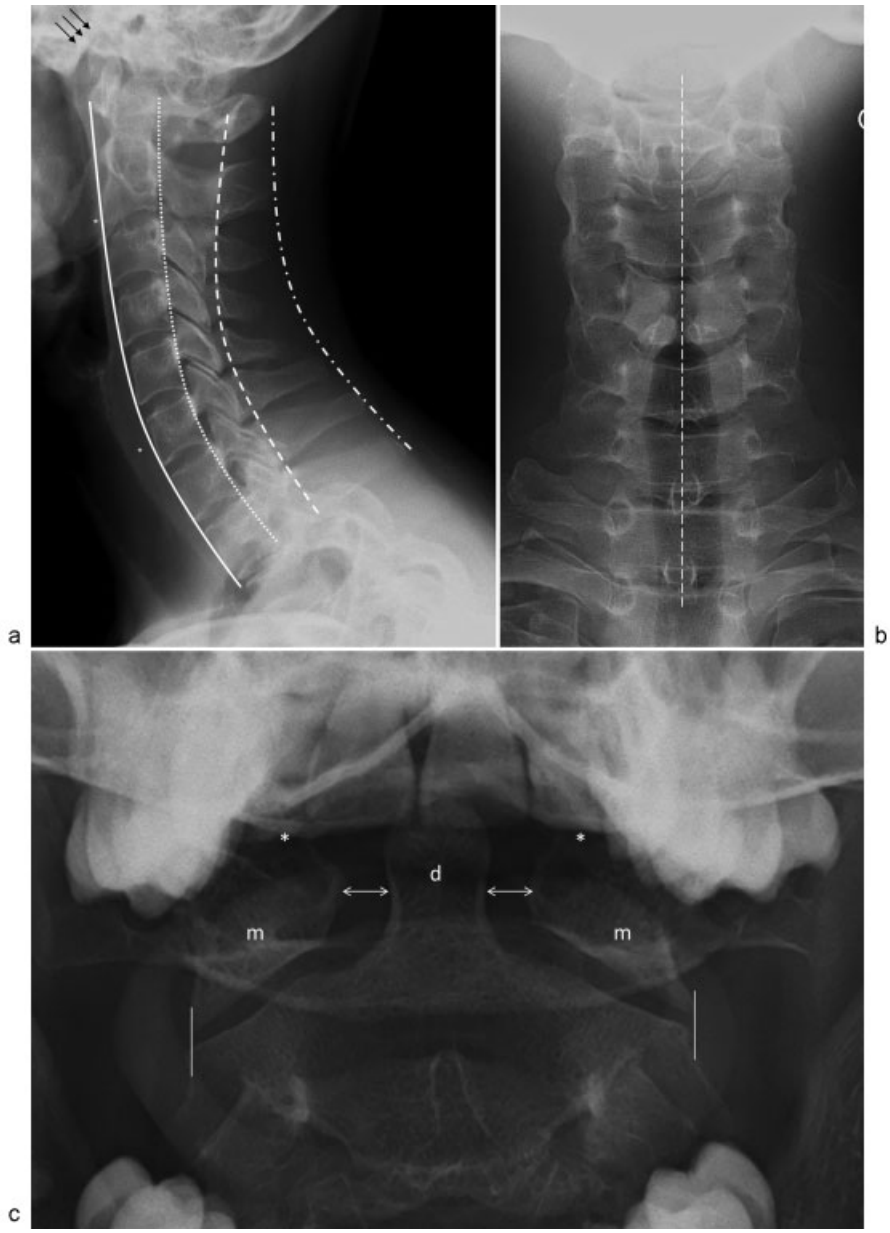

Fig. 1 Normal standard three-view series (plain radiographs). (**a**) On lateral views, the anterior (solid line), posterior (dotted line), spinolaminar (dashed line), and interspinous (dash-dotted line) must be smoothly drawn. Soft tissue swelling can be assessed at C2 and C6 levels (asterisks). A spheno-occipital synchondrosis may be seen in young adults and must not be mistaken as a fracture (black arrows). (**b**) On anteroposterior views, spinous processes are in midline and regularly spaced (dashed line). No vertebrae misalignment should be observed. (**c**) On odontoid views, lateral masses of C1 (m) are equally distant (double-headed arrows) from the dens of the odontoid (d) and aligned with the articular facets of C2 (solid lines). Occipitoatlantal joints may be identified (asterisks).

In addition to these structures, extrinsic ligaments (the articular capsule ligaments and the anterior, posterior, and lateral atlantooccipital membranes) strengthen the craniocervical junction by connecting the ring of C1 to the base of the skull.[19] Another distinctive feature of this region is the absence of intervertebral discs: The load of the skull is directly transferred through the lateral masses of C1 and C2.[20] Through this unique joint complex, many upper cervical vertebrae injuries can be associated because of the close relationship between the occipital condyles (C0), atlas (C1), and axis (C2) vertebrae.

Normal anatomical variants and congenital defects may appear as pseudo fractures, so knowledge of the normal development of the upper cervical spine is critical.[20,21] The description of these variations is beyond the scope of this article.

Occipital Condyle Fractures (C0)

Occipital condyle fractures are rare injuries, now increasingly diagnosed in survivors of high-energy blunt trauma because of the widespread use of CT.[17] Clinical presentation may vary, from only upper cervical pain without neurologic

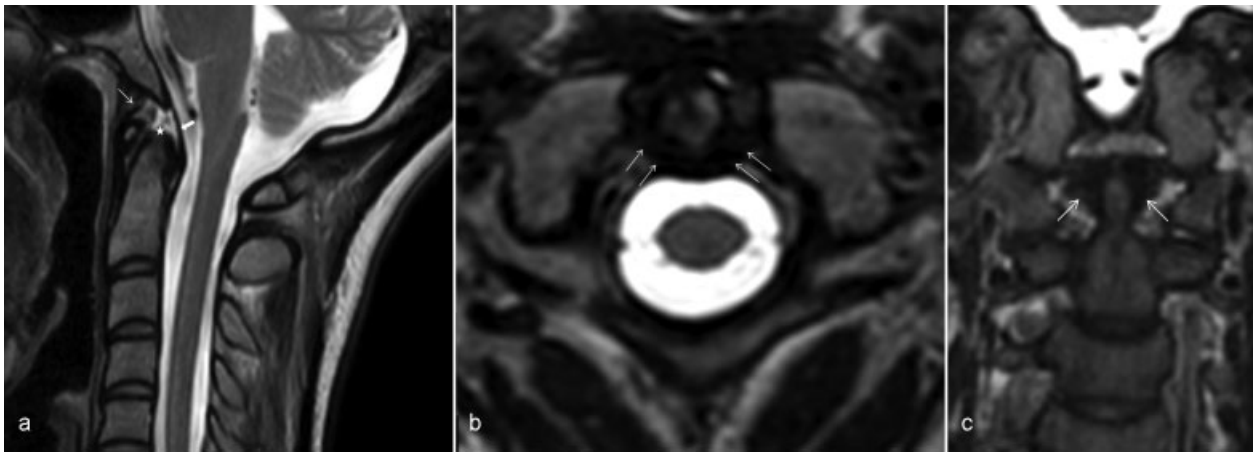

Fig. 2 Normal T2-weighted MRI anatomy. (**a**) Sagittal plane demonstrating the hypointense anterior atlanto-occipital membrane (thin arrow), the apical ligament (white star), and the tectorial membrane (plain arrow). (**b**) Axial plane demonstrating the transverse ligament (thin arrows). (**c**) Coronal plane demonstrating the alar ligaments (thin arrows).

deficit to palsy. Because they may be associated with craniocervical instability, these fractures are important to screen.

Lateral cervical spine radiography has a limited role in the detection of occipital condyle fractures, especially because endotracheal intubation and pooling of pharyngeal secretions are responsible for inadequate lateral cervical spine radiographs. When available, CT imaging is the best modality to explore occipital condyle fractures.

If only plain radiographs are available, alignment of the craniocervical junction should be evaluated from a cross-table lateral view using the basion-dental interval (BDI) and basion-axial interval (BAI) methods, described by Harris et al.[22,23] (►**Fig. 3**):

- *BDI:* The distance between the basion and the dens should not be > 12 mm in adults or children > than 13 years of age.[24]
- *BAI:* The distance between the basion and the posterior axial line should be between + 12 mm and − 4 mm.

The most widely used radiologic classification of occipital condyle fractures was described by Anderson and Montesano[25] as follows:

- *Type I:* Comminuted impaction-fracture due to axial loading that may compromise the ipsilateral alar ligament. Stability is maintained by the contralateral alar ligament and the tectorial membrane. This type is unusual and not frequently observed.[17]
- *Type II:* Skull base fracture that extends from the occipital bone to the condyle before reaching the foramen magnum. Stability is maintained by intact alar ligaments and the tectorial membrane (►**Fig. 4**).
- *Type III:* Avulsion fracture mediated through tension in an alar ligament. When associated with a disruption of alar

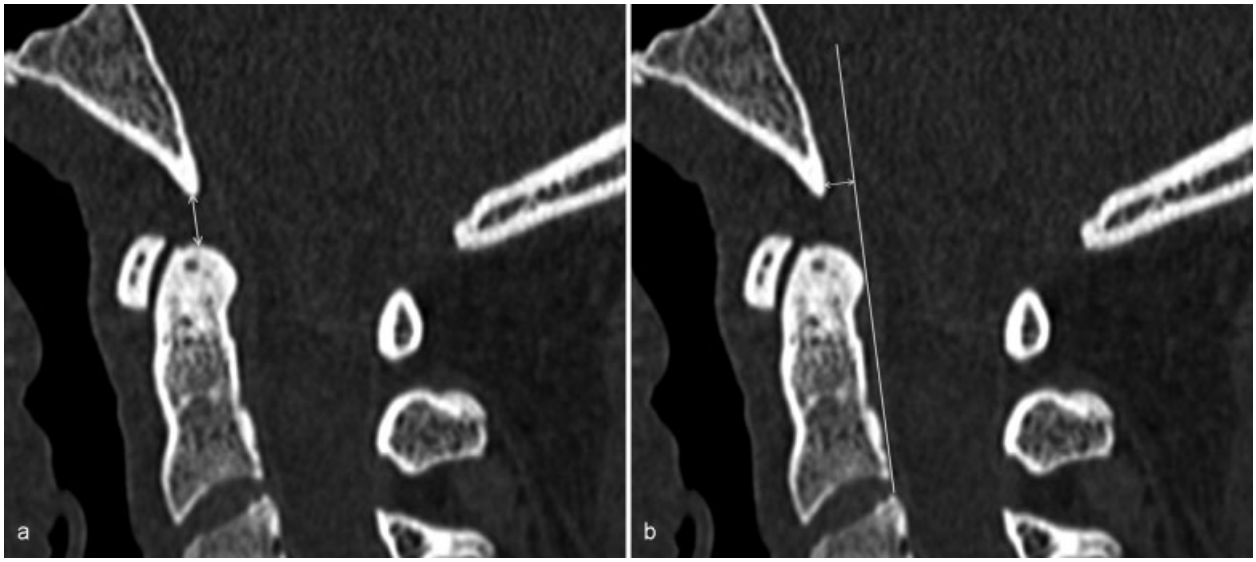

Fig. 3 Computed tomography (CT) assessment of the occipitoatlantoaxial joint complex (Harris's method). (**a**) The basion-dental interval should not be more than 12 mm in adults or children > 13 years.[22,23] (**b**) The basion-axial interval should be between + 12 mm and − 4 mm.

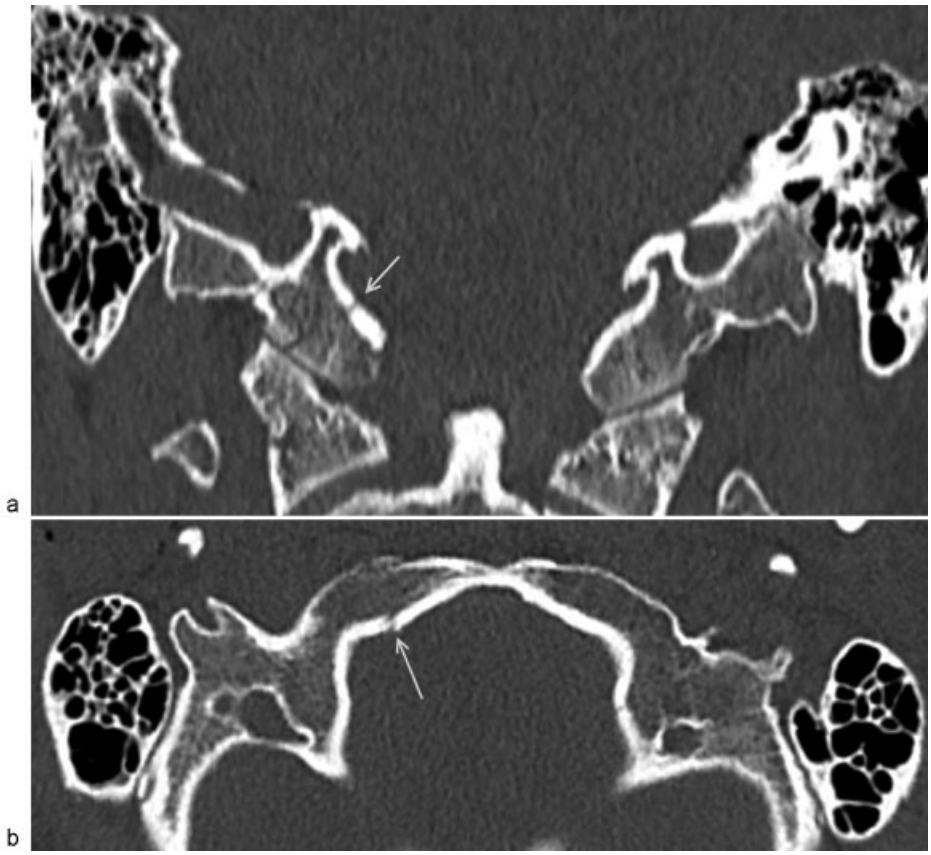

Fig. 4 Anderson and Montosano type II/Tuli type I right occipital condyle fracture (arrow), on (**a**) coronal and (**b**) axial computed tomography reformations.

ligaments and the tectorial membrane, craniocervical dislocation could occur.[26] This type is reported to be the most common.[17]

To guide neurosurgical management, Hanson et al suggested that a bilateral occipitoatlantoaxial joint complex injury, defined as the association of either bilateral occipital condyle fractures or unilateral occipital condyle fracture with contralateral widening of the occipitoatlantal (> 2 mm) or atlantoaxial (> 3 mm) joints (determined from sagittal and coronal CT reformations), can be used as a marker for instability.[17] Furthermore, Tuli et al proposed more recently a classification that includes ligamentous integrity, assessed by MRI[27]:

- *Type 1:* Nondisplaced occipital condyle fracture (stable, no specific treatment).
- *Type 2A:* Displaced (at least 2 mm) occipital condyle fracture with intact ligaments. There is no radiographic, CT, or MRI evidence of occipitoatlantoaxial instability or ligamentous disruption (stable, rigid cervical collar treatment).
- *Type 2B:* Displaced (at least 2 mm) occipital condyle fracture with radiographic evidence of craniocervical junction instability (unstable, requiring surgical instrumentation or halo traction).

Occipitoatlantal Dislocation

Traumatic occipitoatlantal dislocation (OAD) is a severe ligamentous injury of the craniocervical junction. Even if a high rate of mortality and significant neurologic morbidity is associated with this injury, recent advances in medical care are accountable for an increasing documented number of survivors.[18,28,29] Considerable strength is needed to cause OAD because the complexity of the occipitoatlantoaxial joint protects the craniocervical junction. However, in pediatric patients, lower energy trauma may be sufficient for an OAD to occur because these ligamentous structures are underdeveloped.[18] Patients often experience a combination of forces (hyperextension, lateral flexion, and/or hyperflexion) and have cervical pain, head trauma, or multiple traumatic injuries. Despite the severity of this injury, some patients may also present with no neurologic deficit.[28]

Current guidelines suggest using CT as the initial imaging modality if there is a clinical suspicion of OAD, even in children.[30] Swelling of prevertebral soft tissues and inadequate films should also suggest CT imaging.[30] The BDI-BAI (Harris's method) is preferred to evaluate occipitoatlantal ligamentous integrity indirectly[22,31] and can be used on plain radiographs or CT acquisitions, although BAI measurement is poorly reproducible on CT reconstructions.[32] In addition to BDI and BAI, Powers' ratio and X-line

methods can be used to strengthen the diagnostic accuracy of OAD:

- Powers' ratio is the ratio of the basion-posterior atlas arch distance to the opisthion-anterior arch distance. Values > 1 are pathologic.[33]
- X-line method is considered pathologic if the line from the basion to the axis spinolaminar junction does not intersect C2 or if a line from the opisthion to the posteroinferior corner of the body of the axis does not intersect C1.[34]

An initial classification was proposed in 1986 by Traynelis et al, in accordance with OAD orientation (type 1: anterior displacement; type 2: vertical distraction; type 3: posterior displacement).[35] However, this gradation did not sufficiently match with injury severity. To better guide neurosurgical treatment, Horn et al classified OAD fractures as follows[28]:

- *Grade I:* Normal CT findings in relation to established methods of diagnosis (Powers' ratio, X-line, BDI and BAI methods) and equivocal MRI findings consisting of high posterior ligamentous or occipitoatlantal signal and mild to no signal change at the occipitoatlantal joint. Nonoperative treatment, with halo or cervical collar, in patients with grade I injuries, is supported.
- *Grade II:* At least one abnormal finding on CT-based criteria or grossly abnormal MRI findings in the occipitoatlantal joints, tectorial membrane, alar ligaments, or cruciate ligaments. For these patients, surgical fixation is required.

Atlas Fractures (C1)

Atlas fractures account for 3 to 13% of acute cervical spine injuries and 1 to 3% of all spinal injuries.[36–40] A bimodal distribution is seen, with individuals in their mid-20s and between 80 and 84 years most at risk for C1 fractures. However, the mean age of diagnosis is 64 years, and nearly three quarters of atlas fractures occur in patients > 50 years of age.[38]

Patients with C1 fractures classically have cervical pain and neck stiffness, with a history of indirect trauma through axial compression (fall on the head) or violent hyperextension (automobile collision).[37] These fractures are not usually associated with a neurologic deficit because the fragments tend to spread away from the spinal cord.[40] However, the vertebral arteries are at high risk of injury (dissection and/or thrombosis) or spasm due to local inflammation that can result in neurologic deficits.

Because the atlas is a ring, fractures can affect in a combined or isolated way each arch, a lateral mass, or a transverse process. A descriptive classification was initially given by Gehweiler et al in 1976,[41] updated a decade later by Landells et al[42]:

- *Type I:* Fractures confined to a single arch (anterior or posterior). A "plow fracture" affects one anterior arch fracture and is caused by forces driving the odontoid anteriorly.
- *Type II:* Fractures involving both arches (►**Fig. 5**). Four-part fractures correspond to the classic Jefferson burst fracture.
- *Type III:* Isolated fractures of a lateral mass.

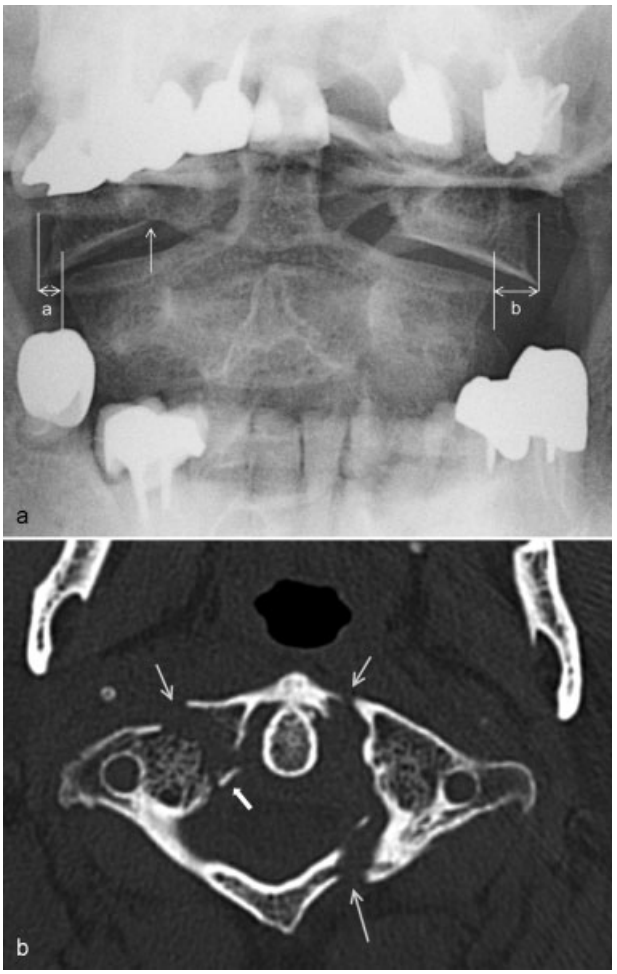

Fig. 5 Landell's type II Jefferson fracture variant (C1, three sites). (**a**) On odontoid views, displacement of lateral masses of C1 (a and b, double-headed arrows) may suggest a transversal ligament disruption if their sum is > 7 mm ($a + b > 7$ mm). (**b**) Displacement and fracture sites (arrows) are better assessed on axial computed tomography reformation. An associated comminuted fracture of the right lateral mass of C1 (plain arrow) may lead to atlantoaxial anteroposterior instability through a transverse ligament injury (type IIB of Dickman's classification).

On lateral views, only fractures of the posterior arch, horizontal fractures of the anterior arch, or retropharyngeal soft tissue swelling may be visible. Precise diagnosis and description of atlas fractures require CT, whereas ligamentous injuries are better identified with MRI.[43]

Odontoid Process Fracture (C2)

An odontoid process fracture, also known as a dens fracture, is the most common traumatic lesion of the axis (C2), accounting for 10 to 15% of all cervical fractures and is rarely associated with spinal cord injuries.[44–46] It occurs differently in elderly and young patients. Common in elderly people, but often missed, a dens fracture is caused by simple falls and may increase morbidity and mortality compared with younger patients with this injury. In young adults, dens

fractures result from head blunt trauma through cervical hyperflexion or hyperextension.

Patients with a dens fracture usually present with neck pain, worsening with motion. Dysphagia may be present when associated with a large retropharyngeal hematoma. Myelopathy is very rare due to the large cross-sectional area of the spinal canal at this level.

Dens fractures can be classified according to Anderson and D'Alonzo's classification as follow[47,48]:

- *Type I:* Oblique avulsion fracture of the tip of the odontoid, above the transverse ligament.
- *Type II:* Fracture occurring at the base of the odontoid, between the level of the transverse ligament and the body of C2, associated with a high nonunion rate due to interruption of blood supply. This type is the most common.[49]
- *Type III:* Fracture extending into the vertebral body.

To better predict the degree of instability, Roy-Camille's classification described four subtypes of type II Anderson's and D'Alonzo's injuries, depending on the direction of the fracture line. Anterior oblique fractures are more stable than the posterior oblique ones[50]:

- Oblique fracture line sloping forward, with dens displaced anteriorly.
- Oblique fracture line sloping backward, with dens displaced posteriorly (►**Fig. 6**).
- Horizontal fracture line, with dens displaced anteriorly or posteriorly.
- Fracture with rotation or "English policeman's hat."

Flexion-extension radiographs are important optional views to diagnose atlantoaxial instability in type I fractures and variants (os odontoideum). Anterior instability is defined as an atlantodens interval (ADI) > 10 mm and a space available for the spinal cord < 13 mm.[51]

CT is the imaging modality of choice for fracture delineation and assessing its stability. CT angiogram is required to determine the location of the vertebral artery prior to posterior instrumentation procedures. MRI is indicated if neurologic symptoms are present.

Nondisplaced fractures can be initially managed with cervical orthosis. Comminution and displaced fractures (> 5 mm) require surgical stabilization.[52]

Traumatic Spondylolisthesis of C2 (Hangman's Fracture)

Traumatic spondylolisthesis is considered one of the most frequent upper cervical spine injury and corresponds to the fracture of both "pars interarticularis" (isthmus) of C2.[2] It usually results from sudden cervical spine hyperextension and distraction, tearing apart the longitudinal ligaments and the intervertebral disc, which can lead to vertebral subluxation. Overall, 30% of concomitant cervical spine fractures are associated with this injury.[53]

Patients with hangman's fracture usually present with neck pain and no neurologic deficit.[54] Most authors affirm that hangman's fractures have a good prognosis.[53,55] The treatment of this fracture is predominantly nonoperative according to the literature, although surgery is preferred for neurologic symptoms, severe ligamentous injuries, or disruption of the C2–C3 disc space.[52]

The classification of these fractures, initially defined by Effendi et al,[56] then modified by Levine and Edwards who included the trauma mechanism,[57] is divided into three main types[48]:

- *Type I:* Fractures with minimal displacement (< 3 mm), secondary to an axial compression with cervical extension (stable) (►**Fig. 7**).
-

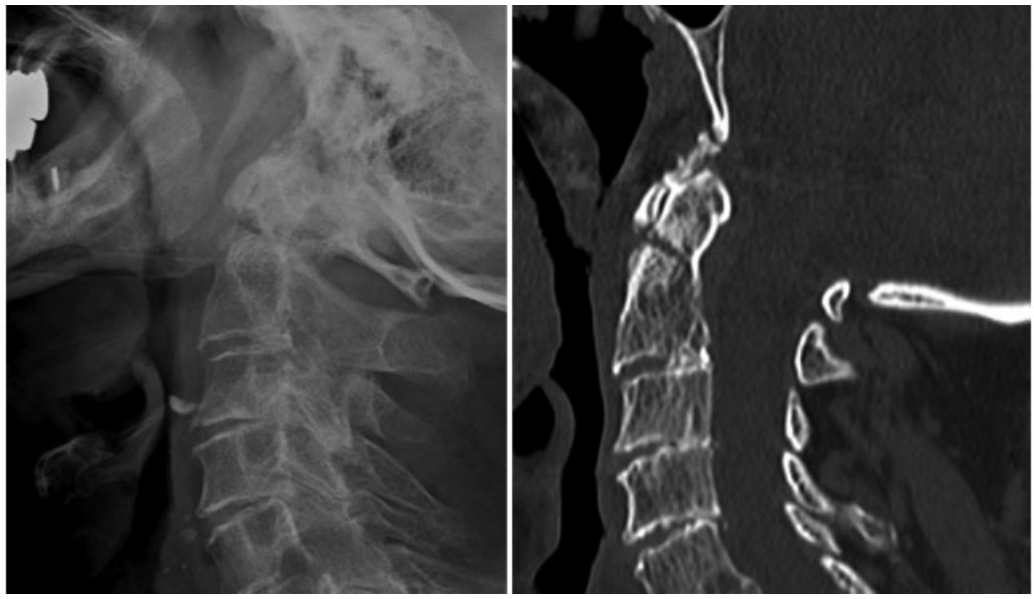

Fig. 6 Roy-Camille "oblique odontoid fracture sloping backward," on (**a**) lateral view and (**b**) sagittal computed tomography reformation.

Fig. 7 Levine and Edwards type I (nondisplaced) hangman's fracture (arrows), on (**a**) axial and (**b**) parasagittal computed tomography (CT) reformations. The anterior C2–C3 intersomatic space is initially widened (star) on the sagittal CT reformation (**c**), suggesting a disc injury and potential instability, confirmed by an anterior subluxation of C2 (double-headed arrow) demonstrated 3 months later (**d**).

Type II: Displaced fractures (> 3 mm), or angulated (> 11 degrees), secondary to axial compression with cervical extension, followed by a rebound flexion (unstable).

- *Type IIa:* Fractures with high angulation (often > 14 degrees) and minimal translation (< 3 mm), secondary to a flexion-distraction mechanism (unstable).
- *Type III* (rare): Translation and accentuated angulation are present, with dislocation of one or two C2–C3 articular facets and ligamentous disruptions (unstable).

On plain radiographs, anomalies could be subtle, and CT is the study of choice to delineate fracture pattern. MRI must be considered to evaluate discoligamentous structures and if there are neurologic symptoms and/or a suspicion of a vertebral artery injury.

Atlantoaxial Anteroposterior Dislocation

The complexity of the atlantoaxial joint provides robust head stabilization while the cervical spine is involved in complex movements. Atlantoaxial anteroposterior dislocation (AAD) is associated with a loss of stability. Unlike the lower cervical spine, the C1–C2 facets are not physically limited in their horizontal movements. The transverse ligament is the sole element preventing C1 from being

dislocated anteriorly and the dens from being displaced posteriorly.

Clinical presentation of atlantoaxial dislocation varies from minor neck pain to death. Approximately 50% of patients have neck pain and/or neck movement restriction, 70% with weakness and/or numbness, and 90% with pyramidal signs.[58–60]

Dickman et al proposed a classification to describe ligamentous injuries following AAD[48,61]:

- *Type I:* Pure transverse ligament injuries, requiring surgery (IA: midportion disruption; IB: disruption at its insertion without fracture of the tubercle).
- *Type II:* Injuries involving a bone fracture, requiring surgery if nonoperative management fails (IIA: avulsion fracture of a tubercle; IIB: comminuted lateral mass fracture).

On open-mouth views, if the sum of each lateral mass displacement is $>$ 7 mm, the transverse ligament is likely to be disrupted ("rule of Spence"). An avulsion fragment of the medial aspect of a lateral mass of C1 could also be visible. On lateral views, ligamentous instability can be assessed by the ADI. Normal ADI is $<$ 3 mm in adults and 5 mm in children, and a larger distance reflects a high probability of ligamentous injury.[62] Available space for the spinal cord can be estimated by measuring the distance from the posterior aspect of the dens to the anterior aspect of the posterior atlantal ring.

Moreover, because plain radiographs acquired in neutral position may be normal, dynamic cervical radiographs can be helpful to evaluate atlantoaxial stability with spontaneous reducible dislocation. MRI must be used to assess soft tissues, joints, and the spinal cord.

According to Wang's classification, and to guide treatment, AAD can be categorized into four types after flexion and extension radiographs[63]:

- *Type I:* Dynamic reduction on radiographs (instability).
- *Type II:* Reducible dislocation after skeletal traction under general anesthesia.
- *Type III:* Irreducible dislocation after skeletal traction under general anesthesia.
- *Type IV:* Bony dislocation (C1–C2 bony fusion).

Atlantoaxial Rotary Subluxation

Atlantoaxial rotary subluxation (ARS) is more common in children due to their discoligamentous laxity, and it occurs after a trauma with sudden head rotation. This pathologic pattern may also be caused by inflammatory processes, as in Grisel's syndrome, although rarely encountered. Because rotation of C1 over C2 is fixed, the head is blocked in lateral rotation and muscle contracture is responsible for cervical pain.

Whereas the transverse ligament and C1–C2 joint capsules keep the atlantoaxial joint from shifting in a sagittal plane, the alar ligaments prevent excessive rotation. The whole atlantoaxial ligamentous complex is involved in this injury.

CT is essential for ARS diagnosis. Evaluation of the ADI and anatomical relationship between C1 and C2 in an axial plane are required. Fielding and Hawkins in 1977 described four types of rotary subluxations[64]:

- *Type 1:* Rotary subluxation without anterior shift (►**Fig. 8**).
- *Type 2:* Rotary fixation with 3- to 5-mm anterior shift.
- *Type 3:* Rotary fixation with $>$ 5 mm anterior shift.
- *Type 4:* Rotary fixation with posterior shift (rare).

Because the atlantoaxial joint can rotate up to 40 degrees, physiologic rotation due to torticollis and type 1 ARS can be difficult to distinguish on a single CT scan. Some authors suggest scanning patients with maximum voluntary contralateral head rotation if symptoms do not resolve 3 to 4 weeks after the initial diagnosis. In patients with ARS, subluxation was not reducible on functional scans.[65]

Lower Cervical Region Injuries (C3–C7)

Due to its considerable mobility and proximity with the more rigid thoracic spine, the subaxial cervical spine is particularly vulnerable to traumatic injuries. More than two thirds of cervical fractures and spinal dislocations take place in this region, mostly from C5 to C7.[2,3] In addition to being frequently associated with neurologic symptoms, numerous patterns of osseous and ligamentous lesions can be observed in the lower cervical spine, and described according to the injury mechanism (compression, distraction, or rotation).

Subaxial Cervical Spine Injury Classification System

Several descriptive classifications of lower cervical vertebrae fractures have been proposed. However, in 2013 the Congress of Neurosurgeons recommended the use of the Subaxial Cervical Spine Injury Classification System (SLIC).[66,67] This severity scale is based on three main components: (1) injury morphology (compression, distraction, rotation/translation), (2) integrity of the discoligamentous complex, and (3) the patient's neurologic status. This gradation combines all imaging modalities available, especially MRI for discoligamentous complex assessment, and takes clinical evaluation into account (►**Table 2**). Even if only partially validated, this system is less complicated than other scales (the Cervical Spine Injury Severity Score is the main and more complex alternative) and may guide treatment.

Compression Injuries

Vertical compression injuries occur when sufficient axial strength is exerted through the spinal column. Minor vertical compression results in central cupping of vertebral end plates and/or sagittal/coronal split fractures. Most fractures affect only the vertebral body. With high-energy compression mechanisms, typical burst fractures show severe vertebral body height loss and may extend to the posterior column (►**Fig. 9**). Minimally displaced articular pillars and facet fractures may occur with lateral compression mechanisms. Fragments reaching the spinal canal can result in severe neural damages.

Of all cervical traumas, compressive hyperflexion injuries are responsible for the highest rate of neurologic outcomes.

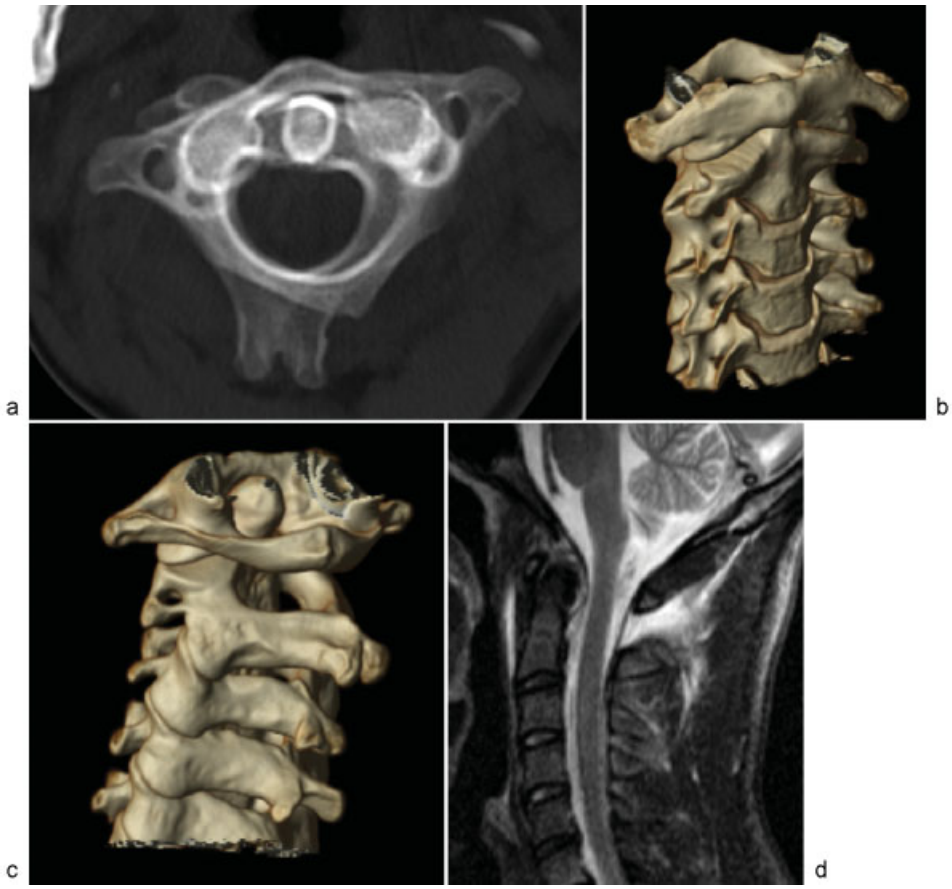

Fig. 8 Atlantoaxial rotary subluxation (ARS) in a patient with multiple traumatic injuries (car accident). Clinically, neck pain was associated with an impairment in rotation of the head. On computed tomography (CT), (**a**) axial and (**b, c**) volume rendering reformations demonstrate a rotation of the atlas over the axis, with no significant anterior shift (< 5 mm). This type 1 ARS (Fielding and Hawkins' classification) does not radiologically differ from a physiologic rotation of the head on the initial examination. However, subluxation was not reducible on a control CT scan (similar appearance, not shown). MRI revealed some prevertebral and posterior edema on sagittal proton-density-weighted short tau inversion recovery acquisitions (**d**), without any alar or transverse ligament disruption.

Table 2 Subaxial cervical spine injury classification[66]

Morphology	- No abnormality	**0**
	- Compression	**1**
	o Burst	**+ 1 = 2**
	- Distraction	**3**
	- Rotation/translation	**4**
Discoligamentous complex	- Intact	**0**
	- Indeterminate	**1**
	- Disrupted	**2**
Neurologic status	- Intact	**0**
	- Root injury	**1**
	- Complete cord injury	**2**
	- Incomplete cord injury	**3**
	- Continuous cord compression in setting of neurologic deficit (Neuro Modifier)	**+ 1**

Because they are frequently unstable, surgical stabilization is often needed.

Teardrop Fractures

When cervical flexion is combined with axial loading, the anterior and superior margin of the vertebral bodies is weakened and may wedge. With increased forces, a fracture line may appear in the coronal plane. A triangular anterior fragment is separated from the vertebral body. In so-called teardrop fractures, an additional fracture line is oriented in the sagittal plane (►**Fig. 10**). Forces may also result in a backward displacement of the remaining posterior vertebral body fragment, thus potentially leading to spinal cord compression. Tensile failure of the posterior part of the intervertebral disc and posterior ligamentous complex injuries can also occur resulting in highly unstable fractures.[68] MRI must not delay surgical intervention, especially if neurologic symptoms are present. To grade severity and evaluate prognosis, Korres et al proposed a classification for this peculiar fracture pattern:[69]

- *Type I:* Incomplete or occult sagittal fractures, with an anterior fragment < 3 mm.

Fig. 9 Complex vertebral fracture (fall from > 3 m high) on (**a**) sagittal computed tomography (CT) and (**b**) T2-weighted MRI acquisitions. Burst fracture of C7 (star) is best seen on CT, whereas soft tissues and distraction lesions are best explored on MRI: prevertebral hematoma with disruption of anterior and posterior longitudinal vertebral ligaments (arrows) leading to anterior subluxation of C6, spinal cord contusions (asterisk), and posterior edema suggesting supraspinous and interspinous ligamentous injuries (plain arrow).

- *Type II:* Complete sagittal fractures, without posterior displacement.
- *Type III:* Type II with posterior displacement (IIIa: < 4 mm; IIIb: > 4 mm).
- *Type IV:* Type IIIb with locked facet (the inferior articular facet is dislocated and locked over the superior articular process of the subjacent vertebra) and anterior dislocation of the above vertebra.

Distraction Injuries

The main feature of distraction injuries is the anatomical dissociation in the vertical axis, with severe discoligamentous lesions. In flexion, the posterior column is affected first. The supraspinous ligament begins to disrupt, followed by the interspinous ligament, facet capsular ligaments, and the ligamentum flava, thus leading to interspinous and interlaminar widening and unilateral or bilateral facet joint

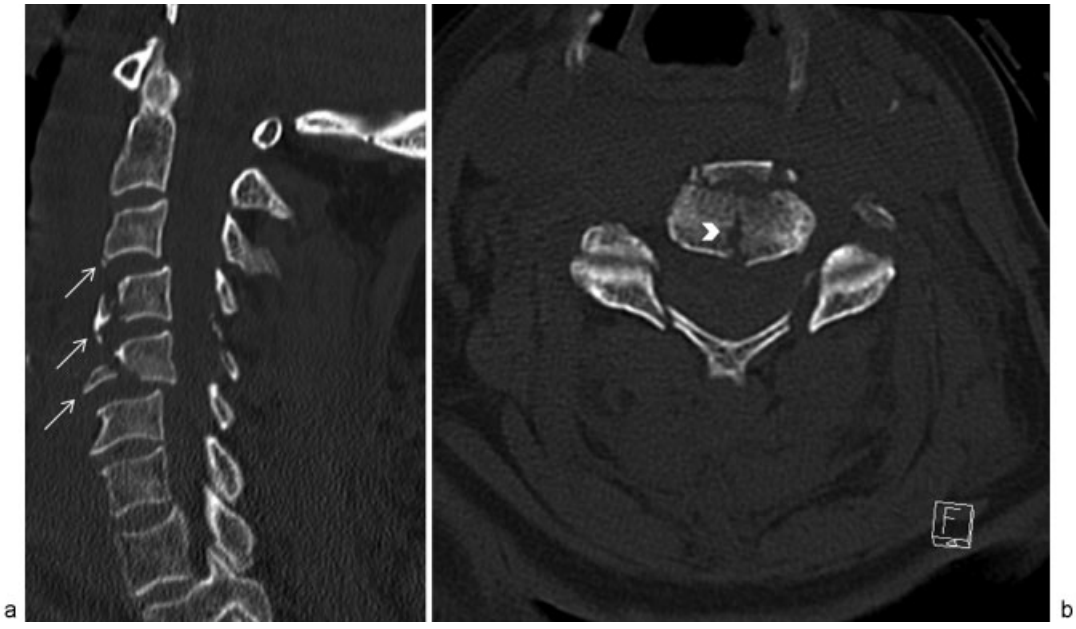

Fig. 10 Teardrop fractures. (**a**) A triangular fragment is seen at the anterior and inferior corner of C3–C5 vertebral bodies (arrows) on sagittal computed tomography (CT) reformations. (**b**) The sagittal fracture line (arrowhead) is best seen on axial CT reformations.

subluxation or dislocation. A widened posterior disc space can be associated with focal kyphosis and anterior subluxation of the vertebral bodies. Minor compressive forces are frequently present, resulting in vertebral end-plate fractures.[70]

After exaggerated cervical hyperextension, tensile failure of the anterior column progressively occurs. Ligamentous disruptions first take place, beginning with the anterior longitudinal ligament and progressing posteriorly, to affect the intervertebral disc and posterior longitudinal ligament. Posterior subluxation of the cranial vertebra over the caudal one may appear transiently as distraction increases and be combined with ligamentous and disc injuries. Severe neurologic deficits accompany dislocations. Widened anterior disc space resulting from anterior longitudinal ligament and anterior annulus disruption, spinous processes fractures, and avulsion fractures of the anterior body can be encountered. Because the posterior dislocation is transient, hyperextension-dislocation injuries may produce minimal imaging features on plain radiographs or CT. Diffuse prevertebral soft tissue swelling could be an indirect sign, as well as some degree of retrolisthesis.

Whiplash injuries, resulting from unrestrained hyperextension followed by flexion, fall into this category. Except in high-energy trauma, only some limited and nonspecific imaging findings have been described. MRI has a poor diagnostic accuracy for low-grade acute whiplash injuries.[71]

Severe cervical osteoarthritis and ankylosing spondylitis can significantly weaken the cervical spine. A minor trauma, especially through a distraction mechanism, may be responsible for unstable fractures. Only subtle injuries can be visible on plain radiographs, so patients with an ankylosed spine must undergo CT, supplemented with MRI if there are clinically or radiologically suspected discoligamentous or spinal cord injuries (►**Fig. 11**).

Rotation/Translation Injuries

The highest score for the SLIC severity scale (morphology component) is given when a horizontal translation exceeds 3.5 mm or a sagittal angulation > 11 degrees is observed. However, the translation must be unrelated to degenerative causes.[66] Anterior and posterior structures are injured through these trauma mechanisms (►**Fig. 12**).

Hyperflexion teardrop fractures, unilateral or bilateral facet dislocations, and pedicle fractures may fall into this category. Several signs on axial images were described to ease facet joint dislocation diagnosis[72,73]:

- The "reverse hamburger sign," suggested by a reversal of the normal facet relationship, with convex surfaces opposing each other (►**Fig. 13**).
- The "naked facet sign," due to an absent opposing facet joint articular process.
- The "headphones sign," consisting of a loss of concentric relationship of the uncinate processes with the superior vertebral body.

Clay-Shoveler's Fractures

Clay-shoveler's fractures are isolated spinous process fractures of a lower cervical vertebra, affecting mostly C7. Several mechanisms can produce this injury, such as a direct blow to the posterior aspect of the neck and cervical hyperextension and hyperflexion injuries. These are common and stable fractures but may require surgical treatment because of disabling pain.[74] This pain may radiate up to the head and

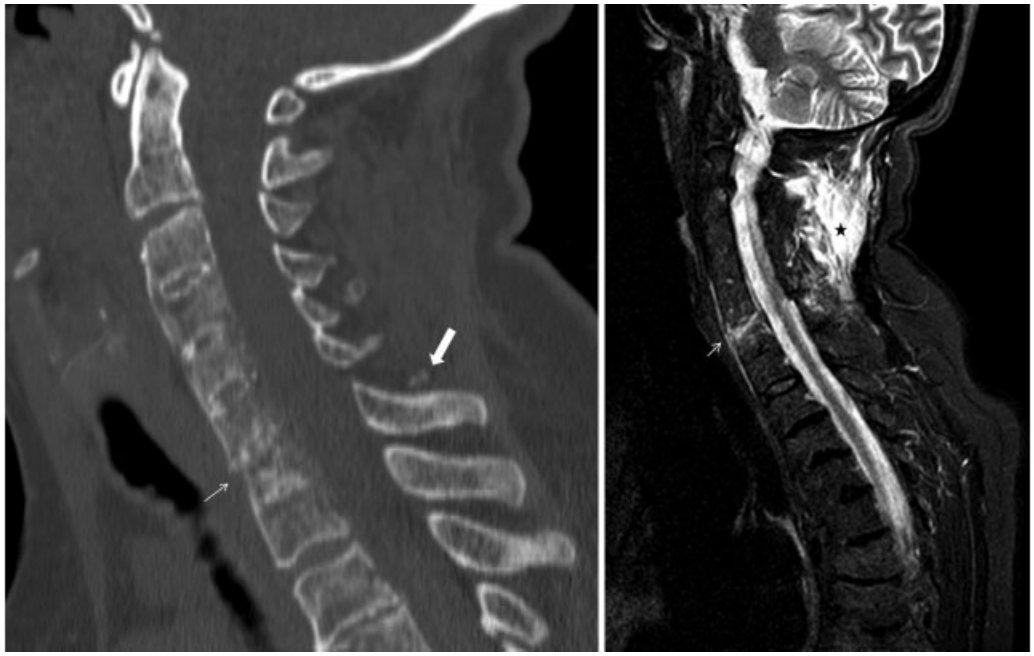

Fig. 11 Transdiscal fracture following a distraction injury on an ankylosed cervical spine. Sagittal computed tomography reformations (**a**) show a widened interspinous space, with a fractured bone fragment from a spinous process (plain arrow) and a fracture of the superior end plate of C7 (thin arrow), better individualized on sagittal proton-density-weighted short tau inversion recovery MRI acquisition (**b**). Hyperintense posterior soft tissues (black star) suggest supraspinous and interspinous ligament injuries.

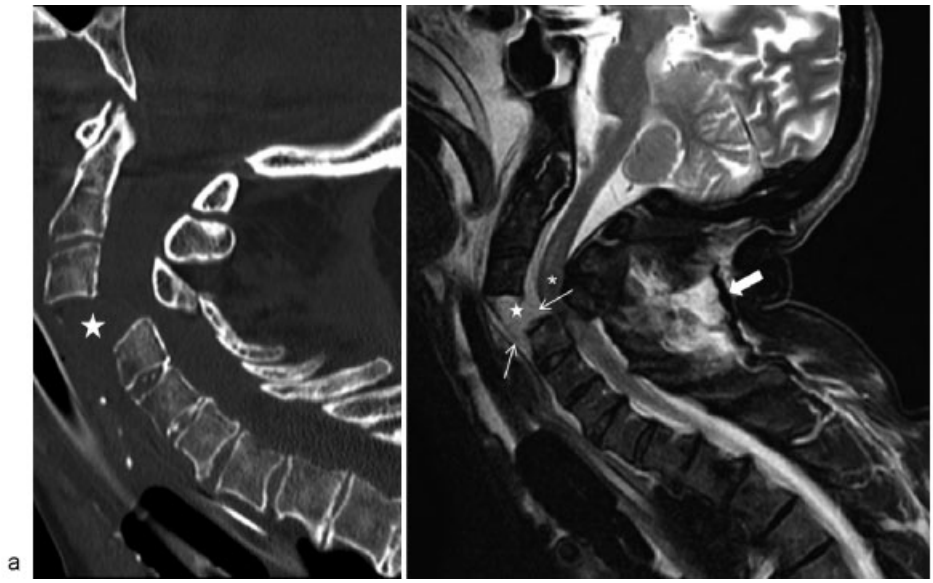

Fig. 12 Transdiscal fracture following a distraction injury, with severe vertebral translation. (**a**) Sagittal computed tomography reformations and (**b**) T2-weighted short tau inversion recovery MRI acquisitions show a large intersomatic C3–C4 space widening (white star), posterior soft tissue edema (plain arrow), spinal cord contusions (asterisk), and disruption of the anterior and posterior vertebral longitudinal ligaments (thin arrows).

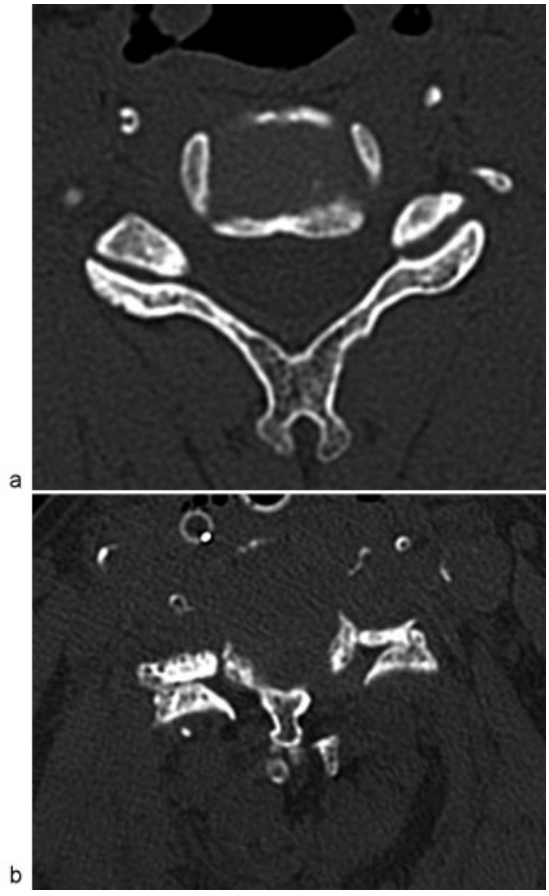

Fig. 13 Axial computed tomography reformations showing normal articular facets (**a**) that are reversed when dislocated ("reverse hamburger sign," **b**).

down to the arms. However, in the presence of an isolated spinous process fracture, further neuroradiologic investigations should be performed to rule out concomitant cervical fractures or additional spinal column injuries.[75]

On anteroposterior views, clay-shoveler's fractures appear as a double spinous process shadow at the affected level.[76] Downward displacement of fractured bone fragments can be seen on lateral views. CT and MRI of the cervical spine may be useful for detecting more serious spinal fractures. MRI is especially useful in demonstrating ligamentous disruptions. Anterior longitudinal ligament and anterior annulus fibrosus injuries can be associated because these findings are related to a common mechanism through cervical hyperextension.

Conclusion

Confirmed cervical spine injuries are uncommon, but because unstable lesions can lead to severe neurologic complications, rigorous imaging management and interpretation are required. In a patient not demonstrating low-risk criteria, CT imaging is mandated if available, especially for unconscious, intermediate-risk, and high-risk patients, supplemented with MRI when a discoligamentous or spinal cord injury is suspected.

References

1 Lenehan B, Boran S, Street J, Higgins T, McCormack D, Poynton AR. Demographics of acute admissions to a National Spinal Injuries Unit. Eur Spine J 2009;18(07):938–942
2 Goldberg W, Mueller C, Panacek E, Tigges S, Hoffman JR, Mower WR; NEXUS Group. Distribution and patterns of blunt traumatic cervical spine injury. Ann Emerg Med 2001;38(01):17–21

3 Greenbaum J, Walters N, Levy PD. An evidenced-based approach to radiographic assessment of cervical spine injuries in the emergency department. J Emerg Med 2009;36(01):64–71
4 Varma A, Hill EG, Nicholas J, Selassie A. Predictors of early mortality after traumatic spinal cord injury: a population-based study. Spine 2010;35(07):778–783
5 Inaba K, Byerly S, Bush LD, et al; WTA C-Spine Study Group. Cervical spinal clearance: a prospective Western Trauma Association Multi-Institutional Trial. J Trauma Acute Care Surg 2016; 81(06):1122–1130
6 Hoffman JR, Mower WR, Wolfson AB, Todd KH, Zucker MI; National Emergency X-Radiography Utilization Study Group. Validity of a set of clinical criteria to rule out injury to the cervical spine in patients with blunt trauma. N Engl J Med 2000;343(02):94–99
7 Stiell IG, Clement CM, McKnight RD, et al. The Canadian C-spine rule versus the NEXUS low-risk criteria in patients with trauma. N Engl J Med 2003;349(26):2510–2518
8 Stiell IG, Wells GA, Vandemheen KL, et al. The Canadian C-spine rule for radiography in alert and stable trauma patients. JAMA 2001;286(15):1841–1848
9 Westerveld LA, Verlaan JJ, Oner FC. Spinal fractures in patients with ankylosing spinal disorders: a systematic review of the literature on treatment, neurological status and complications. Eur Spine J 2009;18(02):145–156
10 Daffner RH, Hackney DB. ACR Appropriateness Criteria on suspected spine trauma. J Am Coll Radiol 2007;4(11):762–775
11 Bailitz J, Starr F, Beecroft M, et al. CT should replace three-view radiographs as the initial screening test in patients at high, moderate, and low risk for blunt cervical spine injury: a prospective comparison. J Trauma 2009;66(06):1605–1609
12 Blackmore CC, Ramsey SD, Mann FA, Deyo RA. Cervical spine screening with CT in trauma patients: a cost-effectiveness analysis. Radiology 1999;212(01):117–125
13 Daffner RH. Cervical radiography for trauma patients: a time-effective technique? AJR Am J Roentgenol 2000;175(05):1309–1311
14 Ryken TC, Hadley MN, Walters BC, et al. Radiographic assessment. Neurosurgery 2013;72(Suppl 2):54–72
15 Rozzelle CJ, Aarabi B, Dhall SS, et al. Management of pediatric cervical spine and spinal cord injuries. Neurosurgery 2013; 72(Suppl 2):205–226
16 Daffner RH, Harris JH. Cervical Spine Injuries. 5th ed. Philadelphia, PA: Lippincott Williams & Wilkins; 2013:139–260
17 Hanson JA, Deliganis AV, Baxter AB, et al. Radiologic and clinical spectrum of occipital condyle fractures: retrospective review of 107 consecutive fractures in 95 patients. AJR Am J Roentgenol 2002;178(05):1261–1268
18 Garrett M, Consiglieri G, Kakarla UK, Chang SW, Dickman CA. Occipitoatlantal Dislocation. Neurosurgery 2010;66(03, Suppl 3): A48–A55
19 Karam YR, Traynelis VC. Occipital condyle fractures. Neurosurgery 2010;66(03, Suppl 3):A56–A59
20 Klimo P Jr, Rao G, Brockmeyer D. Congenital anomalies of the cervical spine. Neurosurg Clin N Am 2007;18(03):463–478
21 Lustrin ES, Karakas SP, Ortiz AO, et al. Pediatric cervical spine: normal anatomy, variants, and trauma. Radiographics 2003; 23(03):539–560
22 Harris JH Jr, Carson GC, Wagner LK. Radiologic diagnosis of traumatic occipitovertebral dissociation: 1. Normal occipitovertebral relationships on lateral radiographs of supine subjects. AJR Am J Roentgenol 1994;162(04):881–886
23 Harris JH Jr, Carson GC, Wagner LK, Kerr N. Radiologic diagnosis of traumatic occipitovertebral dissociation: 2. Comparison of three methods of detecting occipitovertebral relationships on lateral radiographs of supine subjects. AJR Am J Roentgenol 1994; 162(04):887–892
24 Wholey MH, Bruwer AJ, Baker HL Jr. The lateral roentgenogram of the neck; with comments on the atlanto-odontoid-basion relationship. Radiology 1958;71(03):350–356
25 Anderson PA, Montesano PX. Morphology and treatment of occipital condyle fractures. Spine 1988;13(07):731–736
26 Ahuja A, Glasauer FE, Alker GJ Jr, Klein DM. Radiology in survivors of traumatic atlanto-occipital dislocation. Surg Neurol 1994; 41(02):112–118
27 Tuli S, Tator CH, Fehlings MG, Mackay M. Occipital condyle fractures. Neurosurgery 1997;41(02):368–376; discussion 376–377
28 Horn EM, Feiz-Erfan I, Lekovic GP, Dickman CA, Sonntag VK, Theodore N. Survivors of occipitoatlantal dislocation injuries: imaging and clinical correlates. J Neurosurg Spine 2007;6(02): 113–120
29 Steinmetz MP, Lechner RM, Anderson JS. Atlantooccipital dislocation in children: presentation, diagnosis, and management. Neurosurg Focus 2003;14(02):ecp1
30 Theodore N, Aarabi B, Dhall SS, et al. The diagnosis and management of traumatic atlanto-occipital dislocation injuries. Neurosurgery 2013;72(Suppl 2):114–126
31 Diagnosis and Management of Traumatic Atlanto-occipital Dislocation Injuries. Neurosurgery 2002;50(Suppl 3):S105–S113
32 Rojas CA, Bertozzi JC, Martinez CR, Whitlow J. Reassessment of the craniocervical junction: normal values on CT. AJNR Am J Neuroradiol 2007;28(09):1819–1823
33 Powers B, Miller MD, Kramer RS, Martinez S, Gehweiler JA Jr. Traumatic anterior atlanto-occipital dislocation. Neurosurgery 1979;4(01):12–17
34 Lee C, Woodring JH, Goldstein SJ, Daniel TL, Young AB, Tibbs PA. Evaluation of traumatic atlantooccipital dislocations. AJNR Am J Neuroradiol 1987;8(01):19–26
35 Traynelis VC, Marano GD, Dunker RO, Kaufman HH. Traumatic atlanto-occipital dislocation. Case report. J Neurosurg 1986; 65(06):863–870
36 Marcon RM, Cristante AF, Teixeira WJ, Narasaki DK, Oliveira RP, de Barros Filho TE. Fractures of the cervical spine. Clinics (Sao Paulo) 2013;68(11):1455–1461
37 Jefferson G. Fracture of the atlas vertebra. Report of four cases, and a review of those previously recorded. Br J Surg 1919;7(27): 407–422
38 Matthiessen C, Robinson Y. Epidemiology of atlas fractures–a national registry-based cohort study of 1,537 cases. Spine J 2015;15(11):2332–2337
39 Kakarla UK, Chang SW, Theodore N, Sonntag VK. Atlas fractures. Neurosurgery 2010;66(03, Suppl 3):A60–A67
40 Hadley MN, Dickman CA, Browner CM, Sonntag VK. Acute traumatic atlas fractures: management and long term outcome. Neurosurgery 1988;23(01):31–35
41 Gehweiler J, Duff D, Martinez S, Miller MD, Clark WM. Fractures of the atlas vertebra. Skeletal Radiol 1976;1(02):97–102
42 Landells CD, Van Peteghem PK. Fractures of the atlas: classification, treatment and morbidity. Spine 1988;13(05):450–452
43 Radcliff KE, Sonagli MA, Rodrigues LM, Sidhu GS, Albert TJ, Vaccaro AR. Does C_1 fracture displacement correlate with transverse ligament integrity? Orthop Surg 2013;5(02):94–99
44 Harrop JS, Sharan AD, Przybylski GJ. Epidemiology of spinal cord injury after acute odontoid fractures [abstract]. Neurosurg Focus 2000;8(06):e4
45 Pepin JW, Bourne RB, Hawkins RJ. Odontoid fractures, with special reference to the elderly patient. Clin Orthop Relat Res 1985;(193): 178–183
46 Ryan MD, Taylor TK. Odontoid fractures in the elderly. J Spinal Disord 1993;6(05):397–401
47 Anderson LD, D'Alonzo RT. Fractures of the odontoid process of the axis. J Bone Joint Surg Am 1974;56(08):1663–1674
48 Wilson J, Harrop J. Update on upper cervical spine injury classifications. Semin Spine Surg 2017;29(01):9–13
49 Pal D, Sell P, Grevitt M. Type II odontoid fractures in the elderly: an evidence-based narrative review of management. Eur Spine J 2011;20(02):195–204

50 Roy-Camille R, Saillant G, Judet T, de Botton G, Michel G. Factors of severity in the fractures of the odontoid process [in French]. Rev Chir Orthop Repar Appar Mot 1980;66(03):183–186
51 Rozzelle CJ, Aarabi B, Dhall SS, et al. Os odontoideum. Neurosurgery 2013;72(Suppl 2):159–169
52 Ryken TC, Hadley MN, Aarabi B, et al. Management of isolated fractures of the axis in adults. Neurosurgery 2013;72(03, Suppl 2): 132–150
53 Gleizes V, Jacquot FP, Signoret F, Féron JM. Combined injuries in the upper cervical spine: clinical and epidemiological data over a 14-year period. Eur Spine J 2000;9(05):386–392
54 Garber JN. Abnormalities of the atlas and axis vertebrae—congenital and traumatic. J Bone Joint Surg Am 1964;46(08): 1782–1791
55 Barros TE, Bohlman HH, Capen DA, et al. Traumatic spondylolisthesis of the axis: analysis of management. Spinal Cord 1999; 37(03):166–171
56 Effendi B, Roy D, Cornish B, Dussault RG, Laurin CA. Fractures of the ring of the axis. A classification based on the analysis of 131 cases. J Bone Joint Surg Br 1981;63-B(03):319–327
57 Levine AM, Edwards CC. The management of traumatic spondylolisthesis of the axis. J Bone Joint Surg Am 1985;67(02):217–226
58 Passias PG, Wang S, Kozanek M, Wang S, Wang C. Relationship between the alignment of the occipitoaxial and subaxial cervical spine in patients with congenital atlantoxial dislocations. J Spinal Disord Tech 2013;26(01):15–21
59 Yin Y-H, Qiao G-Y, Yu X-G, Tong H-Y, Zhang Y-Z. Posterior realignment of irreducible atlantoaxial dislocation with C1-C2 screw and rod system: a technique of direct reduction and fixation. Spine J 2013;13(12):1864–1871
60 Sobolewski BA, Mittiga MR, Reed JL. Atlantoaxial rotary subluxation after minor trauma. Pediatr Emerg Care 2008;24(12): 852–856
61 Dickman CA, Greene KA, Sonntag VK. Injuries involving the transverse atlantal ligament: classification and treatment guidelines based upon experience with 39 injuries [abstract]. Neurosurgery 1996;38(01):44–50
62 Jackson RS, Banit DM, Rhyne AL III, Darden BV II. Upper cervical spine injuries. J Am Acad Orthop Surg 2002;10(04):271–280
63 Wang S, Wang C, Yan M, Zhou H, Dang G. Novel surgical classification and treatment strategy for atlantoaxial dislocations. Spine 2013;38(21):E1348–E1356
64 Fielding JW, Hawkins RJ. Atlanto-axial rotatory fixation. (Fixed rotatory subluxation of the atlanto-axial joint) [abstract]. J Bone Joint Surg Am 1977;59(01):37–44
65 Kowalski HM, Cohen WA, Cooper P, Wisoff JH. Pitfalls in the CT diagnosis of atlantoaxial rotary subluxation. AJR Am J Roentgenol 1987;149(03):595–600
66 Vaccaro AR, Hulbert RJ, Patel AA, et al; Spine Trauma Study Group. The subaxial cervical spine injury classification system: a novel approach to recognize the importance of morphology, neurology, and integrity of the disco-ligamentous complex. Spine 2007; 32(21):2365–2374
67 Aarabi B, Walters BC, Dhall SS, et al. Subaxial cervical spine injury classification systems. Neurosurgery 2013;72(Suppl 2):170–186
68 Favero KJ, Van Peteghem PK. The quadrangular fragment fracture. Roentgenographic features and treatment protocol. Clin Orthop Relat Res 1989;239(239):40–46
69 Korres D, Benetos I, Evangelopoulos D, et al. Tear-drop fractures of the lower cervical spine: classification and analysis of 54 cases. Eur J Orthop Surg Traumatol 2007;17(06):521–526
70 Allen BL Jr, Ferguson RL, Lehmann TR, O'Brien RP. A mechanistic classification of closed, indirect fractures and dislocations of the lower cervical spine. Spine 1982;7(01):1–27
71 Anderson SE, Boesch C, Zimmermann H, et al. Are there cervical spine findings at MR imaging that are specific to acute symptomatic whiplash injury? A prospective controlled study with four experienced blinded readers. Radiology 2012;262(02):567–575
72 Palmieri F, Cassar-Pullicino VN, Dell'Atti C, et al. Uncovertebral joint injury in cervical facet dislocation: the headphones sign. Eur Radiol 2006;16(06):1312–1315
73 Shanmuganathan K, Mirvis SE, Levine AM. Rotational injury of cervical facets: CT analysis of fracture patterns with implications for management and neurologic outcome. AJR Am J Roentgenol 1994;163(05):1165–1169
74 Hirsh LF, Duarte LE, Wolfson EH, Gerhard W. Isolated symptomatic cervical spinous process fracture requiring surgery. Case report. J Neurosurg 1991;75(01):131–133
75 Meyer PG, Hartman JT, Leo JS. Sentinel spinous process fractures. Surg Neurol 1982;18(03):174–178
76 Solaroğlu I, Kaptanoğlu E, Okutan O, Beşkonakli E. Multiple isolated spinous process fracture (Clay-shoveler's fracture) of cervical spine: a case report. Ulus Travma Acil Cerrahi Derg 2007;13(02):162–164