# Pedicled Transfer of the Superficial Inguinal Lymph Node Flap for Lymphedema

Theodore A. Kung, MD[1] Nicole M. Duggan, BA[2] Peter C. Neligan, MB, FRCS(I), FRCSC, FACS[2]

[1] Section of Plastic and Reconstructive Surgery, Department of Surgery, University of Michigan, Ann Arbor, Michigan
[2] Division of Plastic Surgery, Department of Surgery, University of Washington, Seattle, Washington

J Reconstr Microsurg Open 2017;2:e29–e34.

**Address for correspondence** Peter C. Neligan, MD, FRCS(I), FRCSC, FACS, Division of Plastic Surgery, Center for Reconstructive Surgery, University of Washington Medical Center, 1959 NE Pacific Street, Box 356410, Room BB487, Seattle, WA 98195-6410 (e-mail: pneligan@uw.edu).

## Abstract

**Background** Vascularized lymph node transfer is performed for select patients with lymphedema who remain refractory to nonsurgical therapies. Typically, this involves a microvascular free tissue transfer of donor lymph nodes to the affected area. We describe our experience with the transfer of a pedicled adipofascial flap containing the superficial inguinal lymph nodes for lower extremity lymphedema or penoscrotal lymphedema.

**Methods** In eight patients, a unilateral pedicled superficial inguinal lymph node flap was harvested. The flap consisted of subscarpal adipofascial tissue between the level of the inguinal ligament and the groin crease. Blood supply was from either the superficial circumflex iliac vessels or the superficial inferior epigastric vessels. In certain patients, concurrent lymphaticovenular anastomosis was attempted as well.

**Results** Four patients underwent pedicled superficial inguinal lymph node flap transfer for lower extremity lymphedema and for the other four patients the indication was penoscrotal lymphedema. Seven of the eight study patients reported improvements in their lymphedema symptoms. Postoperative complications included cellulitis in one patient and hematoma in another patient; neither patient required reoperation.

**Conclusion** The pedicled superficial inguinal lymph node flap is a feasible and safe treatment option for either lower extremity lymphedema or genital lymphedema. This case series provides the basis for additional studies regarding the potential use of this vascularized lymph node flap in select patients.

**Keywords**
- lymphedema
- vascularized lymph node transfer
- lymphaticovenular anastomosis

Lymphedema is characterized by the accumulation of lymph fluid within the subcutaneous tissues resulting in a state of chronic inflammation that over time leads to fibrosis and further disruption of lymphatic drainage.[1] Recent studies have shown that select patients with lymphedema may benefit from vascularized lymph node transfer (VLNT) procedures.[2] These reports have largely focused on patients with extremity lymphedema, particularly in situations where normal lymphatic drainage has been interrupted by previous lymphadenectomy and radiotherapy. One theory for how this occurs is that the transferred lymph nodes produce vascular endothelial growth factor (VEGF), a signaling protein that stimulates lymphangiogenesis in the recipient site.[3] Another prominent theory emphasizes that an inherent pump mechanism within transferred lymph nodes facilitates the absorption of surrounding interstitial fluid and returns this fluid back to the venous circulation.[4,5] Although the exact mechanism is still under investigation; it is clear that some patients certainly benefit from VLNT and exhibit measurable reductions of limb volume and circumference.

**received**
December 31, 2016
**accepted after revision**
February 21, 2017

**DOI** http://dx.doi.org/10.1055/s-0037-1601434.
**ISSN** 2377-0813.

Copyright © 2017 by Thieme Medical Publishers, Inc., Inc., 333 Seventh Avenue, New York, NY 10001, USA Tel: +1(212) 584-4662.

License terms

VLNT is usually performed as a free tissue transfer of an adipofascial or fasciocutaneous flap containing lymph nodes. However, based on anatomic studies of the lymphatic drainage of the lower abdomen, groin, and thigh,[6–9] transfer of a pedicled superficial inguinal lymph node flap is feasible and may augment lymphatic drainage from either the proximal thigh or genital region.[10,11] This case series describes our experience with the superficial inguinal lymph node flap and emphasizes its potential use in the treatment of lower extremity lymphedema and penoscrotal lymphedema.

## Methods

A retrospective review was conducted on patients with symptomatic lymphedema who underwent pedicled superficial inguinal lymph node flap transfer. Two subgroups were identified: (1) patients with lower extremity lymphedema with progressive symptoms despite maximal nonsurgical management, and (2) patients with penoscrotal lymphedema who were candidates for a radical debulking operation according to the referring urologist. Medical records were examined for pertinent information such as patient age, etiology of lymphedema, disease duration, and postoperative complications.

A unilateral pedicled superficial inguinal lymph node transfer was performed under general anesthesia on an outpatient basis. In some patients, lymphaticovenular anastomosis (LVA) was performed either in a separate operation before VLNT or concurrently with VLNT. None of the patients had undergone a previous VLNT for their lymphedema. After surgical site preparation, the isosulfan blue dye was injected subdermally into the lower abdomen on the donor side. This facilitated intraoperative identification of the superficial inguinal lymph nodes during harvest. Identification entailed the detection of a bluish blush within the subcutaneous portion of the flap; actual dissection and visualization of individual lymph nodes were not done to preserve the vascularity of the nodes. The flap was raised with ample subscarpal adipofascial tissue located between the inguinal ligament and the groin crease (►**Fig. 1**). Blood supply to the flap was confirmed by intraoperative fluorescent angiography. Once adequate length was achieved, the flap was tunneled to the recipient site and secured with absorbable sutures. For lower extremity lymphedema, the flap was positioned overlying the femoral triangle (►**Fig. 2**); for genital lymphedema, the flap was tunneled to the base of the penis and scrotum through a separate incision.

Postoperatively, patients were instructed to continue their existing nonsurgical therapy for lymphedema, such as elevation and the use of compression garments. Patients presented for follow-up at 1 week and subsequently at approximately 3-month intervals to evaluate the status of

**Fig. 1** A left-pedicled superficial inguinal lymph node flap for penoscrotal lymphedema. Above, left: A 34-year-old male patient with longstanding idiopathic penoscrotal lymphedema resulting in functional difficulties. Above, right: An incision is made in the lower abdomen. Note the marked groin crease and the position of the inguinal ligament (double lines). A flap consisting of adipofascial tissue containing the superficial inguinal lymph nodes is harvested. It is important not to carry the dissection inferior to the groin crease to avoid disruption to the lymph nodes that drain the lower extremity. Note that indocyanine green has been injected into the skin of the penis to facilitate intraoperative lymphangiography. Below, left: The flap is primarily based on the superficial circumflex iliac vessels and can easily reach the base of the penis and scrotum. Below, right: Flap inset at the base of the penis and scrotum.

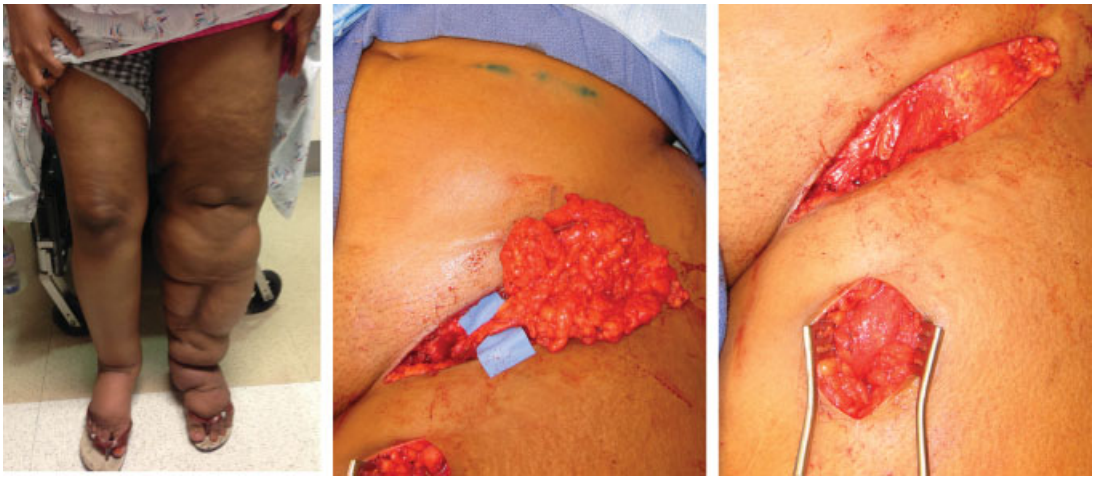

**Fig. 2** A left-pedicled superficial inguinal lymph node flap for left lower extremity lymphedema. Left: A 20-year-old female patient with bilateral lower extremity lymphedema (left worse than right) resulting from prior groin trauma. Middle: Adipofascial tissue containing the superficial inguinal lymph nodes is harvested on the superficial circumflex iliac vessels. Note the use of indocyanine green to confirm the presence of lymph nodes within the flap. Right: The flap is inset into the femoral triangle after excision of any scar tissue.

their lymphedema. Patient-reported subjective improvements in lymphedema symptoms, such as decreased heaviness of the affected area or reduction in soft tissue turgor, were documented in the medical record.

## Results

A total of eight patients were treated with a pedicled superficial inguinal lymph node flap (►**Table 1**). In four patients the operation was performed for lower extremity lymphedema; in the other four patients, the indication was penoscrotal lymphedema. All flaps were harvested without difficulty; seven were based on the superficial circumflex iliac vessels, and in one patient the superficial inferior epigastric vessels were chosen. Average follow-up for all eight patients was 9.5 months. However, in one patient, the follow-up interval was much longer at 36 months; without this patient's follow-up factored in, the mean follow-up of the remaining seven patients was 5.7 months. These seven patients demonstrated subjective improvement in their lymphedema symptoms. Improvement in lymphedema symptoms was determined by the patient reporting a decrease in heaviness, swelling, or skin changes to the affected area, either the lower extremity or the penis/scrotum. Follow-up nuclear studies were not performed to avoid the use of radioactive tracer. Serial circumferential measurements of the affected area were often performed; however, this study lacked sufficient power to account for the known variability of these measurements. Therefore, we found that the most reliable and promising results were patient-reported testimonies regarding their lymphedema experience.

One of the penoscrotal lymphedema patients suffered from postoperative cellulitis at the donor site, and this was successfully treated with oral antibiotics on an outpatient basis. Another patient who was in the lower extremity cohort presented with a small hematoma at the proximal thigh recipient site and this was treated expectantly with conservative management. Among patients with existing lower extremity lymphedema, none reported worsening of their symptoms after flap harvest; among patients with penoscrotal lymphedema, none reported iatrogenic donor-site lymphedema.

## Discussion

A pedicled superficial inguinal lymph node transfer is a feasible and safe option for patients with either lower extremity or genital lymphedema. The flap includes a large volume of well-vascularized adipofascial tissue that easily reaches the proximal thigh or the pubis. The pedicled technique obviates the need for microsurgical anastomoses that would otherwise be required if lymph nodes from another donor site were transferred. Blood supply is primarily based on the superficial circumflex iliac vessels and, rarely, the superficial inferior epigastric vessels.[7] Flap viability is expectedly robust and can be readily verified intraoperatively through the use of fluorescent angiography. Additionally, should the lymphedema continue to progress, a pedicled superficial inguinal lymph node transfer does not preclude further surgical intervention in the future.

Previous studies in animals and humans have reported the potential of pedicled abdominal flaps to treat lymphedema.[10–13] We hypothesize that pedicled transfer of the superficial inguinal lymph node flap augments drainage of lymph fluid from the lower extremity or external genitalia through VEGF-mediated lymphangiogenesis as well as favorable repositioning of afferent lymphatic collectors. Typically, the superficial inguinal lymph node flap contains around four to eight lymph nodes that are concentrated at a point approximately one-half of the distance from the pubic tubercle to the anterior superior iliac spine.[7,8] Therefore, adequate mobilization of the vascular pedicle is necessary to maximize the reach of the superficial inguinal lymph nodes. Additionally, it is known that multiple afferent

**Table 1** Patients treated with a pedicled superficial inguinal lymph node flap for lymphedema

| Patient no. | Age (y) | Sex | Lymphedema type | Lymphedema etiology | Duration of symptoms (y) | Lymphaticovenular anastomosis performed? | Postoperative complications | Follow-up (mo) | Subjective improvement |
|---|---|---|---|---|---|---|---|---|---|
| 1 | 20 | Female | Lower extremity | Secondary to groin trauma | 6 | No | None | 3 | Yes |
| 2 | 22 | Female | Lower extremity | Secondary to biopsy of an inflammatory lymph node in the groin | 4 | Yes; concurrent | None | 5 | Yes |
| 3 | 27 | Male | Penoscrotal | Idiopathic | 3 | No; attempted | None | 5 | Yes |
| 4 | 33 | Male | Penoscrotal | Secondary to scrotal surgery for benign hematoma | 10 | Yes; prior | None | 36 | No |
| 5 | 34 | Male | Penoscrotal | Idiopathic | 10 | No; attempted | Cellulitis | 6 | Yes |
| 6 | 57 | Male | Penoscrotal | Idiopathic | 2 | No; attempted | None | 6 | Yes |
| 7 | 67 | Female | Lower extremity | Secondary to groin lymph node dissection for melanoma | 1 | No | Hematoma | 9 | Yes |
| 8 | 69 | Male | Lower extremity | Secondary to femoral-popliteal bypass | 6 | Yes; concurrent | None | 6 | Yes |

lymphatic collectors are present within the subscarpal fat of the lower abdomen.[9] These lymphatic channels drain lymph from the lower abdomen into the superficial inguinal lymph nodes and subsequently into the pelvis.[8] By turning over the superficial inguinal lymph node flap from it native location to either the pubis or proximal thigh, the afferent collectors within the flap may help facilitate the drainage of excess lymphatic fluid in these locations.

A potential relative contraindication for the superficial inguinal lymph node flap is a history of ipsilateral groin lymphadenectomy because the superior limit of dissection for this procedure is commonly the inguinal ligament. This results in the removal of the superficial inguinal lymph nodes as well as possible injury of both superficial circumflex iliac and superficial inferior epigastric pedicles. A contralateral superficial inguinal lymph node flap may still be used for cases of penoscrotal lymphedema, but its length cannot be expected to reach the thigh on the other side. One patient in our study cohort (#7) who developed right lower extremity lymphedema after groin lymphadenectomy underwent successful transfer of an ipsilateral superficial inguinal lymph node flap. In this patient, surgery was offered to first excise extensive scarring at the site of previous inguinal node dissection. Intraoperatively, indocyanine green was injected subdermally into the lower abdomen and lymph nodes were identified within the adipofascial tissue overlying the inguinal ligament. Intact superficial inferior epigastric vessels were also found and were selected as the pedicle for the flap.

Patients with lower extremity lymphedema experience uncomfortable swelling the leg that often progresses in a distal-to-proximal fashion, resulting in functional limitations and decreased the quality of life.[14] Those with penoscrotal lymphedema commonly report problems with voiding, ambulation, hygiene, and sexual activity. All patients with lymphedema are predisposed to recurrent episodes of skin infections which can further impair lymphatic drainage.[15] Conservative management, including the use of compression wraps, elevation, and exercises, should be prescribed as soon as possible, but effective application remains quite challenging. This is especially true for penoscrotal lymphedema due to understandable anatomic constraints. Consequently, some patients with functionally limiting disease are offered radical resection of lymphedematous tissues followed by skin grafting.[16–18] However, we suggest that in carefully selected patients lymphatic surgery may provide an effective alternative to radical resection.

VLNT may be performed in conjunction with LVA or at a separate surgery. Concurrent or previous LVA was possible in only three of our eight study patients; of these, two displayed improvement of lymphedema symptoms. The degree to which symptomatic improvement can be attributed to LVA versus lymph node transfer is presently unknown and should be the focus of future investigation. In lower extremity lymphedema, LVA is frequently performed when functional lymphatic vessels can be identified. In these patients, VLNT using the pedicled superficial inguinal lymph nodes may be performed in addition to LVA to enhance lymphatic drainage from the lower extremity, especially in situations of previous

**Fig. 3** A left-pedicled superficial inguinal lymph node flap for penoscrotal lymphedema. Left: A 27-year-old man with idiopathic penoscrotal lymphedema. Intraoperative lymphangiography showed some evidence of residual lymphatic vessels; however, the lymphaticovenular anastomosis was attempted but not successful due to extensive subcutaneous fibrosis. Right: At 5-month follow-up, the patient reported improvement in the feeling of heaviness of the penis and scrotum. Also, the penis was softer to palpation and demonstrated a reduced circumference especially at the base.

lymphadenectomy and radiation therapy. In patients with penoscrotal lymphedema, "lymphangioplasty" techniques have been performed historically with questionable benefit,[19] although recently some authors report more promising results with LVA.[20] Therefore, in this clinical setting, we believe that LVA should also be performed in conjunction with VLNT whenever possible. However, it is important to note that longstanding lymphedema commonly results in chronic inflammation that causes considerable soft tissue fibrosis that can often make LVA unfeasible in penoscrotal disease (►**Fig. 3**). In three of our cases of penoscrotal lymphedema, LVA was attempted, but no suitable lymphatic channels were found in the subcutaneous tissues of the penis or scrotum.

A rare but devastating complication of lymph node transfer is the incitement of symptomatic lymphedema in the donor site.[21] During the harvest of a pedicled superficial inguinal lymph node flap, reverse lymph node mapping can assist in preserving the deep nodes that drain the lower extremity.[22] While this technique was not used in our series of patients, future studies will consider reverse lymph node mapping as an important adjunct to lymph node flap harvest as a measure to reduce the risk of iatrogenic lymphedema. Also, research has shown that maintaining a dissection level superior to the groin crease avoids disruption of these critical deeper nodes.[9] Therefore, the pedicled technique allows for the expeditious and reliable transfer of vascularized lymph nodes with minimal risk of iatrogenic lymphedema.

## Conclusion

In this case series, we present the use of a pedicled superficial inguinal lymph node flap for treatment of lower extremity lymphedema and penoscrotal lymphedema. These promising results encourage further investigation into the potential utility of this flap in these clinical scenarios. Additional insights into the anatomical basis of this flap and quantification of its effect in reducing accumulated lymph fluid will help define its role in the surgical treatment of lymphedema.

**Funding**
None.

## References

1 Ghanta S, Cuzzone DA, Torrisi JS, et al. Regulation of inflammation and fibrosis by macrophages in lymphedema. Am J Physiol Heart Circ Physiol 2015;308(09):H1065–H1077
2 Raju A, Chang DW. Vascularized lymph node transfer for treatment of lymphedema: a comprehensive literature review. Ann Surg 2015;261(05):1013–1023
3 Aschen SZ, Farias-Eisner G, Cuzzone DA, et al. Lymph node transplantation results in spontaneous lymphatic reconnection and restoration of lymphatic flow. Plast Reconstr Surg 2014; 133(02):301–310
4 Ito R, Zelken J, Yang CY, Lin CY, Cheng MH. Proposed pathway and mechanism of vascularized lymph node flaps. Gynecol Oncol 2016;141(01):182–188
5 Cheng MH, Huang JJ, Wu CW, et al. The mechanism of vascularized lymph node transfer for lymphedema: natural lymphaticovenous drainage. Plast Reconstr Surg 2014;133(02):192e–198e
6 Tourani SS, Taylor GI, Ashton MW. Anatomy of the superficial lymphatics of the abdominal wall and the upper thigh and its implications in lymphatic microsurgery. J Plast Reconstr Aesthet Surg 2013;66(10):1390–1395
7 Zhang H, Chen W, Mu L, et al. The distribution of lymph nodes and their nutrient vessels in the groin region: an anatomic study for design of the lymph node flap. Microsurgery 2014;34(07): 558–561
8 Scaglioni MF, Suami H. Lymphatic anatomy of the inguinal region in aid of vascularized lymph node flap harvesting. J Plast Reconstr Aesthet Surg 2015;68(03):419–427
9 Dayan JH, Dayan E, Kagen A, et al. The use of magnetic resonance angiography in vascularized groin lymph node transfer: an anatomic study. J Reconstr Microsurg 2014;30(01):41–45

10 Mihara M, Tange S, Hara H, Han Peng Z, Haragi M, Muarai N. Modified lymph vessel flap transplantation for the treatment of refractory lymphedema: A case report. Microsurgery 2016; 36(08):695–699
11 Gentileschi S, Servillo M, Garganese G, et al. The lymphatic superficial circumflex iliac vessels deep branch perforator flap: A new preventive approach to lower limb lymphedema after groin dissection-preliminary evidence. Microsurgery 2016. Doi: 10.1002/micr.30142
12 Slavin SA, Van den Abbeele AD, Losken A, Swartz MA, Jain RK. Return of lymphatic function after flap transfer for acute lymphedema. Ann Surg 1999;229(03):421–427
13 Parrett BM, Sepic J, Pribaz JJ. The contralateral rectus abdominis musculocutaneous flap for treatment of lower extremity lymphedema. Ann Plast Surg 2009;62(01):75–79
14 Cromwell KD, Chiang YJ, Armer J, et al. Is surviving enough? Coping and impact on activities of daily living among melanoma patients with lymphoedema. Eur J Cancer Care (Engl) 2015;24-(05):724–733
15 Rockson SG. The lymphatics and the inflammatory response: lessons learned from human lymphedema. Lymphat Res Biol 2013;11(03):117–120
16 Torio-Padron N, Stark GB, Földi E, Simunovic F. Treatment of male genital lymphedema: an integrated concept. J Plast Reconstr Aesthet Surg 2015;68(02):262–268
17 Modolin M, Mitre AI, da Silva JC, et al. Surgical treatment of lymphedema of the penis and scrotum. Clinics (Sao Paulo) 2006; 61(04):289–294
18 Doscher ME, Herman S, Garfein ES. Surgical management of inoperable lymphedema: the re-emergence of abandoned techniques. J Am Coll Surg 2012;215(02):278–283
19 Sauer PF, Bueschen AJ, Vasconez LO. Lymphedema of the penis and scrotum. Clin Plast Surg 1988;15(03):507–511
20 Yamamoto T, Koshima I, Yoshimatsu H, Narushima M, Miahara M, Iida T. Simultaneous multi-site lymphaticovenular anastomoses for primary lower extremity and genital lymphoedema complicated with severe lymphorrhea. J Plast Reconstr Aesthet Surg 2011;64(06):812–815
21 Vignes S, Blanchard M, Yannoutsos A, Arrault M. Complications of autologous lymph-node transplantation for limb lymphoedema. Eur J Vasc Endovasc Surg 2013;45(05):516–520
22 Dayan JH, Dayan E, Smith ML. Reverse lymphatic mapping: a new technique for maximizing safety in vascularized lymph node transfer. Plast Reconstr Surg 2015;135(01):277–285