Contrecoup Head Injury

Manpreet Singh Banga[1] Sandeep BV[1] Kaushik Roy[1] Suniti Kumar Saha[1] Sourabh Dixit[1] Partha Ghosh[1]

[1] Department of Neurosurgery, Nilratan Sircar Medical College, Sealdah, Kolkata, West Bengal, India

Indian J Neurosurg 2017;6:103–106.

Address for correspondence Manpreet Singh Banga, MCh, MS, Department of Neurosurgery, Nilratan Sircar Medical College, 138, AJC Bose Road, Sealdah, Kolkata, West Bengal 700014, India (e-mail: dr.msbanga@gmail.com).

Abstract

Contrecoup injuries comprise a group of focal brain injuries that occur at areas distant from the point of impact. It has been hypothesized that patients with contrecoup injuries would have a worse outcome because of the diffuse nature of injury. At Nilratan Sircar Medical College, Kolkata, 74 patients presenting with contrecoup injuries over a period of 1 year were prospectively analyzed. Site of primary impact was determined by clinical and CT scan criteria. The age, modes of injury, Glasgow coma scale (GCS), site of injury, pattern of injury, and mortality were analyzed. Delayed presentation of contrecoup injury in patients who deteriorated over time was also noted in imaging. The presence of contrecoup injury implies that the traumatic forces have dissipated into the brain, and from the biomechanisms explained, the brain is likely to have suffered greater damage than the case in coup injury alone. The present study shows that the presence of contrecoup contusions is associated with a poor prognosis across all GCS and age categories.

Keywords
- contrecoup
- coup
- Glasgow coma scale

Introduction

Traumatic brain injury is a leading cause of death and disability worldwide. Focal brain injuries are found in approximately one-half of all the patients with severe brain injuries and are responsible for nearly two-thirds of the deaths.[1–3] Contrecoup injuries comprise a group of focal brain injuries that occur at areas distant from the point of impact as a result of shock waves traveling across the brain causing stress/cavitation effects.[4] It is increasingly evident that the pattern of structural brain injury as visualized by imaging and the depth and duration of ischemia are also important factors in prediction of outcome.[5,6]

The presence of a contrecoup injury implies a more severe primary impact, and therefore an injury more diffuse than focal. It has been hypothesized that patients with contrecoup injuries would have a worse outcome because of the diffuse nature of injury.[7] With computed tomographic (CT) scan, it is possible to localize and delineate the type and severity of injury in the majority of head-injured patients and determine whether injuries are coup or contrecoup. Literature search reveals very few studies showing various presentations, modes of injury, and outcome of contrecoup injuries till date.

The present study was undertaken to evaluate the modes of injury and various presentations in contrecoup brain injuries. We believe that data from the present study will be a useful additional reference in head trauma cases and will increase awareness of contrecoup injuries during imaging review. Earlier detection of contrecoup injuries can minimize the complications of head trauma.

Materials and Methods

A prospective study of 1,305 patients with blunt head trauma admitted to Nilratan Sircar medical college, Kolkata, within a 12-month period was performed. The case records were studied regarding age, sex, mode of injury, Glasgow

received
September 8, 2016
accepted
January 23, 2017
published online
April 18, 2017

DOI https://doi.org/10.1055/s-0037-1601361.
ISSN 2277-954X.

coma score (GCS), and focal neurologic deficits at admission and at discharge. CT of the brain was performed in all the cases at the time of admission and after 72 hours or anytime as and when required.

- *Inclusion criteria*:
  1. Definite history of head trauma.
  2. Unequivocal evidence of a localized area of impact either in the form of fracture, scalp laceration, or galeal hematoma.
  3. Presence of contrecoup injury opposite to the site of impact or fracture, as detected in initial CT scan.
- *Exclusion criteria*:
  1. Patients with nonhemorrhagic contusions.
  2. Patients with other systemic injuries and polytrauma.
  3. Patients with associated coup injuries.

Outcomes measured in this study were the incidence of modes of injury, the various types of injury, and the mortality rate among this group.

Results

A total of 74 patients out of 1,305 had only contrecoup injury.

- *Age*: The patients' age ranged from 8 to 76 years with an average age of 38.5 years. Thirty-nine patients were younger than 40 years.
- *Modes of injury*: The most common mode of injury was road traffic accident accounting for 58.1% ($n = 43$) followed by fall 24.3% ($n = 18$) and assault 9.5% ($n = 07$). However, the cause was undetermined in 8.1% ($n = 06$) cases.
- *GCS on admission*: The GCS of the patients on admission ranged from 4 to 15 (mean: 8.20). Thirty-nine patients had GCS ≤ 8.
- *Site of contrecoup injury*: The most common site of contrecoup injury was the *temporal region* accounting for 40.5% ($n = 30$), followed by *frontal region* 29.7% ($n = 22$), *parietal region* 18.9% ($n = 14$), and *occipital region* 6.6% ($n = 5$). Three patients had hematoma in the posterior fossa.
- *Patterns of injury*: Based on the criteria, acute hemorrhagic contusion (►**Fig. 1**) was the most common pattern, followed by acute subdural hematoma (SDH), SDH with contusion (►**Fig. 2**), SDH with subarachnoid hemorrhage (SAH) (►**Fig. 3**), and acute extradural hematoma (EDH) (►**Table 1**).
- *Management*: All patients were clinically assessed and operated depending on the lesion size and mass effect as demonstrated in the CT scan. Patients in good neurologic condition with small lesion were managed conservatively. Some patients with significant injuries but with very poor GCS and absent brainstem reflexes were not operated (►**Table 2**).

Four patients in this group had normal CT scan at presentation. These patients deteriorated over a period of next 24 hours. A repeat scan showed contrecoup hematoma in the new scan. They were managed accordingly.

Discussion

Head injury is one of the most important public health problems today. The incidence of head injuries is steadily increasing all over the world and our country has the dubious distinction of having the highest incidence of head

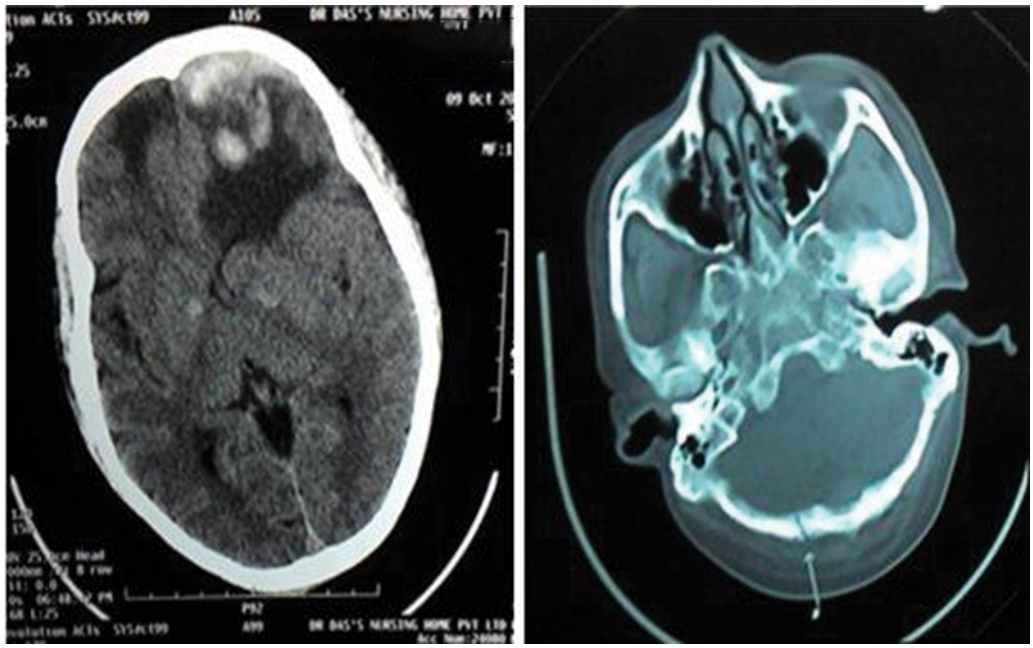

Fig. 1 Acute hemorrhagic contusion.

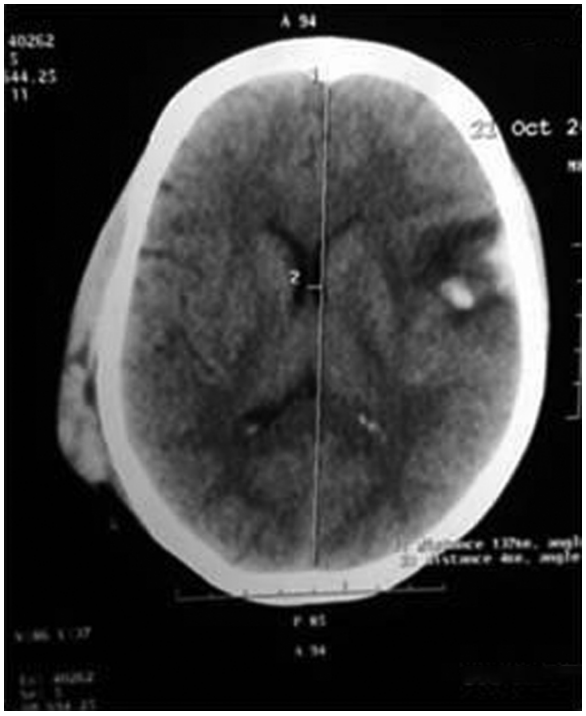

Fig. 2 Subdural hematoma with contusion.

Table 1 Patterns of head injuries

Type of lesion	No. of patients	Percentage
Contusion	38	51.4
Acute SDH	20	27
Acute SDH with contusion	12	16.2
Acute SDH with SAH	03	4
Acute EDH	01	1.4

Abbreviations: EDH, extradural hematoma; SAH, subarachnoid hemorrhage; SDH, subdural hematoma.

Table 2 Management of head injury

Management	Surgical	Conservative
Number	18	56
Improved	4	18
Remained same/deteriorated	8	12
Death	6	26

injuries in the world due to road traffic accidents per 1,000 vehicles or deaths per 1,000 accidents. The management of severe head injury is a major challenge to neurosurgeons and basic neuroscientists, as the consequent mortality and morbidity is depressingly high. There is a need for an extensive multidimensional effort to improve the prognosis of head-injured patients and provide them a better quality of life. To achieve these aims, the epidemiology of head injury needs to be known, especially the incidence and its burden on society.[8]

Brain damage in nonmissile head injury is classified as "focal" or "diffuse." The focal damage includes contusion and lacerations on the surface of the brain or intracranial hematoma and raised intracranial pressure (ICP) as a secondary phenomenon. Focal injuries result from localized damage, found in nearly 58% of patients with severe head injuries and 66% of deaths associated with head trauma.[9] Contrecoup injuries, a form of focal injuries, are well known. There are very few studies on contrecoup injuries, and their clinical significance and the outcome in this subgroup of head-injured patients are largely unknown. The biomechanics of contrecoup injuries is explained to some extent by

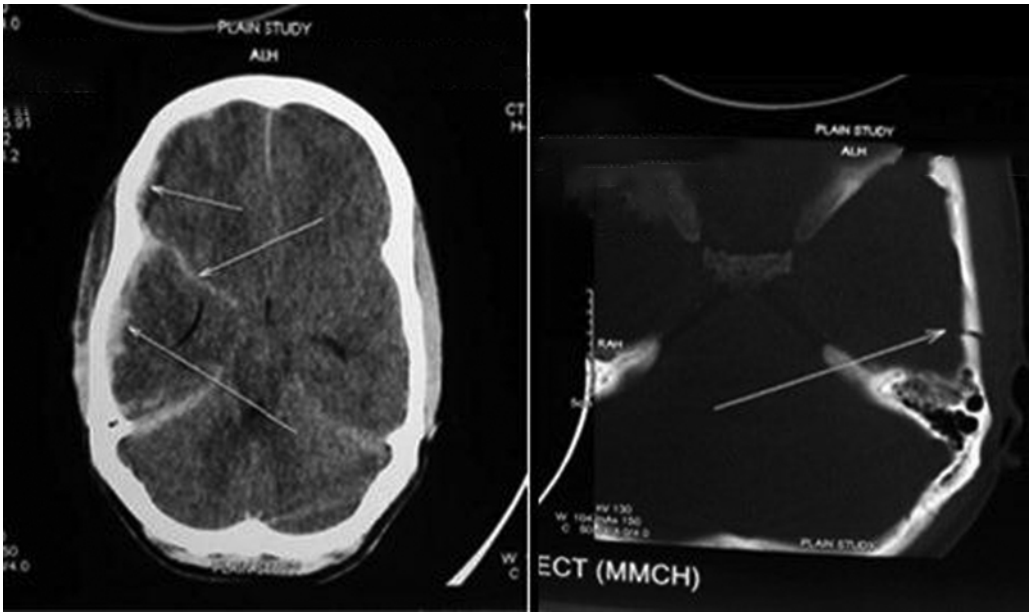

Fig. 3 Subdural hematoma with subarachnoid hemorrhage.

the shock wave theory. The shock waves that begin from the point of impact and spread through the brain may get reflected from the opposite side of the skull and reverberate within the brain. The presence of contrecoup injury implies that the traumatic forces have dissipated into the brain, and from the biomechanisms explained, the brain is likely to have suffered greater damage than the case in coup injury alone. This is reflected in the poor outcome in this subgroup of head-injured patients.[7] Four patients out of the 74 in this group had normal CT scan at presentation. These patients deteriorated over a period of next 24 hours, and a repeat scan showed contrecoup hematoma in the new scan.

In our study 74 (5.7%) patients had contrecoup injury. Jayakumar et al[10] found contrecoup injuries in 9.6% of their 650 patients. The mean age was 38.5 years with more than one-half of the patients younger than 40 years. Kraus[11] also reported the most common group affected by head injuries to be young people aged between 20 and 40 years and the incidence to be lowest at extremes of age, that is, below 5 years and above 60 years. The most common mode of injury was road traffic accident in our study accounting for more than 50%, which was similar to the study by Bhateja et al.[7] The most common injury was acute SDH followed by hemorrhagic contusions, SDH with contusion, SDH with SAH, and acute EDH. This pattern of injury also corroborated with the study of Bhateja et al[7] in which the most common injury was acute SDH followed by hemorrhagic contusions; however, the most common presentation was hemorrhagic contusion in patients with contrecoup injury by temporal bone fracture.[12]

We observed a mortality rate of 43% among this group. According to the study by Bhateja et al[7] and Jayakumar et al,[10] the mortality rates were 44% and 53%, respectively. The factors affecting mortality in our study included age of the patient and GCS at presentation. Thirty-nine patients were younger than 40 years and the mortality was 40% in this group. The mortality was 65% in patients older than 40 years. Mortality rate was higher in patients with GCS score of 8 or less, accounting for 70% compared with those with GCS score of more than 8, which accounted for 38%.

Conclusion

Contrecoup injuries are focal brain injuries that have poor prognosis. The presence of contrecoup injury implies that the traumatic forces have dissipated into the brain, and from the biomechanisms explained, the brain is likely to have suffered greater damage than the case in coup injury alone.

The present study shows that the presence of contrecoup contusions is associated with a poor prognosis across all GCS and age categories. Also, we stress that patients with poor GCS at the time of admission with minimal or no abnormality in imaging should have a repeat imaging done within the first 72 hours as they may later present with contrecoup injury.

References

1 Adams JH, Gennarelli TA, Graham DI. Brain damage in nonmissile head injury: observations in man and subhuman primates. Smith WT, Cavangh JB. Recent Advances in Neuropathology, No. 2. Edinburgh, UK: Churchill Livingstone; 1982:165–190
2 Gennarelli TA, Spielman GM, Langfitt TW, et al. Influence of the type of intracranial lesion on outcome from severe head injury. J Neurosurg 1982;56(01):26–32
3 Gennarelli TA. Head injury in man and experimental animals: clinical aspects. Acta Neurochir Suppl (Wien) 1983;32 (Suppl):1–13
4 Gennarelli TA, Meaney DF. Mechanisms of primary head injury. Wilkins RH, Rengachary SS. Neurosurgery. 2nd ed. New York, NY: McGraw-Hill; 1996:2611–2621
5 Marshall LF, Marshall SB, Klauber MR, et al. A new classification of head injury based on computerized tomography. J Neurosurg 1991;75:14–20
6 Lobato RD, Cordobes F, Rivas JJ, et al. Outcome from severe head injury related to the type of intracranial lesion. A computerized tomography study. J Neurosurg 1983;59(05):762–774
7 Bhateja A, Shukla D, Devi BI, Sastry KV. Coup and contrecoup head injuries: predictors of outcome. Indian J Neurotrauma 2009;6(02):115–118
8 Mahapatra AK, Jaiswal A. Epidemiology of head injury. Neurosci Today 2003;7:29–32
9 Graham DI, Maxwell WL, Nicoll JA. Neurotrauma. Brain Pathol 1997;7:1285
10 Jayakumar PN, Sastry Kolluri VR, Basavakumar DG, et al. Prognosis in contre-coup intracranial haematomas—a clinical and radiological study of 63 patients. Acta Neurochir (Wien) 1991;108(1–2):30–33
11 Kraus JF. Epidemiology. Elizabeth F. NINS. Head Injury Clinical Management and Research. Geneva, Switzerland: AIREN; 1990: 113–124
12 Asha'Ari ZA, Ahmad R, Rahman J, Kamarudin N, Ishlah LW. Contrecoup injury in patients with traumatic temporal bone fracture. J Laryngol Otol 2011;125(08):781–785

Erratum: This article has been updated as per the Erratum; doi: 10.1055/s-0037-1606264. The article title has been updated to "Contrecoup Head Injury".