Imaging and Intervention of Biliary Leaks and Bilomas

Harshna V. Vadvala, MD[1] Ronald S. Arellano, MD[1]

[1] Division of Interventional Radiology, Department of Radiology, Massachusetts General Hospital, Boston, Massachusetts

Dig Dis Interv 2017;1:14–21.

Address for correspondence Harshna Vadvala, MD, Division of Interventional Radiology, Department of Radiology, Massachusetts General Hospital, 55 Fruit Street, Boston, MA 02114 (e-mail: hvadvala@mgh.harvard.edu).

Abstract

Biliary leaks and bilomas develop due to hepatobiliary surgery, trauma, or locoregional therapy for hepatic malignancies. Though uncommon, they can be a source of abdominal pain, hyperbilirubinemia, and sepsis. A variety of diagnostic tools and interventional techniques are available to diagnose and manage biliary leaks and bilomas. Successful management often requires a multidisciplinary approach between the radiologist, surgeon, and endoscopist.

Keywords
- biliary leak
- biloma
- percutaneous drainage
- cholecystectomy
- thermal ablation
- transarterial chemoembolization
- radioembolization

Bilomas are intra- or extrahepatic collections of bile that develop outside of the biliary tree.[1,2] They are most commonly iatrogenic in nature and often the result of surgical procedures, transhepatic interventions, or trauma.[3–5] Clinically, bilomas can cause symptoms of pain, abdominal distention, jaundice, and leukocytosis.[6,7] Management of patients with bile duct injuries and bilomas often requires multidisciplinary efforts of radiologists, surgeons, and endoscopists to control the symptoms and the source of the biliary leak. This review discusses the etiologies and management options of bilomas.

Etiologies of Bilomas

Postsurgical

Refinements in surgical techniques have led to an overall increase in the number of hepatic resections and an overall decrease in mortality.[8] Nevertheless, the overall incidence of postoperative biliary leaks can be up to 30% and varies depending on the type of hepatic resection.[9,10] Most biliary tract-related injuries are the result of an open or laparoscopic cholecystectomy, though any type of hepatobiliary surgery can lead to biliary complications.[11–13] The morbidity of postsurgical biliary leaks relates to prolonged hospitalization and drainage from surgical drains, hyperbilirubinemia, bilomas, and abscess formation.

In a series of 340 liver resections for primary or metastatic liver tumors, Tanaka et al reported biliary-related complications of 8%.[14] The incidence of biliary leak may be related to the indication for hepatic resection: several studies have shown an increase in risk of biliary leaks following resection of malignant tumors versus benign lesions.[15–17] On the other hand, other authors have found no difference in biliary leak rates following hepatic resection for malignant or benign disease.[9,14]

Several studies assessing the various methods used to perform hepatic transections including clamp-crushing technique, harmonic scalpel, and other methods, have shown no clear association between transection methods and postoperative biliary leaks.[18–21]

Several studies have suggested that the type of hepatic resection may be a more important risk factor than the type of tumor removed.[9,16,17,22–24] Complex hepatic resections such as central hepatectomy, segment 4 resection, and caudate lobe resection, as well as left trisegmentectomy, are all associated with higher rates of biliary leakage when compared with less complex resections.[9,22,25]

received
January 23, 2017
accepted after revision
February 7, 2017
published online
March 28, 2017

Issue Theme Biliary Diseases and Interventions; Guest Editor, Ronald S. Arellano, MD

DOI https://doi.org/10.1055/s-0037-1600118.
ISSN 2472-8721.

Over the past 30 years, laparoscopic cholecystectomy has been widely adopted by general surgeons as well as hepatobiliary surgeons as the preferred surgical method for patients with symptomatic cholecystitis. Though laparoscopic cholecystectomy is associated with shorter hospital recovery and lesser pain, it is also associated with a higher risk of bile duct injury when compared with open cholecystectomy.[26–28] Bile duct–related injuries occur in approximately 0.2 to 0.5% of patients who are treated with open cholecystectomy, whereas in their laparoscopic counterparts, the incidence is up to 2.7%.[29,30] The local etiology for the biliary injury can arise from several factors such as aberrant anatomy, bleeding complications that require placement of multiple surgical clips in the hepatic hilum, or thermal injury from electrocautery.[30]

Classification of Postoperative Biliary Leaks

Postoperative biliary leaks can be classified according to a system described by Nagano et al.[31] Type A leaks refer to leakage of bile from the cystic duct remnant or peripheral biliary radicles that leak into the gallbladder fossa.[32–35] These types of leaks often resolve spontaneously without the need for intervention. When persistent or enlarging, type A leaks can be managed by endoscopic insertion of a biliary stent to decompress the biliary system. Sphincterotomy is not always necessary, unless a stone or high-grade stricture is encountered.[35] This method of treatment is well tolerated and highly effective; in roughly 15 to 20% of patients, short-term percutaneous drainage of residual collections may be necessary[35–37] (►**Fig. 1**).

Type B biliary leaks occur due to incomplete closure of major bile ducts along the hepatic resection margin[31] (►**Fig. 2**). Type C injuries also involve major bile ducts, but in contrast to type B injuries, they are more proximal and often localized to the hepatic hilum. Because types B and C injuries involve larger ducts than those of type A, management often requires a combination of percutaneous drainage of extrahepatic bilomas along with endoscopic stent drainage, especially for type B injuries. In contrast to type A leaks, successful drainage by endoscopic means is approximately 75%. For the remaining 25%, decompression of the biliary tree by endoscopic means may not be feasible due to stricture or altered surgical anatomy and often requires percutaneous transhepatic cholangiogram to define the biliary anatomy and drainage of the intrahepatic bile ducts as well as percutaneous of bilomas.[36] Once percutaneous access to the biliary tree is established, a rendezvous

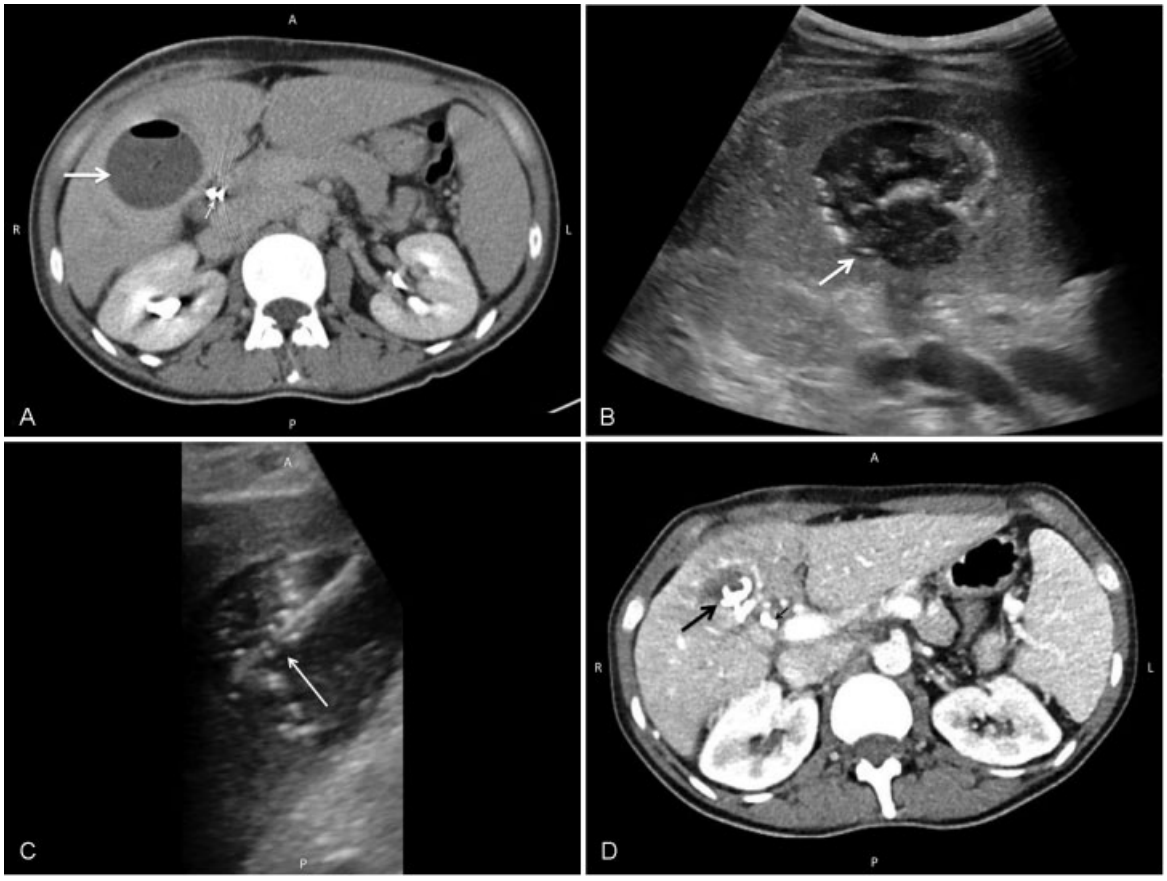

Fig. 1 (**A**) Contrast material-enhanced CT scan of a patient who developed a biloma in the gallbladder fossa (long white arrow), s/p laparoscopic cholecystectomy. Long white arrow indicates endoscopically placed biliary stents in the common bile duct. (**B**) Transverse ultrasound image of the liver that demonstrates a complex fluid collection in the gallbladder fossa, consistent with a biloma (white arrow). (**C**) Sagittal ultrasound image that demonstrates percutaneous placement of drainage catheter (white arrow) into the biloma. (**D**) Contrast material-enhanced CT that demonstrates a percutaneous placed drainage catheter into the gallbladder fossa biloma (long black arrow). Short black arrow indicates endoscopically placed biliary stents in the common bile duct.

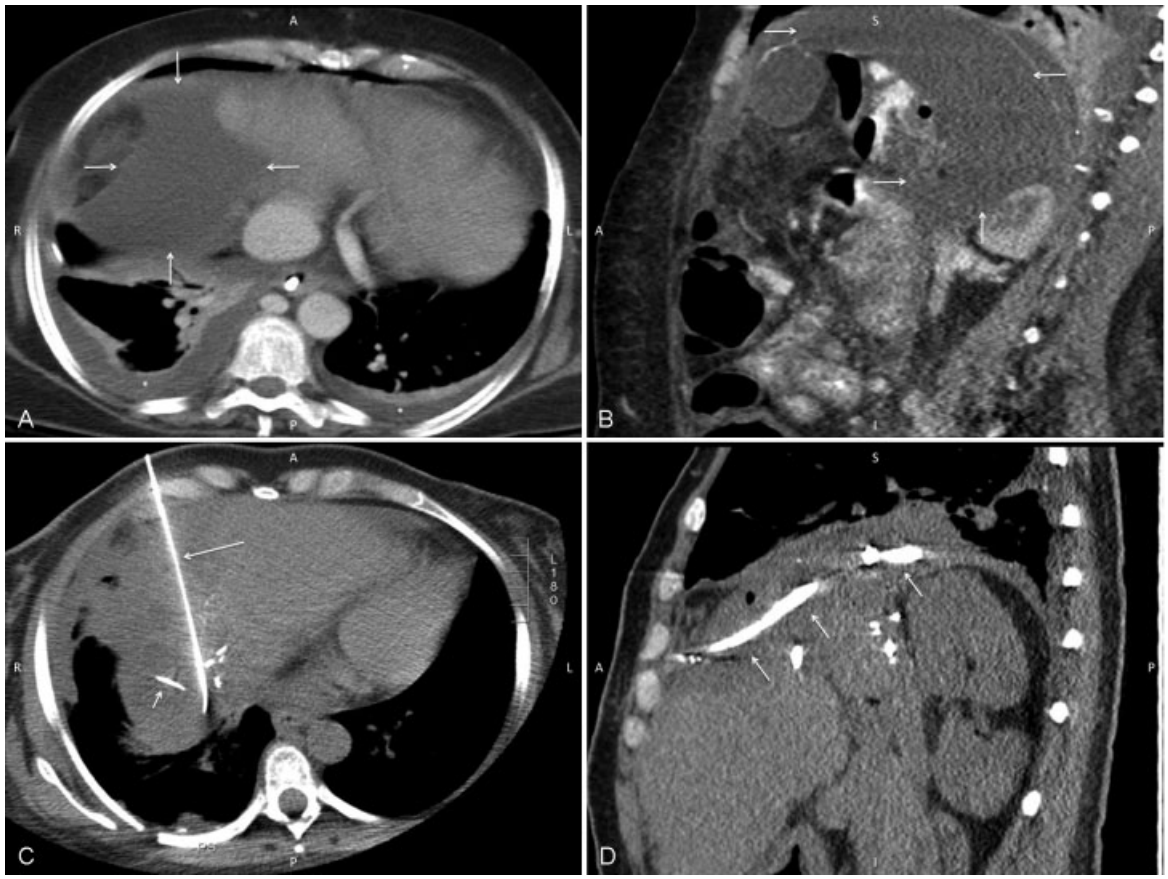

Fig. 2 (**A**) Axial contrast material-enhanced CT scan of the abdomen in a patient who is s/p right hepatectomy. White arrows outline right subphrenic biloma. White asterisks indicate bilateral pleural effusions. (**B**) Sagittal contrast material-enhanced CT scan of the abdomen in a patient who is s/p right hepatectomy. White arrows outline right subphrenic biloma. White asterisk indicates right pleural effusion. (**C**) Axial unenhanced CT scan of the abdomen that demonstrates a percutaneously placed needle (long white arrow) and guidewire (short white arrow) in the right subphrenic collection. (**D**) Sagittal unenhanced CT scan of the abdomen in a patient who is s/p right hepatectomy. White arrows outline right percutaneously placed drainage catheter into the right subphrenic biloma. White asterisks indicates atelectatic right lung.

procedure can be planned to internalize the biliary stents.[38] Type D injuries describe complete transection of distal ducts with discontinuity from the main bile ducts. Type D leakages are more challenging to control due to inability to access via endoscopic means. As a result, these types of injuries often require operative management with bilioenteric anastomosis, pharmacologic occlusion (i.e. fibrin glue, ethanol injection) of the isolated biliary radicle or operative resection of the isolated hepatic segment.[31,39–41] As an alternative to surgery, some authors have described intentional atrophy of the draining liver segment through portal vein embolization as a means to control biliary leakage.[42,43]

Biliary Leaks Associated with Liver Transplant

Biliary leaks that arise in the liver transplant patients are often the result of ischemia to the bile ducts. It is a common bile associated biliary leakage and intrahepatic biloma formation.[44,45] Biliary ischemia can result from acute or delayed thrombosis of the hepatic artery or postoperative stenosis between the donor and the recipient hepatic arteries.[45] Most liver transplants in the United States are performed using cadaveric donors, but transplantation with living related donors are also performed. Biliary leaks related to donor hepatectomy have an incidence of up to 9% and often arise along the hepatic resection margin, especially along the caudate lobe or hilar plate.[46–49]

Nonsurgical Causes of Biliary Leak

Transarterial Embolization

Nonsurgical etiologies of bilomas include injury from transarterial or transvenous interventions such as transarterial chemoembolization (TACE) or transarterial treatment of hepatic tumors with yttrium-90 (radioembolization).[50] TACE is the most commonly performed nonsurgical treatment for patients with unresectable hepatocellular carcinoma (HCC). Overall, it is a safe and effective procedure and is associated with low morbidity and mortality. Nevertheless, biliary-related complications can develop and have been reported as high as 8.6%.[51–53] Though biliary strictures are the most common biliary complications, few cases of bilomas have also been reported. Tu et al reported 2 cases of bilomas in a series of 1,120 patients with HCC who were treated with 2,860 transarterial embolization (TAE) or TACE procedures.[54] Both cases were managed by percutaneous drainage. Similarly, Dhamija et al reported two cases of intrahepatic biloma in 168 patients with

HCC who were treated with TACE.[55] Radioembolization is an emerging liver-directed therapy for selected patients with primary or metastatic liver disease. Biliary tract-related complications associated with radioembolization are similar to those described with TACE, and include biliary necrosis, acute cholecystitis, gallbladder necrosis, and strictures.[56,57]

Trauma

Injury to the biliary tree from abdominal trauma has a reported prevalence of up to 7%.[58,59] Biliary injuries are often seen in association with injuries to other abdominal organs, such as the spleen or duodenum.[60] Abdominal trauma in the form of motor vehicle accidents, penetrating injury, or falls, can lead to biloma formation.[59,61–63] In this setting, biliary tract injuries present on imaging as biliary ascites or loculated intra-abdominal fluid collection.[64] Large symptomatic bilomas may take several weeks from the initial trauma to manifest clinically as well as by imaging. Management is aimed at decompression to reduce mass effect or source control in cases where infection complicates the clinical scenario. Because management of hemodynamically stable patients is often conservative, biliary injuries often present as delayed complications.[65]

The gallbladder is more commonly involved in blunt trauma than the extra- and intrahepatic bile ducts. Gallbladder injuries are identified in up to 3% of patients who undergo emergent laparotomy in the setting of blunt abdominal trauma.[66] Because the gallbladder is somewhat protected by the liver and adjacent omentum, injuries are rare. Traumatic rupture or avulsions of the gallbladder are the most commonly reported injuries associated with blunt trauma.[67–69]

Injuries to the intrahepatic bile ducts are frequently the result of penetrating trauma and develop from lacerations to the intrahepatic biliary radicles. These types of injuries manifest by imaging as intrahepatic biliary collections.[59,70] Extrahepatic biliary injuries typically involve the common bile duct and often result from deceleration type of injuries.[71]

Ablation

Image-guided thermal ablation of hepatic tumors with radiofrequency waves (radiofrequency ablation [RFA]), microwave ablation (MWA), or by freezing (cryoablation) are commonly performed procedures for primary or metastatic liver tumors. All modalities aim to achieve tumor necrosis by exposing the tissue to extreme temperatures ($>$ 100°C with RFA or MWA, $-$40°C with cryoablation). Non–target-organ injury is a potential risk for any tumor undergoing thermal ablation. Biliary complications have been reported for all thermal ablation modalities and can take the form of biliary stricture or biloma[5,72–75] (►**Fig. 3**). Shankar et al described the development of an intrahepatic

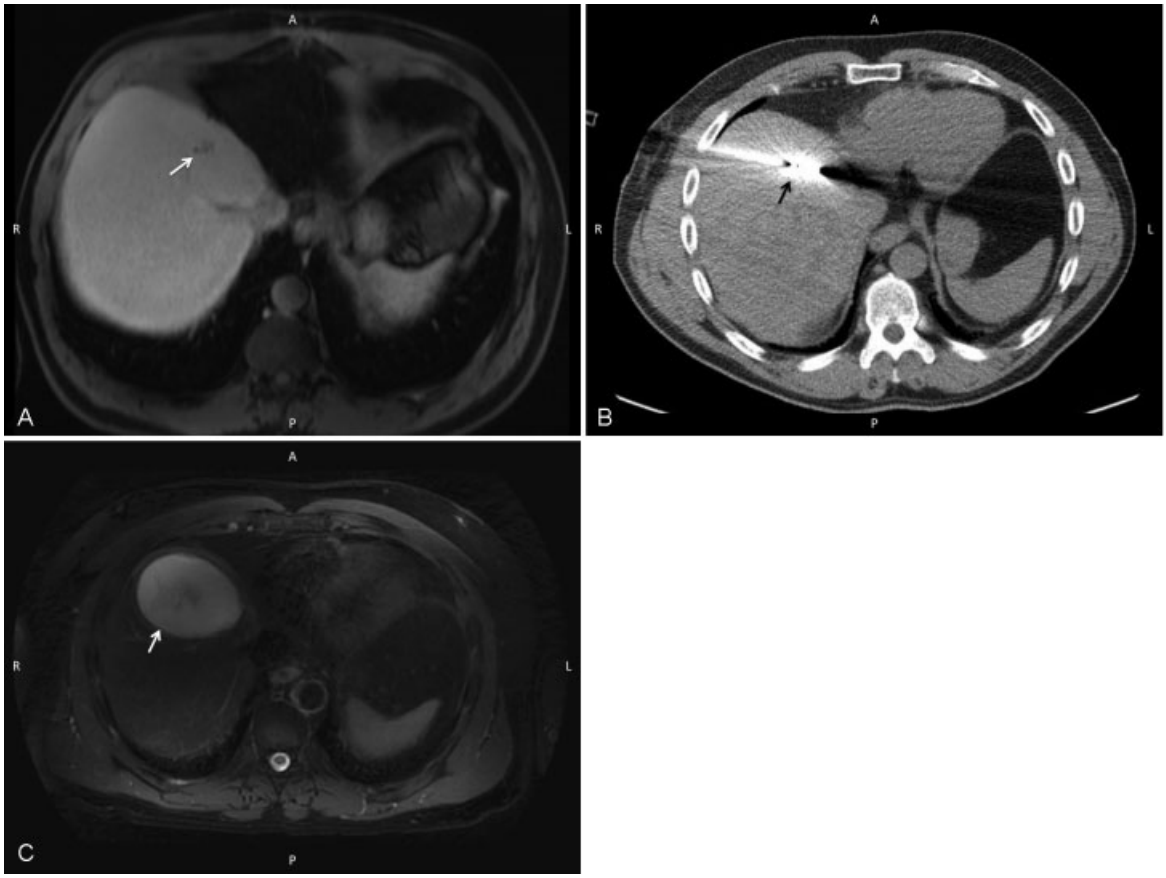

Fig. 3 (**A**) Axial gadolinium-enhanced T1-weighted image of the abdomen in a patient who is s/p left hepatectomy for metastatic colon cancer. White arrow indicates focal metastasis in the right hepatic lobe. (**B**) Axial unenhanced CT scan of the abdomen at the time of ablation. Black arrow indicates microwave antenna in the right hepatic lobe metastasis. (**C**) Axial T2-weighted image of the abdomen 1 month post microwave ablation for right hepatic lobe metastasis. White arrow indicates post-ablation biloma.

biloma following RFA of a gastrointestinal stromal tumor that was successfully treated by percutaneous drainage.[76] Chang et al retrospectively evaluated the post-RFA imaging studies of 2,630 patients with HCC and reported a 3.3% incidence of postablation bilomas.[5] A rare complication of bronchopleural fistula has been described following RFA of gastric cancer metastasis to the liver.

Diagnostic Imaging of Biliary Leaks and Bilomas

Cross-sectional imaging plays a vital role in the diagnosis of bile duct injuries. Computed tomography (CT), magnetic resonance imaging (MRI), ultrasound (US), as well as fluoroscopy, all contribute to the diagnosis and management of patients with biliary leaks.[3]

Magnetic Resonance Imaging

MRI combined with magnetic resonance cholangiography (MRCP) offers exquisite anatomical details of the intra- and extrahepatic bile ducts and can often pinpoint the location of leakage. The emergence of gadolinium-based hepatobiliary contrast agents offers dynamic evaluation of excretion of contrast as it passes through the biliary system. Gadolinium-based hepatobiliary contrast agents have been shown to be more accurate in localizing sites of biliary leak when compared with traditional T2-weighted imaging.[77,78] MRI with hepatobiliary contrast agents overall provides superior characterization of the bile ducts when compared with T2-weighted MRI. MRI findings of active biliary leak include accumulation of contrast material within the liver, in the perihepatic space, or distributed within the peritoneal cavity. Pecchi et al evaluated the role of MRCP in 78 liver transplant patients suspected of biliary complications and detected 44 biliary complications, including stricture, biliary sludge, stones, and biloma, 40 of which were confirmed by other imaging modalities.[79] The overall sensitivity, specificity positive predictive value (PPV), negative predictive value (NPV), and diagnostic accuracy of MRCP in their study was 93.5%, 94.4%, 96.7%, 89.5%, and 93.9%, respectively. Based on its tissue characterization abilities, MRI is also able to differentiate postoperative biloma from hematoma with high diagnostic accuracy.[80]

Computed Tomography

Multidetector computed tomography (MDCT) plays a vital role is assessing the bile ducts and surgical, traumatic, or intervention-related biliary complications.[12,81–86] In the setting of trauma, bile duct injuries may be subtle and not readily detected or may manifest several days to weeks after initial injury. Early manifestations of biliary leakage may be nonspecific findings of trace ascites. When biliary injury is suspected, serial imaging is helpful to evaluate the evolution of perihepatic fluid collections. Persistent or increasing intraperitoneal fluid, loculated low-attenuation perihepatic or intrahepatic fluid, or peritoneal thickening and enhancement all suggest biliary ascites, bilomas, or bile peritonitis.[86,87]

MDCT is also valuable in evaluation of post–liver transplant patients suspected of having biliary abnormalities. Boraschi et al evaluated 170 post–liver transplant patients with MDCT who were suspected of having biliary abnormalities based on clinical/laboratory findings or US examination. All patients were evaluated within 90 days of transplantation, and the results found that MDCT readily detected vascular, biliary, and parenchymal abnormalities with up to 97% sensitivity.[81] Similarly, Meng et al found MDCT to be 100% specific and accurate in detecting anastomotic biliary leak and bilomas in postoperative liver transplant patients.[88] MDCT also plays a critical role in evaluation of blunt abdominal trauma in children and adults.

Hepatobiliary Scintigraphy

Physiologic evaluation of the biliary excretion is the main advantage of hepatobiliary scintigraphy. Biliary leaks are characterized as progressive accumulation of radiotracer in a nonanatomic location outside of the biliary tree.[89] Though effective at detecting biliary leaks, hepatobiliary scintigraphy is limited in its ability to provide anatomic and spatial information that is necessary to localize the site of biliary leakage.

Management of Biliary Leaks and Bilomas

Bilious fluid collections within the abdomen can be drained percutaneously using a variety of imaging modalities and techniques.[90–93] The most straightforward management option is percutaneous catheter drainage of localized fluid collections within the abdomen. Drainage can be accomplished using either Seldinger or trocar techniques, depending upon the size and locations of the collections. Superficial or perihepatic collections are easily targeted using US guidance, which has the benefit of real-time imaging and lack of ionizing radiation. Drainage of subhepatic collections poses unique challenges because of the proximity of the fluid collections to the adjacent diaphragm and lung. Transpleural approaches, while effective at draining the subhepatic collection, may lead to the development of a pleural effusion or empyema following the drainage of sterile or infected bilomas. The combined use of US and fluoroscopy may help avoid these potential complications while achieving effective drainage (►**Fig. 4**). As described previously, biliary leaks from small peripheral ducts (i.e., ducts of Luschka) are often effectively resolved using a combination of percutaneous drainage of the localized collection and endoscopic stent drainage of percutaneous transhepatic drainage. The goal of therapy is to divert the flow of bile away from the site of leakage.[37,94]

Intrahepatic bilomas are treated with percutaneous drainage using either US or CT guidance.

U-tube drainage is a technique that has been described to manage intrahepatic bilomas in the setting of complete transection of the common duct. Conceptually, the procedure involves placing a percutaneous drainage catheter into the biloma through one skin entry site, establishing communication with the biliary tree, and then externalizing the

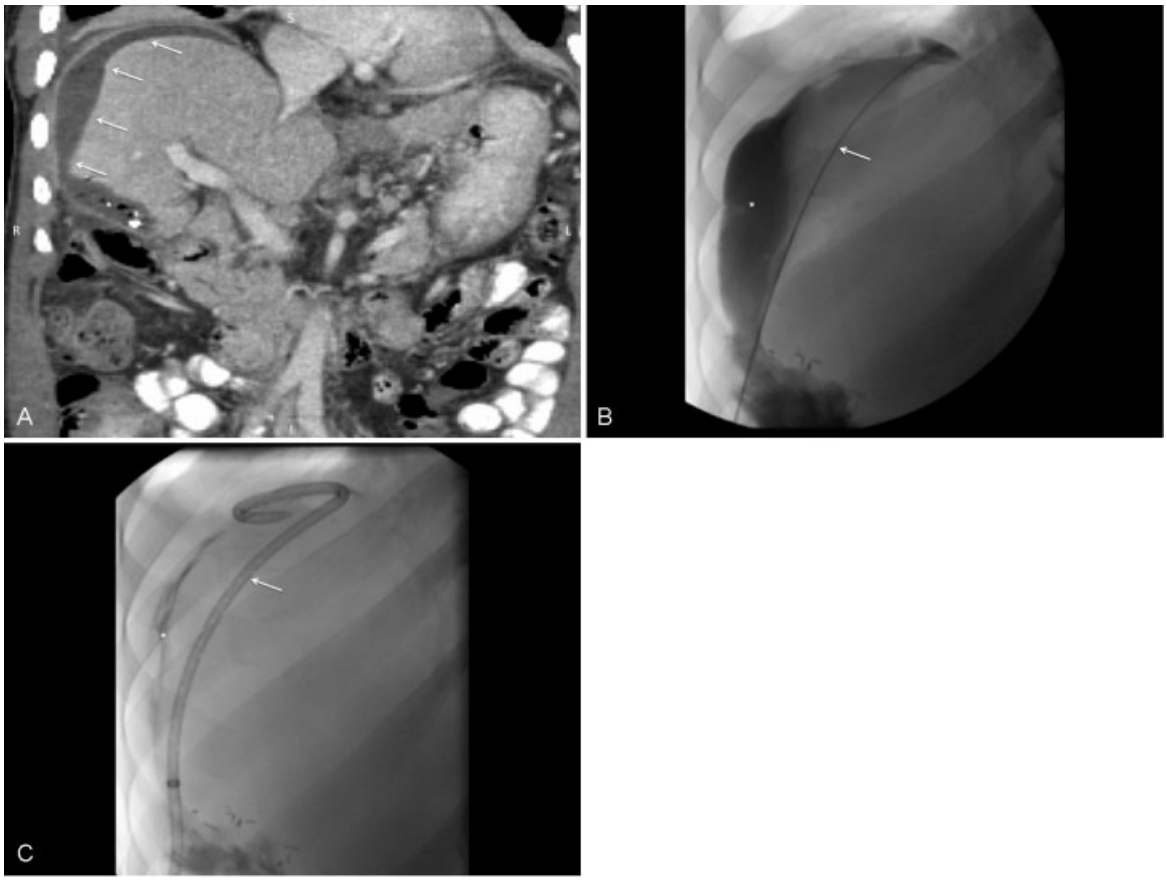

Fig. 4 (A) Coronal contrast material-enhanced CT scan of the abdomen in a patient who is s/p laparoscopic cholecystectomy. White arrows indicate a postsurgical biloma that extends from the gallbladder fossa (white asterisk) to the right subhepatic space (white arrows). (B) Fluoroscopic image of patient in ►**Fig. 4A** that demonstrates contrast (white asterisk) and percutaneously placed guidewire into right subphrenic biloma. (C) Fluoroscopic image of patient in ►**Fig. 4A** that demonstrates a small amount of residual contrast (white asterisk) and percutaneously placed drainage catheter into the right subphrenic biloma.

catheter tip through a second puncture site.[37] This method serves the dual purpose of decompression of the biloma while offering more secure catheter placement with less risk of catheter dislodgement.[94,95]

Conclusion

Biliary leaks and bilomas are infrequent but clinically challenging consequences of iatrogenic or traumatic injury. They can manifest as intra- or extrahepatic abdominal fluid collections, and optimal management requires a multidisciplinary approach between the diagnostic radiologist, interventional radiologist, surgeon, and endoscopists. Cross-sectional imaging is crucial in establishing the diagnosis and site of leakage. A variety of endoscopic and percutaneous techniques are available to facilitate management and resolution of bilomas and biliary leaks.

References

1 Cervantes J, Rojas GA, Ponte R. Intrahepatic subcapsular biloma. A rare complication of laparoscopic cholecystectomy. Surg Endosc 1994;8(3):208–210
2 Gould L, Patel A. Ultrasound detection of extrahepatic encapsulated bile: "biloma". AJR Am J Roentgenol 1979;132(6):1014–1015
3 Copelan A, Bahoura L, Tardy F, Kirsch M, Sokhandon F, Kapoor B. Etiology, diagnosis, and management of bilomas: a current update. Tech Vasc Interv Radiol 2015;18(4):236–243
4 Braithwaite BM, Cabanilla LT, Lilly M. Hepatic subcapsular biloma: a rare complication of laparoscopic cholecystectomy and common bile duct exploration. Curr Surg 2003;60(2):196–198
5 Chang IS, Rhim H, Kim SH, et al. Biloma formation after radiofrequency ablation of hepatocellular carcinoma: incidence, imaging features, and clinical significance. AJR Am J Roentgenol 2010; 195(5):1131–1136
6 Safdar N, Said A, Lucey MR, et al. Infected bilomas in liver transplant recipients: clinical features, optimal management, and risk factors for mortality. Clin Infect Dis 2004;39(4):517–525
7 Hoffer FA, Teele RL, Lillehei CW, Vacanti JP. Infected bilomas and hepatic artery thrombosis in infant recipients of liver transplants. Interventional radiology and medical therapy as an alternative to retransplantation. Radiology 1988;169(2):435–438
8 Dimick JB, Wainess RM, Cowan JA, Upchurch GR Jr, Knol JA, Colletti LM. National trends in the use and outcomes of hepatic resection. J Am Coll Surg 2004;199(1):31–38
9 Capussotti L, Ferrero A, Viganò L, Sgotto E, Muratore A, Polastri R. Bile leakage and liver resection: where is the risk? Arch Surg 2006;141(7):690–694, discussion 695
10 Viganò L, Ferrero A, Sgotto E, Tesoriere RL, Calgaro M, Capussotti L. Bile leak after hepatectomy: predictive factors of spontaneous healing. Am J Surg 2008;196(2):195–200

11 Antonopoulos C, Voulimeneas I, Ioannides P, Kotsifas T, Kavallieratos N, Vagianos C. Bile leaks after cholecystectomy: the significance of patient selection. Surg Laparosc Endosc Percutan Tech 2009;19(5):379–383
12 Ametani F, Itoh K, Shibata T, Maetani Y, Tanaka K, Konishi J. Spectrum of CT findings in pediatric patients after partial liver transplantation. Radiographics 2001;21(1):53–63
13 Barabino M, Gatti A, Santambrogio R, et al. Biliary fistula after liver resection: central role of intraoperative perihepatic drain. Minerva Chir 2016;71(6):353–359
14 Tanaka S, Hirohashi K, Tanaka H, et al. Incidence and management of bile leakage after hepatic resection for malignant hepatic tumors. J Am Coll Surg 2002;195(4):484–489
15 Imamura H, Seyama Y, Kokudo N, et al. One thousand fifty-six hepatectomies without mortality in 8 years. Arch Surg 2003; 138(11):1198–1206, discussion 1206
16 Clarke DL, Currie EJ, Madhavan KK, Parks RW, Garden OJ. Hepatic resection for benign non-cystic liver lesions. HPB (Oxford) 2004; 6(2):115–119
17 Erdogan D, Busch OR, Gouma DJ, van Gulik TM. Morbidity and mortality after liver resection for benign and malignant hepatobiliary lesions. Liver Int 2009;29(2):175–180
18 Geller DA, Tsung A, Maheshwari V, Rutstein LA, Fung JJ, Marsh JW. Hepatic resection in 170 patients using saline-cooled radiofrequency coagulation. HPB (Oxford) 2005;7(3):208–213
19 Delis S, Bakoyiannis A, Tassopoulos N, et al. Clamp-crush technique vs. radiofrequency-assisted liver resection for primary and metastatic liver neoplasms. HPB (Oxford) 2009;11(4):339–344
20 Saiura A, Yamamoto J, Koga R, Seki M, Yamaguchi T. Liver transection using the LigaSure sealing system. HPB (Oxford) 2008;10(4):239–243
21 Castaldo ET, Earl TM, Chari RS, et al. A clinical comparative analysis of crush/clamp, stapler, and dissecting sealer hepatic transection methods. HPB (Oxford) 2008;10(5):321–326
22 Yamashita Y, Hamatsu T, Rikimaru T, et al. Bile leakage after hepatic resection. Ann Surg 2001;233(1):45–50
23 Lo CM, Fan ST, Liu CL, Lai EC, Wong J. Biliary complications after hepatic resection: risk factors, management, and outcome. Arch Surg 1998;133(2):156–161
24 Jarnagin WR, Gonen M, Fong Y, et al. Improvement in perioperative outcome after hepatic resection: analysis of 1,803 consecutive cases over the past decade. Ann Surg 2002;236(4):397–406, discussion 406–407
25 Lee JG, Choi SB, Kim KS, Choi JS, Lee WJ, Kim BR. Central bisectionectomy for centrally located hepatocellular carcinoma. Br J Surg 2008;95(8):990–995
26 McMahon AJ, Russell IT, Baxter JN, et al. Laparoscopic versus minilaparotomy cholecystectomy: a randomised trial. Lancet 1994;343(8890):135–138
27 McMahon AJ, Russell IT, Ramsay G, et al. Laparoscopic and minilaparotomy cholecystectomy: a randomized trial comparing postoperative pain and pulmonary function. Surgery 1994; 115(5):533–539
28 Gouma DJ, Rauws EA, Keulemans YC, Bergman JJ, Huibregtse K, Obertop H. [Bile duct injuries after a laparoscopic cholecystectomy] [in Dutch]. Ned Tijdschr Geneeskd 1999;143(12):606–611
29 Deziel DJ, Millikan KW, Economou SG, Doolas A, Ko ST, Airan MC. Complications of laparoscopic cholecystectomy: a national survey of 4,292 hospitals and an analysis of 77,604 cases. Am J Surg 1993;165(1):9–14
30 Deziel DJ. Complications of cholecystectomy. Incidence, clinical manifestations, and diagnosis. Surg Clin North Am 1994;74(4): 809–823
31 Nagano Y, Togo S, Tanaka K, et al. Risk factors and management of bile leakage after hepatic resection. World J Surg 2003;27(6): 695–698
32 Neumann H, Fry LC, Malfertheiner P, Mönkemüller K. Bile leak from the duct of Luschka. Z Gastroenterol 2010;48(2):256–257
33 Stathopoulos V, Georganas M, Stratakis K, Delaporta E, Karallas E, Koutsopoulos K. Hepatic subcapsular biloma: a rare complication of laparoscopic cholecystectomy. Case Rep Surg 2014;2014:186819
34 Choi KM, Jang HJ, Kwak JH, Kim JH, Ahn JH. Management of postoperative bilomas and biliary injuries associated with laparoscopic cholecystectomy with intrabiliary ethanol ablation and microcoil embolization. Hepatogastroenterology 2014;61(129):27–30
35 Pinkas H, Brady PG. Biliary leaks after laparoscopic cholecystectomy: time to stent or time to drain. Hepatobiliary Pancreat Dis Int 2008;7(6):628–632
36 Rossi M, Salvatori FM, Giglio L, et al. Interventional radiology techniques in the treatment of complications due to videolaparoscopic cholecystectomy. Radiol Med (Torino) 2002;103(4): 384–395
37 Thompson CM, Saad NE, Quazi RR, Darcy MD, Picus DD, Menias CO. Management of iatrogenic bile duct injuries: role of the interventional radiologist. Radiographics 2013;33(1):117–134
38 Shin S, Klevan A, Fernandez CA, Astudillo JA, Martinez J. Rendezvous technique for the treatment of complete common bile duct transection after multiple hepatobiliary surgeries. J Laparoendosc Adv Surg Tech A 2014;24(10):728–730
39 Lo Nigro C, Geraci G, Sciuto A, Li Volsi F, Sciume C, Modica G. Bile leaks after videolaparoscopic cholecystectomy: duct of Luschka. Endoscopic treatment in a single centre and brief literature review on current management. Ann Ital Chir 2012;83(4):303–312
40 Kyokane T, Nagino M, Oda K, Nimura Y. An experimental study of selective intrahepatic biliary ablation with ethanol. J Surg Res 2001;96(2):188–196
41 Kyokane T, Nagino M, Sano T, Nimura Y. Ethanol ablation for segmental bile duct leakage after hepatobiliary resection. Surgery 2002;131(1):111–113
42 Hai S, Tanaka H, Takemura S, Sakabe K, Ichikawa T, Kubo S. Portal vein embolization for an intractable bile leakage after hepatectomy. Clin J Gastroenterol 2012;5(4):287–291
43 Yamakado K, Nakatsuka A, Iwata M, et al. Refractory biliary leak from intrahepatic biliary-enteric anastomosis treated by selective portal vein embolization. J Vasc Interv Radiol 2002;13(12): 1279–1281
44 Albishri SH, Issa S, Kneteman NM, Shapiro AM. Bile leak from duct of Luschka after liver transplantation. Transplantation 2001; 72(2):338–340
45 Zhu KS, Meng XC, Huang MS, et al. [The role of early hepatic artery ischemia on biliary complications after liver transplantation and hepatic arterial interventional therapy] [in Chinese]. Zhonghua Yi Xue Za Zhi 2009;89(31):2195–2198
46 Chan SC, Fan ST, Lo CM, Liu CL, Wong J. Toward current standards of donor right hepatectomy for adult-to-adult live donor liver transplantation through the experience of 200 cases. Ann Surg 2007;245(1):110–117
47 Chan SC, Fan ST, Lo CM, et al. A decade of right liver adult-to-adult living donor liver transplantation: the recipient mid-term outcomes. Ann Surg 2008;248(3):411–419
48 Liu CL, Fan ST, Lo CM, et al. Operative outcomes of adult-to-adult right lobe live donor liver transplantation: a comparative study with cadaveric whole-graft liver transplantation in a single center. Ann Surg 2006;243(3):404–410
49 Ghobrial RM, Freise CE, Trotter JF, et al; A2ALL Study GroupDonor morbidity after living donation for liver transplantation. Gastroenterology 2008;135(2):468–476
50 Sakamoto I, Iwanaga S, Nagaoki K, et al. Intrahepatic biloma formation (bile duct necrosis) after transcatheter arterial chemoembolization. AJR Am J Roentgenol 2003;181(1):79–87
51 Zhaolin Z, Xuelian L, Wensou H, et al. [Clinical features and risk factors of biloma formation after transcatheter arterial chemoembolization] [in Chinese]. Zhonghua Yi Xue Za Zhi 2015;95(13): 1002–1005
52 Miyayama S, Yamashiro M, Okuda M, et al. Main bile duct stricture occurring after transcatheter arterial chemoembolization for

hepatocellular carcinoma. Cardiovasc Intervent Radiol 2010; 33(6):1168–1179
53 Wang Z, Wang M, Duan F, Song P, Liu F. Bile duct injury after transcatheter arterial chemoembolization: risk factors and clinical implications. Hepatogastroenterology 2014;61(132):947–953
54 Tu J, Jia Z, Ying X, et al. The incidence and outcome of major complication following conventional TAE/TACE for hepatocellular carcinoma. Medicine (Baltimore) 2016;95(49):e5606
55 Dhamija E, Paul SB, Gamanagatti SR, Acharya SK. Biliary complications of arterial chemoembolization of hepatocellular carcinoma. Diagn Interv Imaging 2015;96(11):1169–1175
56 Atassi B, Bangash AK, Lewandowski RJ, et al. Biliary sequelae following radioembolization with yttrium-90 microspheres. J Vasc Interv Radiol 2008;19(5):691–697
57 Minocha J, Lewandowski RJ. Radioembolization for hepatocellular carcinoma complicated by biliary stricture. Semin Intervent Radiol 2011;28(2):226–229
58 Kozar RA, Moore JB, Niles SE, et al. Complications of nonoperative management of high-grade blunt hepatic injuries. J Trauma 2005; 59(5):1066–1071
59 Bala M, Gazalla SA, Faroja M, et al. Complications of high grade liver injuries: management and outcome with focus on bile leaks. Scand J Trauma Resusc Emerg Med 2012;20:20
60 Chen X, Talner LB, Jurkovich GJ. Gallbladder avulsion due to blunt trauma. AJR Am J Roentgenol 2001;177(4):822
61 Gander R, Molino JA, Santiago S, et al. [Conservative management of liver trauma and its complications: current gold-standard] [in Spanish]. Cir Pediatr 2016;29(1):19–24
62 Al-Hassani A, Jabbour G, El-Labib M, Kanbar A, El-Menyar A. Al-Thani H. Delayed bile leak in a patient with grade IV blunt liver trauma: a case report and review of the literature. Int J Surg Case Rep 2015;14:156–159
63 Howard R, Bansal S, Munshi IA. Biloma: a delayed complication of blunt hepatic injury. J Emerg Med 2008;34(1):33–35
64 Fleming KW, Lucey BC, Soto JA, Oates ME. Posttraumatic bile leaks: role of diagnostic imaging and impact on patient outcome. Emerg Radiol 2006;12(3):103–107
65 Wahl WL, Brandt MM, Hemmila MR, Arbabi S. Diagnosis and management of bile leaks after blunt liver injury. Surgery 2005; 138(4):742–747, discussion 747–748
66 Wittenberg A, Minotti AJ. CT diagnosis of traumatic gallbladder injury. AJR Am J Roentgenol 2005;185(6):1573–1574
67 Brennan PM, Welsh FK, Lyness C, Bathgate AJ, Wigmore S J. Avulsion of the gallbladder following trivial injury. Int J Clin Pract 2004;58(3):318–321
68 Ameh EA, Mai A, Adams LM, Dogo PM, Esangbedo AE, Nmadu PT. Blunt traumatic injury of the gallbladder in childhood. Cent Afr J Med 1997;43(9):272–273
69 Losanoff JE, Kjossev KT. Complete traumatic avulsion of the gallbladder. Injury 1999;30(5):365–368
70 Feliciano DV. Biliary injuries as a result of blunt and penetrating trauma. Surg Clin North Am 1994;74(4):897–907, discussion 909–912
71 Gupta A, Stuhlfaut JW, Fleming KW, Lucey BC, Soto JA. Blunt trauma of the pancreas and biliary tract: a multimodality imaging approach to diagnosis. Radiographics 2004;24(5):1381–1395
72 Kim SH, Lim HK, Choi D, et al. Changes in bile ducts after radiofrequency ablation of hepatocellular carcinoma: frequency and clinical significance. AJR Am J Roentgenol 2004;183(6):1611–1617
73 Song I, Rhim H, Lim HK, Kim YS, Choi D. Percutaneous radiofrequency ablation of hepatocellular carcinoma abutting the diaphragm and gastrointestinal tracts with the use of artificial ascites: safety and technical efficacy in 143 patients. Eur Radiol 2009;19(11):2630–2640
74 Chiou YY, Hwang JI, Chou YH, Wang HK, Chiang JH, Chang CY. Percutaneous ultrasound-guided radiofrequency ablation of intrahepatic cholangiocarcinoma. Kaohsiung J Med Sci 2005; 21(7):304–309
75 Akahane M, Koga H, Kato N, et al. Complications of percutaneous radiofrequency ablation for hepato-cellular carcinoma: imaging spectrum and management. Radiographics 2005;25(Suppl 1): S57–S68
76 Shankar S, van Sonnenberg E, Silverman SG, Tuncali K, Morrison PR. Diagnosis and treatment of intrahepatic biloma complicating radiofrequency ablation of hepatic metastases. AJR Am J Roentgenol 2003;181(2):475–477
77 Ogul H, Kantarci M, Pirimoglu B, et al. The efficiency of Gd-EOB-DTPA-enhanced magnetic resonance cholangiography in living donor liver transplantation: a preliminary study. Clin Transplant 2014;28(3):354–360
78 Kantarcı M, Pirimoglu B, Karabulut N, et al. Non-invasive detection of biliary leaks using Gd-EOB-DTPA-enhanced MR cholangiography: comparison with T2-weighted MR cholangiography. Eur Radiol 2013;23(10):2713–2722
79 Pecchi A, DeSantis M, DiBenedetto FK, Gibertini M. Role of magnetic resonance cholangiography in biliary complications of orthotopic liver transplantation. Radiol Med 2010;115(7):1065–1079
80 Shigemura T, Yamamoto F, Shilpakar SK, Kojima T, Yamamoto S, Pu Y. MRI differential diagnosis of intrahepatic biloma from subacute hematoma. Abdom Imaging 1995;20(3):211–213
81 Boraschi P, Donati F, Rossi M, Ghinolfi D, Filipponi F, Falaschi F. Role of MDCT in the detection of early abdominal complications after orthotopic liver transplantation. Clin Imaging 2016;40(6):1200–1206
82 Patel NB, Oto A, Thomas S. Multidetector CT of emergent biliary pathologic conditions. Radiographics 2013;33(7):1867–1888
83 Bismpa K, Zlika S, Fouzas I, Imvrios G, Papanikolaou V, Petridis A. Imaging of complications of liver transplantation: multidetector computed tomography findings. Transplant Proc 2012;44(9): 2751–2753
84 Nikpour AM, Knebel RJ, Cheng D. Diagnosis and management of postoperative biliary leaks. Semin Intervent Radiol 2016;33(4): 307–312
85 Tsai MJ, Chen JD, Tiu CM, Chou YH, Hu SC, Chang CY. Can acute cholecystitis with gallbladder perforation be detected preoperatively by computed tomography in ED? Correlation with clinical data and computed tomography features. Am J Emerg Med 2009; 27(5):574–581
86 Yoon W, Jeong YY, Kim JK, et al. CT in blunt liver trauma. Radiographics 2005;25(1):87–104
87 Franklin GA, Richardson JD, Brown AL, et al. Prevention of bile peritonitis by laparoscopic evacuation and lavage after nonoperative treatment of liver injuries. Am Surg 2007;73(6):611–616, discussion 616–617
88 Meng XC, Huang WS, Xie PY, et al. Role of multi-detector computed tomography for biliary complications after liver transplantation. World J Gastroenterol 2014;20(33):11856–11864
89 Singh AK, Nachiappan AC, Verma HA, et al. Postoperative imaging in liver transplantation: what radiologists should know. Radiographics 2010;30(2):339–351
90 Nuñez D Jr, Becerra JL, Martin LC. Subhepatic collections complicating laparoscopic cholecystectomy: percutaneous management. Abdom Imaging 1994;19(3):248–250
91 Sammak BM, Yousef BA, Gali MH, al Karawi MA, Mohamed AE. Case report: radiological and endoscopic management of bile leak following laparoscopic cholecystectomy. J Gastroenterol Hepatol 1997;12(1):34–38
92 Oliva VL, Nicolet V, Soulez G, et al. Bilomas developing after laparoscopic biliary surgery: percutaneous management with embolization of biliary leaks. J Vasc Interv Radiol 1997;8(3):469–473
93 Stampfl U, Hackert T, Radeleff B, et al. Percutaneous management of postoperative bile leaks after upper gastrointestinal surgery. Cardiovasc Intervent Radiol 2011;34(4):808–815
94 Saad N, Darcy M. Iatrogenic bile duct injury during laparoscopic cholecystectomy. Tech Vasc Interv Radiol 2008;11(2):102–110
95 Covey AM, Brown KT. Percutaneous transhepatic biliary drainage. Tech Vasc Interv Radiol 2008;11(1):14–20