

Gastric Rupture in Pregnancy: Case Series from a Tertiary Institution in Rwanda and Review of the Literature

David Ntirushwa, MD^{1,2} Stephen Rulisa, MD, PhD¹ Febronie Muhorakeye, MD¹
Lisa Bazzett-Matabele, MD^{1,2,5} Theogene Rurangwa, MD³ Maria Small, MD^{1,4,5}

¹Department of Obstetrics and Gynecology, University of Rwanda, Rwanda

²Department of Obstetrics and Gynecology, University Teaching Hospital of Kigali, Kigali, Rwanda

³Rwanda Military Hospital, Kigali, Rwanda

⁴Department of Obstetrics and Gynecology, Duke University, Durham, North Carolina

⁵Department of Obstetrics and Gynecology, Yale University, New Haven, Connecticut

Address for correspondence Stephen Rulisa, MD, PhD, Department of Obstetrics and Gynecology, University of Rwanda, BP 655, Kigali, Rwanda (e-mail: srulisa@gmail.com).

Am J Perinatol Rep 2016;6:e436–e441.

Abstract

Background Gastric rupture is a rare, life-threatening condition during pregnancy.
Case study We present three cases of gastric perforation during pregnancy and the puerperium. The first patient presented with gastric perforation 4 days following an uncomplicated cesarean delivery for obstetric indications. She initially complained of epigastric pain; however, those symptoms resolved. She later demonstrated worsening abdominal distension, intra-abdominal free fluid, and signs of peritonitis. At laparotomy, an ascariasis-associated gastric rupture was diagnosed. She died from sepsis 4 days following the laparotomy. The second patient presented 19 days following a normal vaginal delivery. She presented with hemodynamic instability and underwent emergent laparotomy due to suspected septic shock peritonitis. Gastric rupture was diagnosed intraoperatively. She improved clinically and was discharged home. The third patient underwent emergency cesarean delivery due to non-reassuring fetal status in the setting of preeclampsia. She was initially diagnosed with ascites and pulmonary edema as a result of preeclampsia. Later in her course, she developed features in favor of acute abdomen and signs of sepsis. At the time of emergent laparotomy, a gastric rupture was identified and repaired. She died 2 days later from sepsis.
Conclusion We report the management and outcome of three cases of pregnancy-related gastric rupture. To our knowledge, these three cases represent the largest series of pregnancy-related gastric ruptures from a single institution.

Keywords

- ▶ gastric rupture
- ▶ pregnancy
- ▶ Rwanda
- ▶ sepsis
- ▶ ascariasis

Gastric rupture during pregnancy is very rare and the few identified case reports in the literature are primarily associated with either bariatric surgery or undiagnosed diaphragmatic hernias.^{1–4} Early identification of the condition is

essential because diagnostic delay increases maternal and perinatal morbidity and mortality.⁵

We performed a PubMed literature search of English language articles from 1900 to 2015 using key words: “gastric

received
October 23, 2016
accepted after revision
November 11, 2016

DOI <http://dx.doi.org/10.1055/s-0036-1597619>.
ISSN 2157-6998.

Copyright © 2016 by Thieme Medical Publishers, Inc., 333 Seventh Avenue, New York, NY 10001, USA.
Tel: +1(212) 584-4662.

License terms



rupture,” “stomach rupture,” and “pregnancy.” The same search terms were entered in Google Scholar. We also examined the cited references for any additional cases. Nine case reports described gastric ruptures during pregnancy.

The few cases of spontaneous gastric rupture reported in the literature are typically complicated by previously undiagnosed congenital anomalies, gastric carcinoma, or ascariasis.

We present three cases of gastric rupture during pregnancy and managed at the University Teaching Hospital of Kigali (CHUK). CHUK is the largest public hospital in Rwanda and serves as one of the primary teaching and tertiary care referral centers for the country. CHUK receives referrals from 29 district hospitals.

Case Presentations

Case 1

An 18-year-old primiparous patient was transferred to CHUK from the district hospital due to progressive abdominal distension 4 days following an uncomplicated cesarean delivery. The patient had a medical history of epigastric pain, unresponsive to medical treatment with cimetidine. Postoperatively, she experienced fever, abdominal pain, and distension. Endometritis and ileus were suspected. She was treated with ampicillin, gentamycin, and metronidazole, and a nasogastric tube was placed. The patient was transferred to the tertiary care hospital CHUK for further management.

On arrival at CHUK, her Glasgow coma score was 15/15. Her blood pressure was 100/70 mm Hg, pulse 165 beats/min, and temperature was 37.5°C. Her abdomen was noted to be distended and diffusely tender. No rebound or guarding was noted.

Abdominal ultrasound demonstrated a moderate amount of free fluid in the abdomen. The initial impression was hemoperitoneum, possible peritonitis. The patient was aggressively resuscitated with intravenous fluids. The antibiotic regimen was changed to ceftriaxone and metronidazole on admission. The nasogastric tube was maintained. The white blood count was $3.2 \times 10^3/\text{mm}^3$; hemoglobin 16 g/dL, and platelet count $218 \times 10^3/\text{mm}^3$. After review of the laboratory values and confirming that the patient was hemodynamically stable, hemoperitoneum was ruled out.

On hospital day 1, she was clinically improved with reduced abdominal pain and tenderness on examination; however, she was febrile with a temperature of 38.5°C. She reported no flatus or stool.

Abdominal X-ray demonstrated distended bowels without air fluid levels.

She improved clinically on hospital day 2 and tolerated an advance to regular diet. She was afebrile and noted to have flatus and passage of stool.

She acutely decompensated 48 hours after admission. She became febrile, tachycardic, dyspneic, hypoxic, and abdominal distension markedly increased. Bedside ultrasound confirmed increased free fluid. Providers suspected sepsis due to worsening peritonitis. Emergent laparotomy was performed. Intraoperatively, five ascaris worms measuring approximately 20 cm each were found in the peritoneal cavity. A mass of

intestinal worms was palpable in the intestines. Feculent peritoneal fluid was aspirated.

A 3×3 cm perforation in the lesser curvature of the stomach was diagnosed and repaired.

Despite resuscitation efforts, the patient died of septic shock 4 hours following surgery.

Case 2

A 35-year-old gravida 6, para 4 patient was transferred from a district hospital 19 days following a normal vaginal delivery. She reported feeling well until about 3 days prior to admission when she developed progressive abdominal pain and distension. Peritonitis was suspected and the patient was transferred to CHUK for further management.

On admission, she was febrile with temperature of 39.4°C, tachycardic (150 beats/min), hypotensive (nonmeasurable blood pressure), and pale. The abdomen was distended and tender on palpation, but no rebound or guarding was noted. The remainder of the physical examination was unremarkable. Available laboratories demonstrated hemoglobin of 8.8 g/dL and platelet count of $154 \times 10^3/\text{mm}^3$. Ultrasound revealed elevated free fluid in the abdominal cavity. Resuscitation was initiated with blood, intravenous fluids, and broad-spectrum antibiotics (cefotaxime and metronidazole). The working diagnosis was sepsis in the setting of generalized peritonitis. Emergent laparotomy was performed after maternal stabilization. Intraoperatively, 3 L of foul-smelling pus was aspirated. Further exploration revealed a posterior gastric perforation measuring 1 to 2 cm was diagnosed and repaired. There was no obvious underlying cause for the perforation. In addition, the patient had no documented history of peptic ulcer disease (PUD), but clinically ulcer disease was suspected as the possible cause of perforation.

The postoperative course was uneventful and the patient was discharged home in stable condition.

Case 3

A 34-year-old primiparous patient transferred to CHUK from a district hospital due to suspected pulmonary edema 1 day following cesarean delivery for non-reassuring fetal status in the setting of preeclampsia. The neonate died on the day of delivery. The patient reported a history of epigastric pain prior to her cesarean delivery. She denied nausea or vomiting. She received 80 mg of Lasix at the district hospital prior to transfer. At CHUK, the patient was dyspneic, tachypneic with an oxygen saturation of 88% on room air. Her blood pressure was 138/89 mm Hg, pulse 117 beats/min, and respiratory rate 30 breaths/min. The physical examination was significant for marked facial and lower extremity edema, but the lungs were described as “clear” by the admitting physician. The cardiac examination was significant for tachycardia. The abdomen was markedly distended and diffusely tender. No rebound or guarding was noted. Abdominal ultrasound demonstrated a large amount of free fluid in the abdominal cavity. The working diagnosis was pulmonary edema and abdominal ascites in the setting of severe preeclampsia. The differential diagnoses also included pulmonary embolus and hemoperitoneum. The patient was given 5 L of oxygen per minute and

placed on therapeutic enoxaparin. On admission the white blood (cell) count (WBC) was $6.2 \times 10^3/\text{mm}^3$, hemoglobin 9.1 g/dL, and platelet count $59 \times 10^3/\text{mm}^3$. A chemistry panel was requested but not available at the time of admission. Antibiotics were not initiated at the time of admission. Hospital day 2, the patient was noted to have minimal clinical improvement. She remained afebrile and a repeat WBC was $3.7 \times 10^3/\text{mm}^3$. Ceftriaxone and metronidazole were initiated; however, the site of infection was not clear. She did not show signs of acute abdomen. Lovenox was discontinued. The abdominal free fluid progressively increased and peritoneocentesis was performed. The peritoneocentesis demonstrated blood tinged ascitic fluid. Additional studies included Gram stain/culture and cytology; however, these results were not immediately available to providers.

The patient's clinical status improved slightly. She was eating, ambulating without difficulty and did not have nausea/vomiting. Her WBC, however, progressively increased despite antibiotic therapy. The results of the initial paracentesis demonstrated WBC $100/\text{mm}^3$, red blood (cell) count (RBC) $2,000/\text{mm}^3$, and polymorphonuclear (PMN) 100%.

On hospital day 11, the patient was noted to be hypothermic with a temperature of 35°C , pulse 122 beats/min, respiratory rate 40 breaths/min, and blood pressure of 128/68 mm Hg. The paracentesis was repeated and frank pus was aspirated. Emergent laparotomy was performed due to suspected peritonitis.

Intraoperatively, undigested food particles were noted. Three liters of inflammatory, foul-smelling ascitic fluid was aspirated. A 1.5×1 cm anterior gastric perforation was noted (→ Fig. 1). The perforation was repaired in two layers.

Antibiotics were continued and nasogastric tube placed. The patient improved clinically on postoperative day 1. However, on postoperative day 2, she developed respiratory distress and an acute abdomen. She was taken back to the

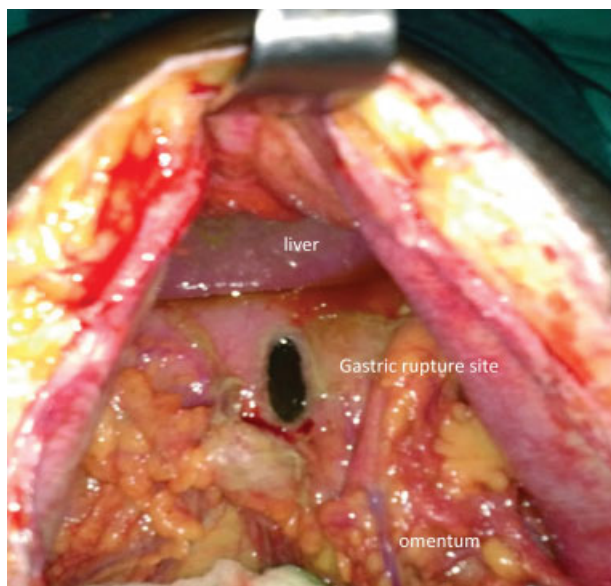


Fig. 1 Intraoperative image (case 3) demonstrating gastric rupture site in postpartum patient.

operating room for exploratory laparotomy due to suspected leakage of the gastric repair site.

At the time of the second laparotomy, the gastric repair was intact and 1.5 L of inflammatory fluid was aspirated. No other pathologic findings were noted.

Postoperatively she remained intubated, on antibiotics, and with a nasogastric tube in place. Because of to lack of intensive care unit (ICU) beds, she was transferred to another tertiary care center ICU. She died from sepsis 1 day later.

Discussion

In the general population, gastric perforation is primarily associated with advanced PUD. Additional risk factors may also increase the life-long risk of PUD. *Helicobacter pylori* infection, smoking, alcohol, and nonsteroidal anti-inflammatory drugs (NSAIDs) are exposures known to increase the risk for PUD and perforation.⁶⁻⁹ Bariatric surgery is increasingly common in wealthy nations and, therefore, more frequently encountered in pregnancy.¹⁰ Bariatric surgery increases the risk for gastric perforation. Maternal congenital diaphragmatic hernias also increase the risk for gastric perforation. In the setting of maternal gastrointestinal symptoms and known congenital diaphragmatic hernia or bariatric surgery, gastric rupture should be considered in the differential diagnosis.

Gastric perforation should be suspected in the patient with preexisting PUD who manifests sudden-onset, severe, diffuse abdominal pain. Early diagnosis is essential to improve outcomes because the prognosis is favorable when diagnosis and treatment occur within the first 6 hours, but life-threatening when the diagnosis is delayed more than 12 hours.⁶

Understanding of the phases of ulcer perforation may decrease diagnostic delays.

In the first phase (within 2 hours following perforation), abdominal pain is usually sudden and may produce syncope or cardiovascular collapse. Pain is typically localized to the epigastric region but quickly becomes generalized. The initial phase reflects exposure of the peritoneal cavity to acidic fluid triggering release of vasoactive mediators. Tachycardia, weak pulse, cool extremities, and hypothermia may characterize this phase. The first-phase duration may range from minutes up to 2 hours. The severity of symptoms depends on the amount of peritoneal fluid released in the abdomen.

In the second phase, (2–12 hours after onset), abdominal pain may lessen and the inexperienced observer may be led to believe that the patient is clinically improving. Pain is usually generalized and often worsens with movement. The abdomen typically demonstrates board-like rigidity. Liver dullness to percussion may disappear secondary to peritoneal air. On rectal examination, the pelvic peritoneum may reveal tenderness due to irritation from inflammatory fluid. Right lower quadrant tenderness may develop due to fluid in the pelvic gutter.

In the third phase (> 12 hours after onset), increasing abdominal distention is noted, but abdominal pain, tenderness, and rigidity may be less prominent. Fever and hypovolemia may result from third spacing. Acute cardiovascular collapse may occur as a result of advanced peritonitis.

Table 1 Summary of pregnancy associated gastric rupture case reports

Author, year, country	Case summary	Timing of rupture and risk factor (antepartum/postpartum)	Maternal/neonatal outcome
Miller (1933) ¹⁵ USA	A 29-year-old primipara presented in labor at term. Her prenatal course was complicated by emesis during the last month of pregnancy. During the second stage of labor, she developed hypovolemic shock and initially responded to fluid resuscitation. A healthy infant was delivered with forceps. However, 20 h after delivery, she went into a coma and died. At autopsy, a 3-cm perforation of the greater curvature of the stomach was found. The etiology of the rupture was unknown.	Antepartum Spontaneous	Maternal death/ neonatal survival
Christoph and Pinkham (1961) ¹⁹ USA	A 17 year-old at 39 weeks s/p surgery for acute appendicitis. She developed circulatory collapse secondary to gastric perforation postpartum.	Postpartum Spontaneous	Maternal and neonatal survival
Fiester and Zinn (1975) ¹⁴ USA	A 30-year-old woman in her sixth month of pregnancy presented with nausea, vomiting, and headache. She died soon after admission. Autopsy findings included a 4–5-cm perforation on the greater curvature of the stomach, fetal death.	Antepartum Spontaneous	Maternal death/ in utero fetal death
Seon Cha et al (2002) ¹ USA	A young, primigravida delivered a 34-week stillborn infant. Shortly after delivery, she developed signs of hypovolemic shock. Ultrasound examination showed a large amount of free intra-abdominal fluid. At laparotomy, gastric rupture was encountered and repaired. Congenital eventration of the left hemidiaphragm was also noted. After a complicated postoperative course, the patient recovered and did well.	Postpartum Maternal congenital diaphragmatic hernia	Maternal survival/ in utero fetal death
Erez et al (2004) ³ Israel	A 27-year-old primigravida at 35 weeks' gestation and history of gastric banding presented to labor and delivery with protracted nausea and vomiting. She was initially diagnosed and treated for a small bowel obstruction but hours later developed an acute abdomen and non-reassuring fetal testing. Exploratory laparotomy and cesarean delivery were performed. Gastric secretions and blood were found in the abdomen. A perforated gastric ulcer was diagnosed and repaired. Neonate and mother were discharged home.	Antepartum Maternal bariatric surgery (gastric banding)	Maternal and neonatal survival
Luu et al (2006) ² USA	A healthy 34-year-old primigravida woman presented to the emergency department at 33 weeks' gestation, with history of nausea, vomiting, and back pain. She was diagnosed with pneumonia and discharged home on azithromycin. The patient returned 8 d later with a new onset of shortness of breath and severe left-sided chest and back pain. Chest X-ray showed a left pleural effusion. The patient went into preterm labor and vaginal delivered of a healthy 34-week neonate. A computed tomography (CT) scan the following day showed extravasation of oral contrast into the left pleural space. Urgent thoracotomy demonstrated a herniated portion of necrotic stomach protruding through a 2-cm diaphragmatic defect. A 2-cm perforation of the stomach was identified and repaired.	Postpartum Maternal congenital diaphragmatic hernia	Maternal and neonatal survival
Strezelczyk and Peczak (2008) ¹¹ Poland	A 23-year-old at 36 weeks' gestation presented with mild pain of entire abdomen for several hours prior to admission preceded by severe vomiting after a heavy meal the day prior to admission. Taken for cesarean delivery for tense abdomen and recurrent fetal decelerations. Intraoperatively, gas and gastric contents were	Antepartum Spontaneous	Maternal and neonatal survival

(Continued)

Table 1 (Continued)

Author, year, country	Case summary	Timing of rupture and risk factor (antepartum/postpartum)	Maternal/neonatal outcome
	noted in peritoneal cavity with perforation of the anterior wall and fundus of stomach and repaired. Both neonate and mother were discharged to home.		
Morcillio-Lopez et al (2010) ⁵ Spain	A 35-year-old primigravida at 15 weeks' gestation presented to the emergency department with intense, sudden onset of dyspnea. She had a known congenital diaphragmatic hernia. CT scan demonstrated herniation of abdominal contents through the diaphragmatic defect. Thoracotomy demonstrated diaphragmatic and gastric rupture. Both defects were repaired and she underwent cesarean delivery at 38 weeks' gestation.	Antepartum Maternal congenital diaphragmatic hernia	Maternal and neonatal survival
Policiano et al (2013) ⁴ Portugal	A 37-year-old primigravida at 33 weeks' gestation with a history of gastric band who developed abdominal pain, vomiting, and non-reassuring fetal testing. Emergency cesarean delivery demonstrated hemoperitoneum, and gastric rupture was identified and repaired. Both neonate and mother were eventually discharged home.	Antepartum Maternal bariatric surgery (gastric banding)	Maternal and neonatal survival

Treatment delay greater than 12 hours increases the risk of severe morbidity and mortality. Delayed diagnosis may occur during pregnancy and the puerperium due to anatomic changes of pregnancy that may result in diminished peritoneal signs and nonclassic disease localization.^{2,11}

In two of our cases, the cause of gastric perforation was unclear. The patients had no clear history of PUD. Spontaneous gastric rupture is rare for several reasons: the stomach is protected by the liver and ribs; has mobile, distensible walls; and the gastroesophageal and pyloric valves decrease intra-gastric pressure.¹

Our literature search identified nine cases of gastric perforation associated with pregnancy (► **Table 1**).^{1-5,12-15} Two of these cases occurred in the setting of bariatric surgery.^{3,4}

Isolated gastric ruptures are very rare during pregnancy and reported cases are often associated with congenital diaphragmatic hernias.¹ Ideally, pregnant women with diaphragmatic disorders should be identified antenatally or during the first weeks of pregnancy. Correction of the defects and avoidance of situations that may lead to increased intra-abdominal pressure are essential to reduce the risk for diaphragmatic hernia-associated gastric perforation.¹

All of our cases occurred unexpectedly in the postpartum period. No clear medical histories of gastric ulcers were identified. Patients reported epigastric pain, but PUD was not considered in the differential diagnosis. Peritonitis, following cesarean delivery, is a very common clinical finding at CHUK and is the leading cause of severe maternal morbidity and mortality.¹⁶ As a result, the cases described here were managed as cases of peritonitis.¹⁶

Our first case occurred only 2 days after a caesarean section in the setting of ascariasis. In addition to intestinal obstruction, case reports also link *ascaris lumbricoides* with gastric perforation.^{12,17} In 2004, a case from Nigeria described a 65-year-old woman with an acute abdomen. Exploratory laparotomy 6 hours

later demonstrated 3 L of feculent peritoneal fluid, fibrinoid adhesions, and a 25-cm-long live worm in the peritoneal cavity. The patient was noted to have a gastric perforation. Investigators theorize that the worm converted a near perforation into frank perforation or the perforation occurred initially, followed by egress of the worm into the peritoneum.¹⁸ In 2012, Gupta et al describe the case of a 48-year-old man from India who presented with an acute abdomen. At the time of laparotomy, 1.2 L of bilious fluid was drained and a 1 cm × 1 cm stomach perforation was noted. Two live ascaris worms were seen protruding through the perforation site. No scarring or induration around the perforation site was noted. These findings were more consistent with an ascariasis-related perforation rather than long-standing PUD.¹²

Our cases demonstrate the high maternal mortality and morbidity associated with gastric rupture. Part of the diagnostic delay was associated with the rare nature of this condition. In all cases reported in the literature, gastric rupture was not considered in the differential diagnosis at the time of presentation. One patient survived the event in our case series. Her circulatory collapse prompted immediate laparotomy for suspected sepsis. The unexpected gastric rupture was diagnosed and repaired. Although she survived the event, gastric rupture caused a severe, life-threatening, maternal morbidity.

In the first case, the presentation began 2 days following the cesarean delivery. The initial diagnosis did not include gastric perforation. The patient probably arrived in the second or the third phase of gastric perforation where signs in favor of acute abdomen (perforation) may be less evident and may lead to a false impression of clinical improvement. The pain of labor and the puerperium may have interfered with the clinical interpretation. All of these reasons led to poor outcome that ended with maternal death despite all resuscitative and operative interventions.

Conclusion

The diagnosis of gastric perforation relies on extensive medical history and a thorough physical examination; however, the pregnant or postpartum state may interfere with interpretation of the clinical features and complicate the ability to make the diagnosis. Pregnant women may experience diagnostic delays if providers are reluctant to expose the fetus to X-ray or computerized tomography

Given the importance of early and accurate management of gastric perforation, obstetricians and surgeons should be aware of this condition and consider it as part of the differential diagnosis in the pregnant and postpartum patient with acute-onset gastrointestinal symptoms. The diagnosis should be highly considered in pregnant patients with history of bariatric surgery or PUD. Clinical investigations including abdominal ultrasound and chest X-ray add to the history and clinical picture and enable providers to narrow the differential diagnosis. Both modalities are available in our low-resource clinical setting. These cases highlight the importance of early diagnosis and treatment to improve maternal outcome.

Ethical Approval

The University Teaching Hospital of Kigali (CHUK) Ethics committee approved the publication of this manuscript. A copy of ethical approval is available to the journal editors for review

Competing Interests

The authors declare that there is no competing interest for this case series.

Funding

No funding was obtained for the identification and writing of this case series.

Authors' Contributions

All authors contributed to the writing of this manuscript.

references

- 1 Seon Cha A, Krew MA, Tamlyn T, Gill P. Gastric rupture associated with pregnancy. *Obstet Gynecol* 2002;100(5 Pt 2):1072–1074
- 2 Luu TD, Reddy VS, Miller DL, Force SD. Gastric rupture associated with diaphragmatic hernia during pregnancy. *Ann Thorac Surg* 2006;82(5):1908–1910
- 3 Erez O, Maymon E, Mazor M. Acute gastric ulcer perforation in a 35 weeks' nulliparous patient with gastric banding. *Am J Obstet Gynecol* 2004;191(5):1721–1722
- 4 Policiano C, Rocha P, Catanho MC, Pinto L, Valentim-Lourenço A, Graça LM. Acute fetal asphyxia after gastric rupture in a pregnant patient with a gastric band. *Acta Obstet Gynecol Scand* 2013; 92(12):1419–1421
- 5 Morcillo-López I, Hidalgo-Mora JJ, Baamonde A, Díaz-García C. Gastric and diaphragmatic rupture in early pregnancy. *Interact Cardiovasc Thorac Surg* 2010;11(5):713–714
- 6 Svanes C, Lie RT, Svanes K, Lie SA, Søreide O. Adverse effects of delayed treatment for perforated peptic ulcer. *Ann Surg* 1994; 220(2):168–175
- 7 Mitchell HM, Hazell SL. *Helicobacter pylori*, gastric ulcer, and duodenal ulcer. *N Engl J Med* 1996;335(24):1841–1843, author reply 1842–1843
- 8 Mosiello G, Adorisio O, Gatti C, Boeris Clemen F, Dall'Oglio L, Federici di Abriola G. [Ascariasis as a cause of acute abdomen: a case report] [in Italian]. *Pediatr Med Chir* 2003;25(6):452–454
- 9 Nag HH, Ji R. Ascariasis presenting as acute abdomen—a case report. *Indian J Surg* 2013;75(Suppl 1):128–130
- 10 American College of Obstetricians and Gynecologists. ACOG practice bulletin no. 105: bariatric surgery and pregnancy. *Obstet Gynecol* 2009;113(6):1405–1413
- 11 Strelczyk SSL, Peczek M. Spontaneous gastric rupture in the peri-delivery period. *Pol Przegl Chir* 2008;80:676–680
- 12 Gupta A, Rathore AM, Manaktala U. Ascariasis presenting as acute abdomen during pregnancy and puerperium. *Southeast Asian J Trop Med Public Health* 2013;44(2):150–153
- 13 Foucard M. [Triple perforation caused by acute necrosis of the stomach in atrophic gastritis during a rupture of extrauterine pregnancy] [in French]. *Mars Chir* 1954;6(4):390–392
- 14 Fiester RF, Zinn LD. Spontaneous gastric rupture during pregnancy (case report). *W V Med J* 1975;71(5):110
- 15 Miller J. Spontaneous Rupture of the Stomach during Labor. *N Engl J Med* 1933;209:1085–1088
- 16 Rulisa S, Umuziranenge I, Small M, van Roosmalen J. Maternal near miss and mortality in a tertiary care hospital in Rwanda. *BMC Pregnancy Childbirth* 2015;15:203
- 17 Ihekwebaba FN. Intestinal ascariasis and the acute abdomen in the tropics. *J R Coll Surg Edinb* 1980;25(6):452–456
- 18 Ugwu BT, Yiltok SJ, Kidmas AT, Opaluwa AS. Typhoid intestinal perforation in north central Nigeria. *West Afr J Med* 2005;24(1):1–6
- 19 Christoph RF, Pinkham EW. Unexpected rupture of the stomach in the postpartum period: a case report. *Ann Surg* 1961;154(1):100–102