Posttraumatic Skull or Pandora's Box? An Interesting Case of Head Injury Featuring the Entire Spectrum of Traumatic Brain Lesions in an Elderly Patient

Bikash Ranjan Behera[1] Sanjib Mishra[1] Soubhagya Ranjan Tripathy[1] Ram Chandra Deo[1]

[1] Department of Neurosurgery, Shri Ramachandra Bhanj Medical College, Cuttack, Odisha, India

Indian J Neurotrauma 2016;13:154–156.

Address for correspondence Bikash Ranjan Behera, MS, Department of Neurosurgery, Shri Ramachandra Bhanj Medical College, Manglabag, Cuttack, Odisha 753007, India (e-mail: drtinku007@gmail.com).

Abstract

Traumatic brain injury (TBI) due to road traffic accident has assumed an epidemic proportion in the developing nations such as India; where a recent rise in vehicular traffic joins hands with poor road safety measures, to hand over the country it's unenviable status as the epicenter of this catastrophe. TBI can present in various forms including diffuse axonal injury, contusion, acute subdural hematoma (ASDH), epidural hematoma (EDH), subarachnoid hemorrhage (SAH), chronic subdural hematoma (CSDH), pneumocephalus, and so on. Commonly EDH occurs as a coup injury with ASDH occurring as a contrecoup injury on the diametrically opposite side. Contusion and intracerebral hematoma (ICH) can occur in both coup and contrecoup injuries. Various types of lesions can occur simultaneously in a single case of TBI. Here, we present an interesting case of TBI featuring the entire spectrum including EDH, ASDH, CSDH, SAH, ICH, pneumocephalus, fracture of a frontal bone on the same side of the brain. This report is perhaps one of its kinds in the available present literature. The mechanism and the pathophysiology of various lesions occurring simultaneously are discussed.

Keywords
- traumatic brain injury
- hematoma
- multiple lesions
- Pandora's box

Introduction

Head injury can present in various forms and in various combinations according to the mode of injury. Contact injuries cause skull fractures, extradural hematoma (EDH), pneumocephalus, and coup contusions. Acute subdural hematomas (ASDHs) are results of acceleration injuries. Chronic subdural hematoma (CSDH) is usually seen in the elderly patients, where cerebral atrophy causes widening of subdural space thus exposing the bridging veins to a greater risk of rupture when subjected to angular shearing forces. Pathology of traumatic subarachnoid hemorrhage (SAH) is poorly understood. Rupture of bridging veins or cerebral arteries are the likely sources. Here, we present a case where all these lesions coexist simultaneously in the same side of the brain which was managed surgically.

Case Report

A 75-year-old male patient was admitted to our emergency department with features of traumatic brain injury (TBI) after falling from the staircase. He was a known alcoholic and hypertensive, with a history of multiple falls while walking.

On admission the patient was found unconscious with Glasgow coma scale (GCS)-E2V2M3 (7/15), pupil examination revealed bilateral mid-dilated with sluggishly reacting to light. Blood pressure was 170/90 mm Hg and pulse was 75/min.

received
May 5, 2016
accepted after revision
August 31, 2016
published online
November 22, 2016

DOI http://dx.doi.org/10.1055/s-0036-1594018.
ISSN 0973-0508.

There was bleeding from the nose and also a fracture of the left clavicle. There was no history of convulsion or vomiting. With this much finding patient was shifted to intensive care unit and intubated.

All routine blood investigations were within normal limit. Coagulation profile, lipid profile, liver function test, and renal function test were also found to be normal. Screening X-ray of cervical spine did not reveal any abnormality. Noncontrast computed tomography (CT) scan of the brain showed left posterior parietal EDH, left parietal CSDH, SAH, left frontal ASDH, left frontal depressed fracture with pneumocephalus, and intracerebral hemorrhage (ICH) (►**Fig. 1**).

We planned for an emergency craniotomy. Left falconer scalp incision was made. Free bone flap craniotomy was done. Dura was firmly adhered with the bone and the dural tear was obvious. The posterior parietal EDH was evacuated (►**Fig. 2A**). Dura was incised in "U-shaped" manner and reflected toward the temporal base. Spontaneous evacuation of motor oil colored fluid (CSDH) with the appearance of ASDH was discovered during durotomy (►**Fig. 2B**). ASDH was evacuated to reveal an underlying angry looking brain, due to SAH (►**Fig. 2D**). The frontal contusion was excised. Hemostasis was maintained and the wound was closed in layers (►**Fig. 2**).

On second postoperative day patient was improved, with GCS-E4V4M5 (13/15). Postoperative CT scan revealed complete removal of all space-occupying lesions with improvement in midline shift (MLS). He was discharged on the seventh postoperative day with GCS-E4V5M6 (15/15) and residual right hemiparesis (grade 4/5).

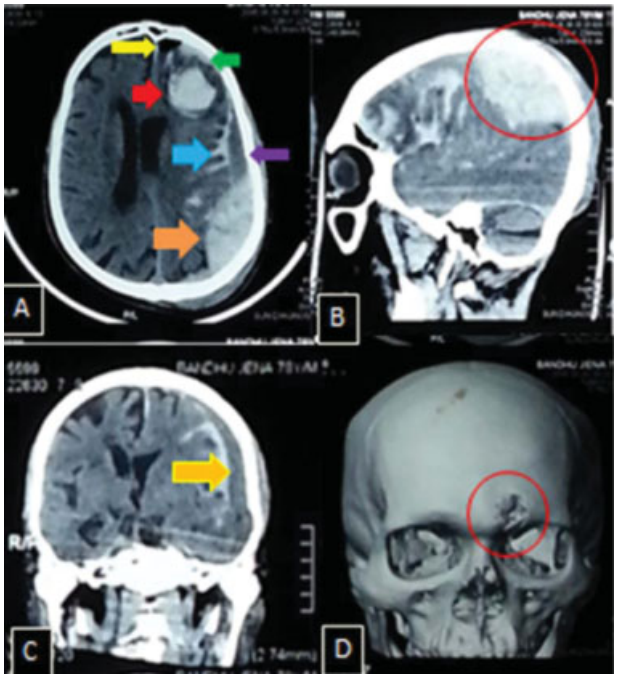

Fig. 1 (**A**) Preoperative NCCT scan axial view showing multiple lesions as follows: orange arrow-EDH, blue arrow-SAH, purple arrow-CSDH, red arrow-ICH, green arrow-ASDH, yellow arrow-pneumocephalus.(**B**) NCCT sagittal view showing posterior parietal EDH. (**C**) NCCT coronal view indicating left temporoparietal CSDH. (**D**) 3D area reconstruction of skull bone showing left frontal depressed fracture. 3D, three-dimensional; ASDH, acute subdural hematoma; CSDH, chronic subdural hematoma; EDH, epidural hematoma; ICH, intracerebral hematoma; NCCT, noncontrast computed tomography; SAH, subarachnoid hemorrhage.

Discussion

Though the exact incidence of head injury in the elderly population is not known, several studies reported incidence ranging from 2.7 to 15%.[1,2] According to the accepted terminology, people above 60 years are termed as elderly.[1] Goodman and Englander[3] had reported, fall to be the most frequent cause of the head injury in elderly patients; as compared with road traffic accident in the younger age group, which is also the mode of injury in our case.

In elderly patients several factors such as thickness of skull bone, adhesion of dura to inner table of skull, cerebral atrophy, status of cerebral blood vessel, associated conditions such as diabetes and hypertension influence the final outcome of TBI.[4] Klashee et al reported four times higher incidence of intracranial hematomas in posttraumatic patient older than 45 years associated with hypertension.[5] Trotter was the first to describe the mechanism of traumatic CSDH in elderly patients. Here, cerebral atrophy causes widening of subdural space thus exposing the bridging veins to a greater risk of rupture when subjected to angular shearing forces.[6] Sinha et al reported systemic illness such as diabetes, hypertension, associated fractures, fluid-electrolyte imbalance significantly alters the outcome of TBI in elderly patients.[7] Even though the atrophic brain in elderly patients can accommodate a significant amount of blood, we preferred immediate surgical decompression due to the low level of consciousness (GCS) and significant mass effect with MLS. Finally, the management of all medical comorbidities has to be addressed in priority in elderly patients like ours.

Blood everywhere and with all possible form in all possible compartments in a single brain is an interesting sequel to TBI. In our extensive database search (PubMed), we couldn't find reports of the combination of EDH, ASDH, SAH, ICH, preexisting CSDH, pneumocephalus in one hemisphere of the brain. So, to the best of our knowledge, this might be the first reported instance of an entire spectrum of TBI, fanning out in one hemisphere; akin to opening up of a "Pandora's box" and taking out "what not" from the curse of a traumatic brain.

The mechanism of injury that can cause such an extensive bleed is uncertain. We hypothesize that the EDH in the posterior parietal region occurred following the direct impact due to coup injury which was evident from scalp hematoma over the EDH site, but ASDH on the same side is difficult to explain.[8,9] An associated pia-arachnoid injury probably resulted in the dissection of the arachnoid and extension of hematoma into the subarachnoid space .CSDH is probably due to repeated previous fall with atrophic brain causing bridging vein tear in past and was merely an incidental finding.

Hemorrhagic contusion in the left frontal region may be explained in form of contrecoup hematoma, which expanded probably due to prior uncontrolled hypertensive

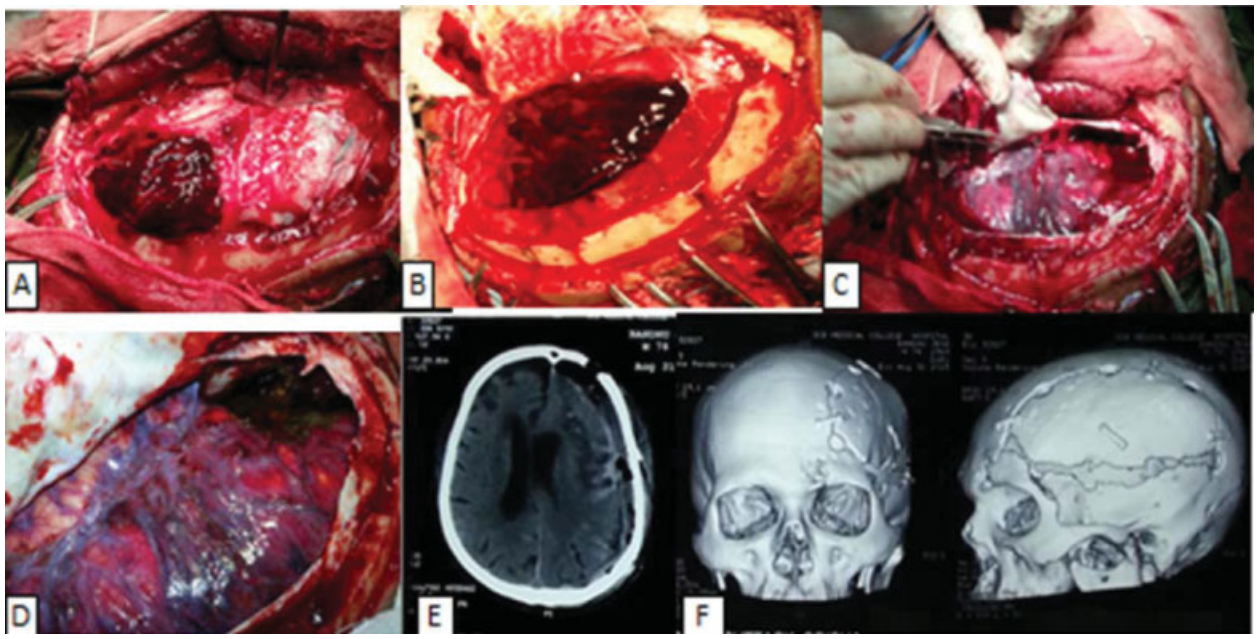

Fig. 2 (**A**) Intraoperative image showing EDH, (**B**) ASDH, (**C**) frontal contusion, (**D**) SAH, (**E**) postoperative NCCT axial view showing no mass lesion with minimal MLS and (**F**) postoperative 3D reconstruction of a skull showing craniotomy defect. 3D, three-dimensional; ASDH, acute subdural hematoma; EDH, epidural hematoma; MLS, midline shift; NCCT, noncontrast computed tomography; SAH, subarachnoid hemorrhage.

status or alternately, due to normotensive brain getting raised intracranial pressure post this traumatic episode. Another coup injury in the left frontal region might have caused the left frontal fracture with pneumocephalus. So probably there were two coup injuries (primary and secondary impact injuries) on the same side of the brain with the previous presence of CSDH.

Conclusion

Around 5 to 10% of all head injury patients are of elderly age group. The most frequent cause is fall. Due to cerebral atrophy, more space is available for expanding hematomas in all possible cerebral compartments. This interesting case of TBI, featuring EDH/ASDH/CSDH/SAH/pneumocephalus/ICH, is perhaps the first reported case in our extensive literature search (PubMed). Hence, the neurosurgeons should be aware of this constellation, and promptly intervene at the first sign of deterioration of the neurological status of the patient.

References

1 Wilson JA, Pentland B, Currie CT, Miller JD. The functional effects of head injury in the elderly. Brain Inj 1987;1(2):183–188
2 Galbraith S. Head injuries in the elderly. Br Med J (Clin Res Ed) 1987;294(6568):325
3 Goodman H, Englander J. Traumatic brain injury in elderly individuals. Phys Med Rehabil Clin N Am 1992;32(2):441–459
4 Mahapatra AK, Kumar R, Kamal R. Textbook of Traumatic Brain Injury. New Delhi, India: Jaypee Brothers Med Publishers Ltd.; 2012:191–195
5 Kalsbeek WD, McLaurin RL, Harris BS 3rd, Miller JD. The National Head and Spinal Cord Injury Survey: major findings. J Neurosurg 1980;(Suppl):S19–S31
6 Trotter W. Chronic subdural hemorrhage of traumatic origin, and its relation to pachymeningitis hemorrhagic interna. Br J Surg 1914;2(6):271–291
7 Sinha AK, Mahapatra AK, Bhatia RJ. Acute head injury infielders. JANE 2000;4:27–33
8 Monsalve GA. The “CT comma sign” in head trauma: concurrent epidural and subdural acute intracranial hematomas. J Trauma 2007;63(1):195–196
9 Gupta R, Mohindra S, Verma SK. Traumatic ipsilateral acute extradural and subdural hematoma. Indian J Neurotrauma 2008;5(2):113–114