

Reference Ranges of Fetal Cerebral Lateral Ventricle Parameters by Ultrasonography

Intervalos de referência para parâmetros do ventrículo lateral de cérebros fetais por ultrassonografia

Aderemi Ishola¹ Christianah Mopelola Asaleye¹ Oluwagbemiga Oluwole Ayoola¹
Olabisi Morebise Loto² Bukunmi Michael Idowu¹

¹Department of Radiology, Obafemi Awolowo University Teaching Hospitals Complex, Ile – Ife, Osun state, Nigeria

²Departments of Obstetrics, Gynecology and Perinatology, Obafemi Awolowo University Teaching Hospitals Complex, Ile – Ife, Osun state, Nigeria

Address for correspondence Bukunmi Michael Idowu, MBBS, FWACS, FMCR, Department of Radiology, Obafemi Awolowo University, Ile-Ife, Osun State, Nigeria (e-mail: ibmcontacts@gmail.com).

Rev Bras Ginecol Obstet 2016;38:428–435.

Abstract

Objectives This study was done to evaluate the normal fetal cerebral lateral ventricle dimensions with transabdominal ultrasonography. The atrial width (AW), ventricle-to-choroid measurement (V-C), ventricle-to-hemisphere ratio (VHR), and combined anterior horn measurement (CAHM) were taken.

Methods This was a cross-sectional study involving 400 normal singleton pregnant subjects whose gestational ages were between 14 and 40 weeks. Transabdominal sonography was performed to obtain the values of the fetal cerebral lateral ventricle (FCLV) parameters. Data were reported as mean \pm standard deviation (SD) for continuous variables. The degrees of correlation between FCLV parameters and the estimated gestational age (EGA) were obtained using Pearson's correlation. Regression equations were used to generate the reference limits for the FCLV measurements.

Results The values of AW, V-C measurements and CAHM increased with advancing gestation. The mean values of the AW, V-C and CAHM from 14 to 40 weeks increased from 6.60 ± 0.94 mm to 9.75 ± 0.07 mm ($R^2 = 0.114$), 0.80 ± 0.00 mm to 1.90 ± 0.14 mm ($R^2 = 0.266$), and 6.95 ± 0.06 mm to 23.07 ± 4.02 mm ($R^2 = 0.692$) respectively, while the mean VHR decreased from $61.20 \pm 1.60\%$ to $42.84 \pm 2.91\%$ ($R^2 = 0.706$) over the same period.

Conclusion The AW, V-C, and CAHM increase, while VHR decreases with advancing gestation.

Keywords

- ▶ ultrasonography
- ▶ fetus
- ▶ ventricle
- ▶ ventriculomegaly
- ▶ reference range

Resumo

Objetivos O presente estudo objetiva avaliar as dimensões do ventrículo lateral de cérebros fetais por meio de ultrassonografia transabdominal. Foram medidos a largura do átrio (LA), a medida do ventrículo ao coroide (V-C), a razão ventrículo/ hemisfério (RVH), e a medida dos cornos anteriores combinados (CAC).

received
March 25, 2016
accepted
July 22, 2016
published online
October 17, 2016

DOI <http://dx.doi.org/10.1055/s-0036-1593410>.
ISSN 0100-7203.

Copyright © 2016 by Thieme Publicações Ltda, Rio de Janeiro, Brazil

License terms



Palavras-chave

- ▶ ultrassonografia
- ▶ feto
- ▶ ventrículo
- ▶ ventriculomegalia
- ▶ intervalo de referência

Métodos Estudo transversal com 400 grávidas de único feto com idades gestacionais entre 14 e 40 semanas. Sonografias transabdominais foram realizadas para obter os valores dos parâmetros do ventrículo lateral de cérebros fetais (VLCF). Dados foram apresentados em média \pm desvio padrão para variáveis contínuas. Os graus de correlação entre parâmetros de VLCF e idade gestacional estimada foram obtidos usando a correlação de Pearson. Equações de regressão foram usadas para gerar as referências-limite para medidas de VLCF.

Resultados Os valores de LA, medida do V-C e CAC aumentaram com o avanço da gestação. Os valores médios de LA, V-C e CAC de 14 a 40 semanas aumentaram de $6,60 \pm 0,94$ mm a $9,75 \pm 0,07$ mm ($R^2 = 0,114$), de $0,80 \pm 0,00$ mm a $1,90 \pm 0,14$ mm ($R^2 = 0,266$), e de $6,95 \pm 0,06$ mm a $23,07 \pm 4,02$ mm ($R^2 = 0,692$), respectivamente, enquanto a RVH média diminuiu de $61,20 \pm 1,60\%$ para $42,84 \pm 2,91\%$ ($R^2 = 0,706$) no mesmo período.

Conclusão A LA, V-C, e CAC aumentaram, enquanto a RVH diminuiu com o avanço da gestação.

Introduction

Ventriculomegaly (VM) refers to dilatation of the cerebral ventricles. This may be associated with normal, larger, or smaller heads than expected for menstrual age.¹ Hydrocephalus, however, refers to enlarged ventricles associated with increased intracranial pressure and/head enlargement¹ or ventriculomegaly of obstructive cause.² Ventriculomegaly has a significant adverse effect on fetal outcome; it may be associated with other congenital anomalies,² and has a prevalence of ~ 0.3 – 22 per 1,000 live births.³

Previously established cut-off values of fetal cerebral lateral ventricles (FCLVs) dimensions are: normal (< 10 mm), mild/borderline VM (10–12 mm), moderate VM (13–15 mm), and severe VM (> 15 mm).⁴ However, there is no consensus regarding these cut-off values, as some authors simply classify FCLV atrial diameters of 10–15 mm as mild VM, and those greater than 15 mm as severe VM.^{4,5} Previously established reference ranges⁶ of FCLV documented only the atrial width (AW). Recently, new parameters such as the choroid plexus/lateral ventricle diameter ratio, the choroid plexus/lateral ventricle length ratio, and the choroid plexus/lateral ventricle area ratio were described as helpful in assessing ventriculomegaly at 11–14 weeks of gestational age.⁷ The importance of these measurements is to ensure consistency and accuracy of diagnosing fetal VM. The known causes of fetal VM are diverse, and there is also a wide spectrum of possible neurodevelopmental outcomes.^{5,8–10} The aim of this study is to establish gestational age-based reference ranges for the FCLV, AW, ventricle-to-choroid (V-C) measurement, ventricle-to-hemisphere ratio (VHR), and combined anterior horn measurement (CAHM).

Methods**Study Design and Study Population**

This prospective, cross-sectional study was performed on 400 consecutively recruited singleton pregnant women at 14 to 40 weeks of gestational age. They were referred from the

antenatal clinic for routine prenatal fetal ultrasound at the Radiology Department of the institution between July 2012 and June 2013. The local Ethics and Research Committee approved the study protocol, and informed consent was obtained from all the participants.

Data Collection

Demographic parameters, including age, last menstrual period and parity, were obtained from all subjects. Subjects with multiple gestations, fetal congenital anomalies, maternal chronic hypertension, maternal diabetes mellitus, irregular menstrual periods, suspected intrauterine growth retardation, brachycephaly (short-headedness, with a cephalic index of 80.0–84.9),¹¹ dolichocephaly (long-headedness, with a cephalic index of 70.0–74.9),¹¹ oligohydramnios (single largest amniotic fluid pocket devoid of fetal parts or cord ≤ 2 cm in anteroposterior extent),¹² and polyhydramnios (single largest amniotic fluid pocket devoid of fetal parts or cord > 8 cm in anteroposterior extent)¹² were excluded from the study. Other relevant data were extracted from the subjects' medical records to confirm their eligibility for the study.

Sonographic Evaluation

A MINDRAY® real-time ultrasound scanner model DC 7 (Shenzhen Mindray Bio-medical Electronics, Nanshan, Shenzhen, China) with a 3.5–5 MHz curvilinear transducer was used to evaluate all subjects by the first author, who had more than 5 years' experience in Obstetrics sonography. Each subject was scanned only once during the study. Each patient was put in supine position on the examination couch with a slight left lateral tilt, and coupling gel was applied to the abdomen to reduce acoustic impedance. Routine obstetric sonography was done first for each subject to determine the number of fetuses, gestational age, fetal weight, and to exclude fetal malformations and placental abnormalities.

Estimation of the fetal weight was done automatically by the scanner by computing the biparietal diameter (BPD), head circumference (HC), abdominal circumference (AC)

and femur length (FL), as incorporated in the Hadlock's four-parameter formula¹³: $\text{Log}_{10} \text{Weight} = 1.3596 - 0.00386 \text{ AC} \times \text{FL} + 0.0064 \text{ HC} + 0.00061 \text{ BPD} \times \text{AC} + 0.0424 \text{ AC} + 0.174 \text{ FL}$.

The fetal perineum was then evaluated to determine the gender. Visualization of the testis in the scrotum confirmed a male fetus. Gender determination in the early second trimester was done as described by Whitlow et al.¹⁴ Thereafter, the fetal head was scanned to obtain an axial image of the lateral ventricle farthest from the transducer, with the ultrasound beam directed approximately perpendicular to the long axis of the ventricle. This is the transventricular plane, which is just above the transthalamic/BPD plane. It demonstrates the anterior and posterior portions of the lateral ventricles and the echogenic glomus of the choroid plexus within the atrium. All FCLV parameters were taken in this plane/view (►Fig. 1).

Adjustment of the ultrasound gain and other settings was done for each patient to optimize the image. Freeze frame ultrasonographic capabilities and electronic on-screen calipers were used for all measurements. All fetal biometric and FCLV parameters (except V-C measurements) were successfully determined in all fetuses. The lateral ventricular atrium was completely filled by the choroid plexus in 50 fetuses; thus, only 350 fetuses had values for V-C measurements.

Data were reported as mean \pm standard deviation (SD) for continuous variables. The degrees of correlation between FCLV parameters and estimated gestational age (EGA) were obtained using Pearson's correlation. Regression equations were used to generate the reference limits for the FCLV measurements. Statistical significance was set at $p < 0.05$. The Statistical Package for Social Sciences (SPSS Inc., Chicago,

IL, USA) software, version 16.0 for Windows was used for data analysis.

Results

A total of 400 pregnant subjects with normal singleton pregnancies were recruited. The maternal age ranged from 17–42 years with a mean age of 29.93 ± 4.84 years. Forty two subjects (10.5%) were in the < 25 -year age group; 136 subjects (34%) were aged between 25 and 29 years; and 155 subjects (38%) were in the 30–34 years age bracket. The remaining 67 subjects (16.8%) were 35 years and above. There were 54 (13.5%) primigravid subjects, 342 (85.5%) multigravid (2–5 children) subjects, and 4 (1%) grand-multi-gravid (> 5 children) subjects.

The gestational ages of the fetuses ranged from 14 to 40 weeks, with a median age of 30.0 weeks. One hundred and forty eight (37%) male and 252 (63%) female fetuses were evaluated. Fetuses in the second trimester constituted 38% ($n = 152$) of the study group, while those in the third trimester constituted 62% ($n = 248$). The mean values of the AW, V-C measurement, CAHM, and VHR were 6.69 ± 1.03 mm, 1.55 ± 0.44 mm, 17.71 ± 4.48 mm and $49.96 \pm 6.99\%$ respectively. Only 350 fetuses had values for V-C measurements because the lateral ventricular atrium was completely filled by the choroid plexus in 50 (12.5%) fetuses. All FCLV parameters had statistically significant Pearson's correlation with EGA ($p = 0.000$), with r values of 0.338 for AW, 0.331 for V-C, 0.832 for CAHM, and -0.84 for VHR. The AW of male fetuses was significantly larger than that of female fetuses (►Table 1).

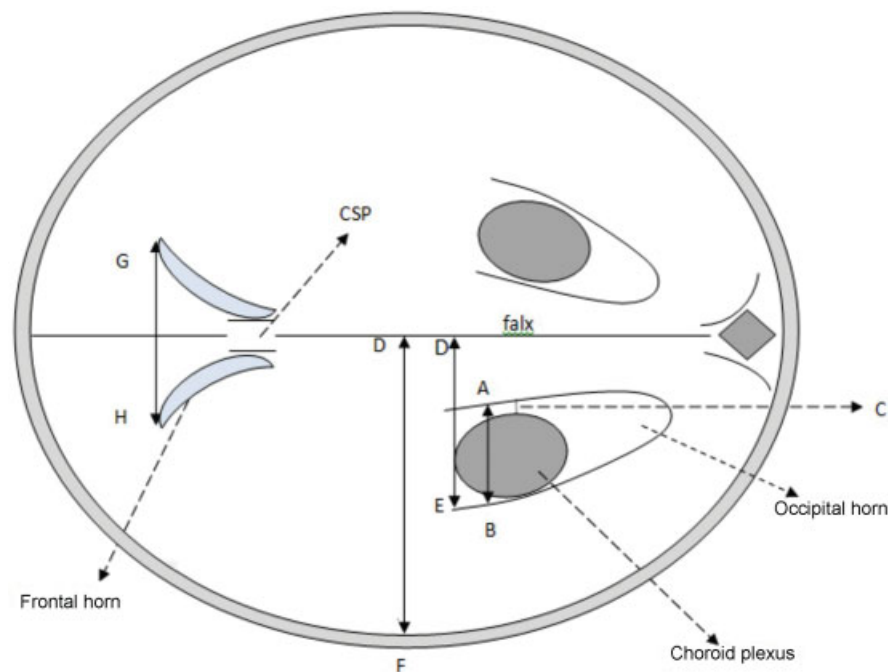


Fig. 1 Schematic diagram of the axial transventricular ultrasound image of a fetal brain showing the landmarks for obtaining measurements. 1. Atrial width (AW): A–B. 2. Ventricle-to-choroid measurement (V-C): C. 3. Ventricle to hemispheric ratio (VHR): DE/DF. 4. Combined anterior horn measurement (CAHM): G–H. 5. DE: Lateral ventricular width (LVW). 6. DF: Cerebral hemisphere width (CHW). 7. CSP: Cavum septum pellucidum.

Table 1 Fetal gender differences in FCLV measurements

Parameter	Mean \pm SD		t	df	p
	Male (n = 148)	Female (n = 252)			
AW (mm)	6.85 \pm 1.03	6.60 \pm 1.03	2.333	398	0.020
V-C (mm)	*1.55 \pm 0.43	**1.56 \pm 0.44	-0.168	348	0.867
CAHM (mm)	17.79 \pm 4.40	17.67 \pm 4.22	0.287	398	0.774
VHR (%)	50.52 \pm 6.68	49.63 \pm 7.15	1.238	398	0.216

Abbreviations: AW, atrial width; CAHM, combined anterior horn measurement; df, degree of freedom; FCLV, fetal cerebral lateral ventricle; SD, standard deviation; t, t-statistic; V-C, ventricle-to-choroid measurement; VHR, ventricle-to-hemisphere ratio.

*n = 126;

**n = 224.

Linear regression was the optimal model that described the effect of gestational age on the FCLV parameters recorded from our sample population. As the data were slightly skewed, the median (also called the 50th percentile) was used as a

measure of central tendency for each gestational age-specific FCLV parameter. The corresponding 5th and 95th percentiles were determined subsequently (**Table 2**). **Tables 3, 4, 5** and **6** show the reference ranges for the AW, VC, CAHM and

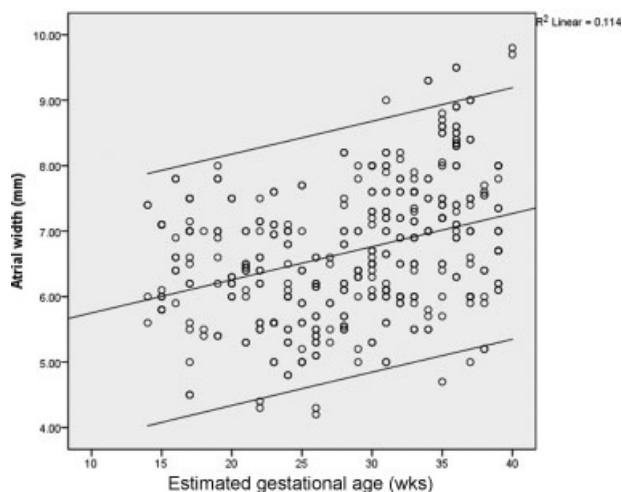


Fig. 2 Scatter plot of AW versus estimated gestational age (EGA), with the 5th, 50th and 95th percentile values.

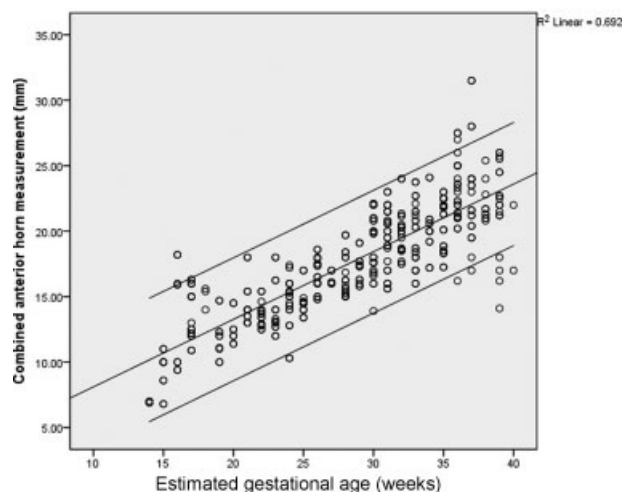


Fig. 4 Scatter plot of CAHM versus EGA, with the 5th, 50th and 95th percentile values.

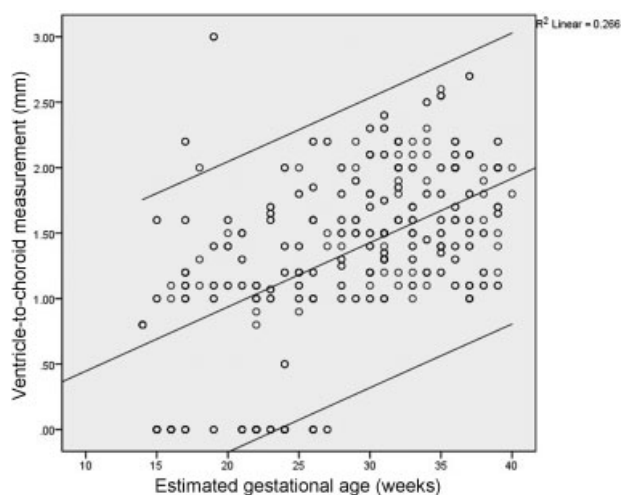


Fig. 3 Scatter plot of V-C measurement versus EGA, with the 5th, 50th and 95th percentile values.

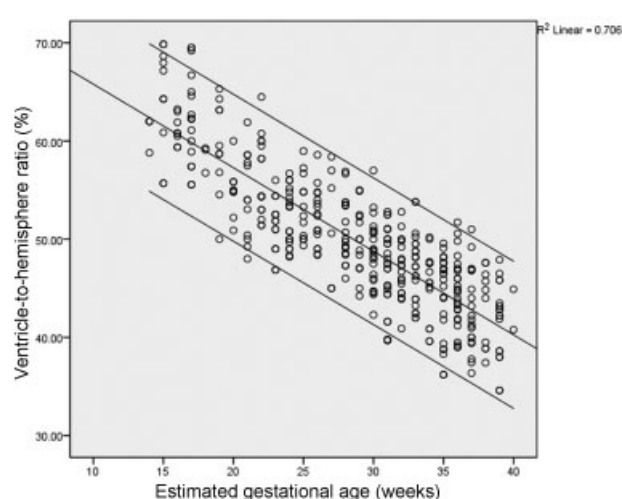


Fig. 5 Scatter plot of VHR versus EGA, with the 5th, 50th and 95th percentile values.

Table 2 Regression equations used for the generation of reference limits

AW	
5th Percentile	$AW = 4.347 + 0.041 * EGA$
50th Percentile	$AW = 5.032 + 0.059 * EGA$
95th Percentile	$AW = 6.007 + 0.070 * EGA$
CAHM	
5th Percentile	$CAHM = 3.871 + 0.374 * EGA$
50th Percentile	$CAHM = 3.321 + 0.488 * EGA$
95th Percentile	$CAHM = 3.737 + 0.588 * EGA$
V-C	
5th Percentile	$VC = 0.7207 + 0.012 * EGA$
50th Percentile	$VC = 0.734 + 0.027 * EGA$
95th Percentile	$VC = 1.024 + 0.036 * EGA$
VHR	
5th Percentile	$VHR = 69.401 - 0.864 * EGA$
50th Percentile	$VHR = 73.368 - 0.809 * EGA$
95th Percentile	$VHR = 77.288 - 0.759 * EGA$
LVW	
5th Percentile	$LVW = 3.391 + 0.378 * EGA$
50th Percentile	$LVW = 3.195 + 0.465 * EGA$
95th Percentile	$LVW = 3.408 + 0.534 * EGA$
CHW	
5th Percentile	$CHW = - 6.728 + 1.328 * EGA$
50th Percentile	$CHW = - 4.665 + 1.352 * EGA$
95th Percentile	$CHW = - 5.584 + 1.497 * EGA$

Abbreviations: AW, atrial width; CAHM, combined anterior horn measurement; CHW, cerebral hemisphere width; EGA, estimated gestational age; LVW, lateral ventricular width; V-C, ventricle-to-choroid measurement; VHR, ventricle-to-hemisphere ratio.

VHR respectively according to EGA. The scatter plots of the FCLV parameters according to EGA are shown in **►Figs. 2–5**. These plot-fitted percentile graphs show weak positive linear correlations of EGA with AW ($R^2 = 0.114$) and with VC ($R^2 = 0.266$). The CAHM had a strong positive linear correlation ($R^2 = 0.692$), while VHR had a strong negative correlation ($R^2 = 0.706$).

Discussion

Evaluation of the cerebral ventricular system is an integral part of all standard routine fetal sonographic examinations. Fetal VM can be isolated or associated with other congenital anomalies.⁵ Isolated fetal ventriculomegaly is the most common cerebral anomaly detected during routine prenatal pregnancy scans,¹⁵ and is a significant risk factor for developmental delay in children.¹⁵ It is important to visualize both lateral ventricles so as to not miss cases of bilateral VM.¹⁶ Ventriculomegaly is an indicator of poor fetal outcome; thus,

Table 3 Nomogram of AW according to EGA

EGA (week)	N	AW (mm)				
		Mean	SD	Percentiles		
				5th	50th	95th
14	4	6.60	0.94	4.93	5.86	6.99
15	10	6.39	0.62	4.97	5.92	7.06
16	8	6.80	0.68	5.01	5.98	7.13
17	18	6.40	0.99	5.05	6.04	7.20
18	3	5.97	0.90	5.09	6.10	7.27
19	10	6.81	0.93	5.13	6.15	7.34
20	8	6.50	0.63	5.17	6.21	7.41
21	12	6.28	0.54	5.21	6.27	7.48
22	16	6.13	0.93	5.26	6.33	7.55
23	14	6.21	0.95	5.30	6.39	7.62
24	18	6.09	0.77	5.34	6.45	7.69
25	13	6.03	0.96	5.38	6.51	7.76
26	18	5.58	0.68	5.42	6.57	7.83
27	6	5.95	0.52	5.46	6.63	7.90
28	18	6.50	0.90	5.50	6.69	7.97
29	13	6.47	0.85	5.55	6.75	8.04
30	25	6.78	0.80	5.59	6.80	8.11
31	28	6.81	1.03	5.63	6.86	8.18
32	20	6.81	0.82	5.67	6.92	8.25
33	24	6.87	0.76	5.71	6.98	8.33
34	14	7.12	1.23	5.75	7.04	8.40
35	24	7.36	1.04	5.79	7.10	8.47
36	26	7.95	0.90	5.83	7.16	8.54
37	20	6.91	1.12	5.88	7.22	8.61
38	10	6.55	0.99	5.92	7.28	8.68
39	18	6.99	0.65	5.96	7.34	8.75
40	2	9.75	0.07	6.00	7.40	8.82

Abbreviations: AW, atrial width; EGA, estimated gestational age; SD, standard deviation.

it is important to establish the normal variations of the cerebral ventricular parameters.¹⁷

This study found that the ventricular AW, V-C, CAHM and VHR show statistically significant correlations with the fetal EGA.

The mean AW of this study (6.69 ± 1.03 mm) can be compared to the mean value reported by other investigators.^{17–20} Hilpert et al¹⁷ documented a mean AW of 6.5 ± 1.5 mm using a mid-to-mid measurement technique because they could not distinguish the inner wall from the outer wall of the thin atrial margin. Cardoza et al²¹ reported a mean AW of 7.6 mm, which is much higher than that of the current study. This disparity could have resulted from their measurement technique: the atrium was measured by

Table 4 Nomogram of V-C dimension according to EGA

EGA (week)	N	V-C (mm)				
		Mean	SD	Percentiles		
				5th	50th	95th
14	4	0.80	0.00	0.89	1.12	1.53
15	4	1.30	0.35	0.90	1.14	1.57
16	2	1.05	0.07	0.91	1.17	1.61
17	14	1.34	0.41	0.93	1.20	1.64
18	3	1.47	0.47	0.94	1.23	1.68
19	8	1.63	0.86	0.95	1.25	1.72
20	8	1.39	0.20	0.96	1.28	1.75
21	8	1.35	0.18	0.97	1.31	1.79
22	8	1.00	0.11	0.99	1.33	1.82
23	10	1.40	0.32	1.00	1.36	1.86
24	8	1.28	0.57	1.01	1.39	1.9
25	13	1.32	0.35	1.02	1.42	1.93
26	14	1.49	0.43	1.03	1.44	1.97
27	4	1.83	0.43	1.05	1.47	2.01
28	18	1.44	0.31	1.06	1.50	2.04
29	13	1.60	0.35	1.07	1.52	2.08
30	25	1.60	0.41	1.08	1.55	2.12
31	28	1.56	0.42	1.09	1.58	2.15
32	20	1.85	0.32	1.11	1.61	2.19
33	24	1.55	0.31	1.12	1.63	2.22
34	14	1.76	0.50	1.13	1.66	2.26
35	24	1.69	0.45	1.14	1.69	2.3
36	26	1.78	0.35	1.15	1.72	2.33
37	20	1.58	0.54	1.17	1.74	2.37
38	10	1.49	0.33	1.18	1.77	2.41
39	18	1.73	0.35	1.19	1.80	2.44
40	2	1.90	0.14	1.20	1.82	2.48

Abbreviations: EGA, estimated gestational age; SD, standard deviation; V-C, ventricle-to-choroid measurement.

placing the cursor on the periphery of the lateral ventricular echogenic walls (outer-to-outer), in contrast with the inner medial to inner lateral walls method used in the present study. Furthermore, multiple sonologists were involved in their sonographic data acquisition, which could have introduced more errors in establishing the mean atrial size. Their sample size was also significantly smaller (100 fetuses, compared with 400 fetuses) than the sample size of this study. Cardoza et al²¹ suggested 10 mm as the upper cut-off for the atrial width, corresponding to 4 SDs above their mean value. Several other studies have supported the use of 10 mm as the upper limit of the ventricular atrial width, which often corresponds to 2.5 to 4 SDs above the mean.⁴

There were statistically insignificant ($p > 0.05$) marginal differences between the mean CAHM, V-C, and VHR of male

Table 5 Nomogram of CAHM according to EGA

EGA (week)	N	CAHM (mm)				
		Mean	SD	Percentiles		
				5th	50th	95th
14	4	6.95	0.06	9.10	10.16	11.97
15	10	9.28	1.54	9.47	10.64	12.56
16	8	13.39	4.04	9.85	11.13	13.15
17	18	13.68	1.96	10.22	11.62	13.74
18	3	15.00	0.87	10.59	12.11	14.33
19	10	12.01	1.65	10.97	12.60	14.92
20	8	12.60	1.24	11.34	13.09	15.51
21	12	14.57	1.80	11.72	13.57	16.09
22	16	13.61	0.92	12.09	14.06	16.68
23	14	14.17	2.08	12.46	14.55	17.27
24	18	14.54	1.98	12.84	15.04	17.86
25	13	14.69	1.12	13.21	15.53	18.45
26	18	16.64	1.27	13.58	16.02	19.04
27	6	16.37	0.49	13.96	16.50	19.62
28	18	16.63	1.64	14.33	16.99	20.21
29	13	17.17	1.11	14.70	17.48	20.80
30	25	18.84	2.31	15.08	17.97	21.39
31	28	19.68	2.24	15.45	18.46	21.98
32	20	19.90	1.85	15.82	18.94	22.57
33	24	19.69	2.39	16.20	19.43	23.15
34	14	20.29	2.00	16.57	19.92	23.74
35	24	20.69	1.95	16.95	20.41	24.33
36	26	22.83	2.59	17.32	20.90	24.92
37	20	23.07	4.02	17.69	21.39	25.51
38	10	22.10	1.52	18.07	21.87	26.10
39	18	21.85	3.51	18.44	22.36	26.68
40	2	19.50	3.54	18.81	22.85	27.27

Abbreviations: CAHM, combined anterior horn measurement; EGA, estimated gestational age; SD, standard deviation.

and female fetuses. However, atrial width was significantly larger ($p = 0.020$) in the male fetuses (6.85 ± 1.03 mm) compared with the female fetuses (6.60 ± 1.03 mm). This is similar to the findings of Patel et al¹⁸ in California, who also evaluated more female fetuses (female: male ratio [F:M] = 1.26:1), as in this study (F:M = 1.7:1), and found a mean atrial width of 5.8 ± 1.3 mm for females and of 6.4 ± 1.3 mm for males ($p < 0.05$). This finding may have implications for defining the upper limits of normal for the different genders. However, Pistorius²² found that the atrium was 0.2 mm smaller in male fetuses on average. The reason for this is not clear. Determination of gender in the early second trimester was quite challenging at times, and some of the fetuses were reexamined 4 to 6 weeks after the initial assessment.

Table 6 Nomogram of VHR according to EGA

EGA (week)	N	VHR (%)				
		Mean	SD	Percentiles		
				5th	50th	95th
14	4	61.20	1.60	57.31	62.04	66.66
15	10	64.43	5.39	56.45	61.23	65.90
16	8	61.12	1.48	55.58	60.42	65.14
17	18	62.34	4.48	54.72	59.61	64.38
18	3	58.37	1.40	53.86	58.81	63.63
19	10	59.41	4.79	52.99	58.00	62.87
20	8	54.93	2.70	52.13	57.19	62.11
21	12	54.42	4.45	51.26	56.38	61.35
22	16	56.21	3.96	50.40	55.57	60.59
23	14	51.41	2.72	49.54	54.76	59.83
24	18	52.18	2.92	48.67	53.95	59.07
25	13	53.05	3.21	47.81	53.14	58.31
26	18	52.15	2.78	46.95	52.33	57.55
27	6	51.87	5.93	46.08	51.52	56.79
28	18	50.86	3.18	45.22	50.72	56.03
29	13	49.76	3.44	44.35	49.91	55.28
30	25	48.61	3.33	43.49	49.10	54.52
31	28	46.73	4.14	42.63	48.29	53.76
32	20	46.97	2.96	41.76	47.48	53.00
33	24	47.02	3.41	40.90	46.67	52.24
34	14	45.13	3.59	40.04	45.86	51.48
35	24	44.28	4.22	39.17	45.05	50.72
36	26	44.55	3.52	38.31	44.24	49.96
37	20	42.54	4.02	37.45	43.43	49.20
38	10	43.08	3.99	36.58	42.63	48.44
39	18	41.67	3.86	35.72	41.82	47.69
40	2	42.84	2.91	34.85	41.01	46.93

Abbreviations: EGA, estimated gestational age; SD, standard deviation; VHR, ventricle-to-hemisphere ratio.

The mean V-C measurement in this study increased from 0.80 mm at 14 weeks to 1.90 mm at 40 weeks, as shown in **Table 4**. This is in agreement with the findings of other investigators.^{19,23} Mahony et al²⁴ defined lateral ventriculomegaly beyond 15 weeks as a 3 mm or more separation between the atrial choroid plexus and the ventricular wall, with a 1–2 mm separation in normal fetuses. Similarly, Hertzberg et al²³ also observed that a separation of 3 mm or more in the V-C measurement is associated with increased abnormal outcome in populations of fetuses with normal-sized ventricles.

The VHR is an invaluable tool for the serial monitoring of the growth rate of the ventricles relative to the surrounding cerebral tissue. Therefore, it is useful in providing the early prenatal diagnosis of VM/hydrocephalus. Other investiga-

tors^{25,26} demonstrated a steady decrease in VHR from 14/15 weeks to term, which they ascribed to the relatively more rapid growth of the cerebral hemispheres compared with cerebral ventricular growth. As a result of this steady change, VHR is said to be of greater diagnostic value than lateral ventricular width.

The current study shows a statistically significant steady decline of VHR throughout gestation from a mean of 61.20% at 14 weeks to 42.84% at 40 weeks. This is similar to the pattern of decline reported by Pilu et al,²⁵ though they had a value of 50% at term. However, D'Addario and Kurjak²⁷ and Johnson et al²⁶ recorded a decline in mean VHR from 61 and 56% respectively at 14/15 weeks to mean values of 29 and 28% respectively at 27 weeks (compared with 51% in the index study), which remained unchanged till term. Pilu et al²⁵ noted that the diagnosis of VM should be made with caution in the second trimester because the ventricles occupy a relatively large portion of the intracranial volume, and VHR range is large. Thus, serial ultrasound with no change or an increase in VHR during this period is needed to confirm the diagnosis of VM or hydrocephalus beyond reasonable doubt.

When a diagnosis of isolated mild VM is made, serial antenatal ultrasonography is necessary to monitor for worsening of the ventricular dilatation and late appearance of associated brain anomalies not detected earlier.¹⁶

In conclusion, real time B-mode transabdominal ultrasonography is a valuable tool for investigating fetal cerebral lateral ventricles. Both qualitative and quantitative parameters should be employed in the evaluation of fetal cerebral ventricles. Absolute threshold values of ventricular parameters should not be interpreted strictly, but should serve as a guideline to allow for the identification of fetuses that need closer monitoring of the fetal brain.

Conflict(s) of Interest

None to declare.

Acknowledgments

None.

References

- Toi A, Sauerbrei EE. The fetal brain. In: Rumack CM, Wilson SR, Chorboneau JW, editors. Diagnostic ultrasound. 2nd ed. St Louis: Mosby; 1998. p. 1256–60
- Brant WE. The core curriculum, ultrasound. Philadelphia: Lippincott Williams & Wilkins; 2001. Obstetric ultrasound-second and third trimester; p. 257–39
- Sethna F, Tennant PW, Rankin J, C. Robson S. Prevalence, natural history, and clinical outcome of mild to moderate ventriculomegaly. *Obstet Gynecol* 2011;117(4):867–876
- Seligman NS. Ultrasound for fetal ventriculomegaly. *Ultrasound Clin* 2013;8(1):13–25
- Ferreira C, Rocha I, Silva J, et al. Mild to moderate fetal ventriculomegaly: obstetric and postnatal outcome. *Acta Obstet Gynecol Port.* 2014;8(3):246–251

- 6 Salomon LJ, Bernard JP, Ville Y. Reference ranges for fetal ventricular width: a non-normal approach. *Ultrasound Obstet Gynecol* 2007;30(1):61–66
- 7 Manegold-Brauer G, Oseledchik A, Floeck A, Berg C, Gembruch U, Geipel A. Approach to the sonographic evaluation of fetal ventriculomegaly at 11 to 14 weeks gestation. *BMC Pregnancy Childbirth* 2016;16:3
- 8 Lo C [Internet]. Fetal ventriculomegaly guideline. 2010 [cited 2016 Jul 7]. Available from: <http://www.healthpoint.co.nz/downloadinfo,138318,otherList,6yfwc09a45w12r18te0r.do>
- 9 Kutuk MS, Ozgun MT, Uludag S, Dolanbay M, Poyrazoglu HG, Tas M. Postnatal outcome of isolated, nonprogressive, mild borderline fetal ventriculomegaly. *Childs Nerv Syst* 2013;29(5):803–808
- 10 Pagani G, Thilaganathan B, Prefumo F. Neurodevelopmental outcome in isolated mild fetal ventriculomegaly: systematic review and meta-analysis. *Ultrasound Obstet Gynecol* 2014;44(3):254–260
- 11 Franco FC, de Araujo TM, Vogel CJ, Quintão CC. Brachycephalic, dolichocephalic and mesocephalic: Is it appropriate to describe the face using skull patterns? *Dental Press J Orthod* 2013;18(3):159–163
- 12 Dahnert W. *Radiology review manual*. 7th ed. Philadelphia: Lippincott Williams & Wilkins; 2011. Amniotic fluid volume; p. 1015.
- 13 Hadlock FP, Harrist RB, Sharman RS, Deter RL, Park SK. Estimation of fetal weight with the use of head, body, and femur measurements—a prospective study. *Am J Obstet Gynecol* 1985;151(3):333–337
- 14 Whitlow BJ, Lazanakis MS, Economides DL. The sonographic identification of fetal gender from 11 to 14 weeks of gestation. *Ultrasound Obstet Gynecol* 1999;13(5):301–304
- 15 Vladareanu S, Traistaru VA, Vladareanu R. Fetal isolated ventriculomegaly: is there any neonatal consequences? *Donald Sch. J Ultrasound Obstet Gynecol*. 2015;9(1):75–79
- 16 D'Addario V. Fetal mild ventriculomegaly: still a challenging problem. *J Perinat Med* 2015;43(1):5–9
- 17 Hilpert PL, Hall BE, Kurtz AB. The atria of the fetal lateral ventricles: a sonographic study of normal atrial size and choroid plexus volume. *AJR Am J Roentgenol* 1995;164(3):731–734
- 18 Patel MD, Goldstein RB, Tung S, Filly RA. Fetal cerebral ventricular atrium: difference in size according to sex. *Radiology* 1995;194(3):713–715
- 19 Almog B, Gamzu R, Achiron R, Fainaru O, Zalel Y. Fetal lateral ventricular width: what should be its upper limit? A prospective cohort study and reanalysis of the current and previous data. *J Ultrasound Med* 2003;22(1):39–43
- 20 Alagappan R, Browning PD, Laorr A, McGahan JP. Distal lateral ventricular atrium: reevaluation of normal range. *Radiology* 1994;193(2):405–408
- 21 Cardoza JD, Goldstein RB, Filly RA. Exclusion of fetal ventriculomegaly with a single measurement: the width of the lateral ventricular atrium. *Radiology* 1988;169(3):711–714
- 22 Pistorius LR. *Imaging of fetal central nervous system [dissertation]*. Utrecht: University of Utrecht; 2008
- 23 Hertzberg BS, Lile R, Foosaner DE, et al. Choroid plexus-ventricular wall separation in fetuses with normal-sized cerebral ventricles at sonography: postnatal outcome. *AJR Am J Roentgenol* 1994;163(2):405–410
- 24 Mahony BS, Nyberg DA, Hirsch JH, Petty CN, Hendricks SK, Mack LA. Mild idiopathic lateral cerebral ventricular dilatation in utero: sonographic evaluation. *Radiology* 1988;169(3):715–721
- 25 Pilu G, Reece EA, Goldstein I, Hobbins JC, Bovicelli L. Sonographic evaluation of the normal developmental anatomy of the fetal cerebral ventricles: II. The atria. *Obstet Gynecol* 1989;73(2):250–256
- 26 Johnson ML, Dunne MG, Mack LA, Rashbaum CL. Evaluation of fetal intracranial anatomy by static and real-time ultrasound. *J Clin Ultrasound* 1980;8(4):311–318
- 27 D'Addario V, Kurjak A. Ultrasound investigation of the fetal cerebral ventricles. *J Perinat Med* 1985;13(2):67–77