

# Management Strategies for Growing Skull Fractures: A Single-Center Experience

Vernon Velho<sup>1</sup> Hrushikesh U. Kharosekar<sup>1</sup> Harish Naik<sup>1</sup> Shonali Valsangkar<sup>1</sup> Pravin Survashe<sup>1</sup>

<sup>1</sup>Department of Neurosurgery, Sir J. J. Group of Hospitals and Grant Medical College, Mumbai, Maharashtra, India

Address for correspondence Dr. Hrushikesh U. Kharosekar, MCh, Department of Neurosurgery, 4th floor, Sir J. J. Group of Hospitals and Grant Medical College, Byculla E, Mumbai, Maharashtra 400008, India (e-mail: hkharosekar@gmail.com).

Indian J Neurotrauma 2016;13:7–10.

## Abstract

**Introduction** Growing skull fractures are a rare but significant complication of pediatric head trauma, occurring mostly in children. Growing skull fractures are associated with a breach in the dura underlying the fracture line and may exceed the line of fracture making the management difficult. A delay in diagnosis exacerbates this disease increasing morbidity.

**Materials and Methods** A retrospective analysis of 36 patients who were operated for growing skull fracture between August 2005 and August 2015 in our institute was done.

**Results** Most common age group at presentation was 1 to 6 months and fall from height was the most common etiology. All patients underwent surgical repair; 23 required only duraplasty whereas cranioplasty with dural repair was done at the same time in 13 patients. Osteomesh, titanium mesh, and autologous bone chips were used for cranioplasty. All patients who presented to us with scalp swelling had complete resolution of swelling, whereas of the 7 patient who had neurologic deficit, 5 improved postoperatively (71%). Good clinical outcome was obtained in all patients.

**Conclusion** Herniation of the brain matter and underlying dural tear, which can extend beyond the bony defect makes management challenging in growing skull fracture.

## Keywords

- ▶ growing skull fracture
- ▶ Osteomesh
- ▶ titanium mesh
- ▶ duraplasty
- ▶ children

## Introduction

Growing skull fractures (GSFs) are a rare but significant complication of pediatric head trauma, occurring mostly in children who are younger than 3 years. Progressive herniation of the brain matter through the dural and bony defect results in seizure disorder and neurologic deficit. GSFs are associated with a breach in the dura underlying the fracture line and may exceed the line of fracture making the management difficult at time. Decision making in a given case is difficult and inappropriate selection results in a dissatisfactory result. Progressive pulsatile head swelling is the most common presenting feature. Clinical examination reveals a pulsatile swelling that becomes tense as the child cries. It is seen in 0.05 to 1.6% of pediatric head injuries.<sup>1</sup> Computed tomography (CT)

and magnetic resonance imaging (MRI) of the head confirms the diagnosis. Management involves identifying the fracture line, excision of gliotic brain, water-tight repair of dural breach, and cranioplasty at the earliest. A delay in diagnosis exacerbates this disease increasing morbidity. We report 36 patients with GSFs managed at our center and discuss their pathology, highlighting the principles of management, and review the literature<sup>1,2</sup>(word "of" removed).

## Materials and Methods

A retrospective analysis was performed in the department of neurosurgery at Grant Medical College and Sir J. J. Group of Hospitals. It included 36 patients who were operated for GSF between August 2005 and August 2015. The data were

received

November 19, 2015

accepted

March 17, 2015

published online

April 19, 2016

© 2016 Neurotrauma Society of India

DOI <http://dx.doi.org/>

10.1055/s-0036-1583266.

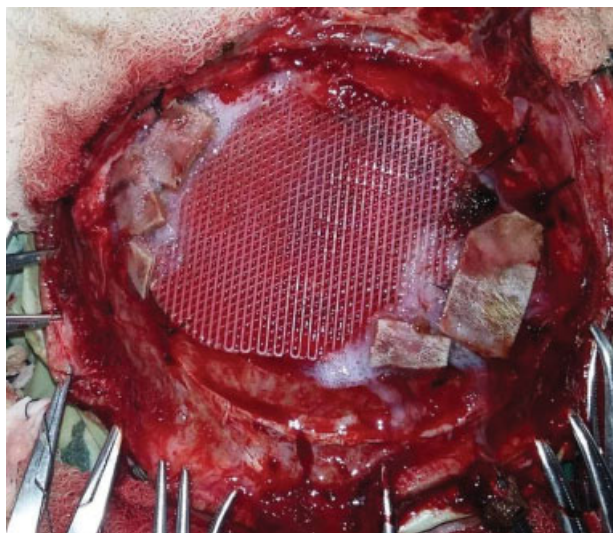
ISSN 0973-0508.

analyzed for mode of injury, clinical presentation, neurologic status, radiologic findings, surgical indications, and type of surgery performed. Clinical outcome was evaluated and patients were followed up for a period of 3 months to 2 years.

## Results

Out of 36 patients, 22 were male and 14 were female patients. The most common age group at presentation was 1 to 6 months ( $n = 15$ , 41%). History of trauma was present in all 36 patients. Twenty-seven patients had history of fall from height whereas 2 presented as child abuse. Thirty-four (95%) patients out of 36 had parietal bone fracture that was extending to frontal bone in 9 patients and temporal bone in 10 patients. The duration of presentation after head trauma was shorter than 2 months in 48% of cases, whereas it ranged from 1 month to 10 years. Scalp swelling was the most common presentation seen in 86% patients, whereas 39% presented with seizures and 20% had neurologic deficits at presentation. All patients underwent CT scan of the brain and skull radiography at admission. MRI of the brain was done in 13 patients (children who presented late and were cooperative during MRI scan, i.e., > 2 years of age). All patients showed bony defect whereas 27 showed herniation of the brain through the defect (75%). Only leptomeningeal cyst was seen in 9 (25%) patients. Encephalomalacia was seen in 17 patients. Among the 36 patients, 3 patients had hydrocephalus that were shunted after repair of dural defect.

All patients underwent surgical repair of GSF. The operative procedure consisted of defining the bony defect and identifying dural margin, excision of gliotic brain tissue, and duraplasty using the pericranial flap. This was done in 23 (64%) patients whereas 13 patients underwent cranioplasty in same sitting. These patients were older than 2 years. The rest 23 were either younger than 2 years or having small bony defect; therefore, they were advised follow-up. Cranioplasty was done using autologous bone, Osteomesh (Syncronei, Bangalore, Karnataka, India) or titanium mesh (► **Figs. 1 and 2**). Titanium mesh was



**Fig. 1** Images showing repair of dural defect and reconstruction using Osteomesh (case 1).

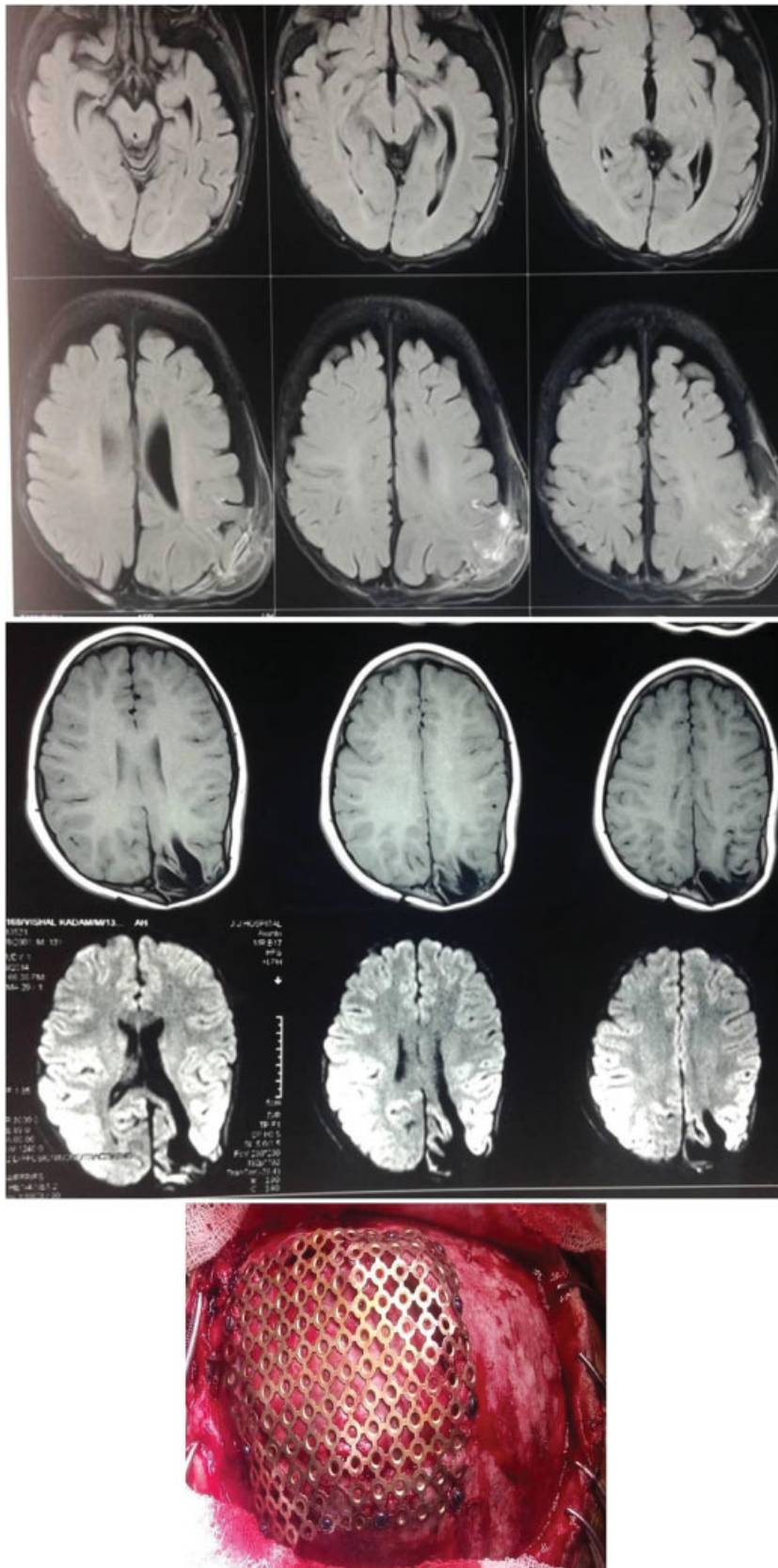
used in only two patients who were older than 5 years (completed skull growth). Postoperatively, five patients developed cerebrospinal fluid (CSF) leak, out of whom only one required reexploration and repair with tissue glue and the rest four were managed with prolonged lumbar drainage. Two patients had postoperative seizures, which were controlled with antiepileptic drugs (AED). All 31 patients who presented to us with scalp swelling had complete resolution of swelling. Out of seven patients who had contralateral hemiparesis, five improved postoperatively (71%). Two patients in whom contralateral hemiparesis did not improve as they presented late to us, that is, after 1 year of trauma. Reduction in brain herniation preventing subsequent progressive gliosis resulted in improvement of deficits that were due to herniation of parenchyma. Earlier the surgery better was the outcome in patients who had neurologic deficit. Good clinical outcome was obtained in all patients (► **Table 1**).

## Discussion

Growing skull fractures (GSFs), also known as “posttraumatic leptomeningeal cyst” or “cranio cerebral erosion,” was first described by Howship in 1816. GSF is a rare neurologic complication and accounts for 1.2 to 1.6% of the head injury patients.<sup>1,3</sup> The term “growing skull fracture” has been coined by Pia and Tonnis. The term “pseudoencephalocele” is also suggested as it more closely describes the pathology, as compared with “growing skull fracture” or “leptomeningeal cyst.” It is commonly seen in people younger than 1 year (50%), and nearly 90% of the patients are younger than 3 years, after which the condition is rare.<sup>2,4,5</sup>

The exact etiopathological process of GSF is unclear. The single most important factor in the pathogenesis of GSF is dural tear. It is unanimously accepted that the skull fracture, with its dural tearing and entrapment of the arachnoid membrane or brain tissue within the fracture margin, is the most important factor for GSF pathogenesis. Morphologically, the predominant factor responsible for fracture growth may lie in the subarachnoid space (a leptomeningeal cyst), cerebrum (herniated brain), or ventricle (dilated underlying ventricle with porencephalic cyst). These events constitute the morphologic basis for the fracture types I, II, and III, respectively.<sup>2</sup>

There are two main hypotheses to elucidate why the incidence of GSF is higher in infancy and early childhood than in adulthood.<sup>1,6</sup> One hypothesis states that during the first 2 years of life, rapid growth of the brain and skull occurs; the dura adheres more tightly to the bone and thus is more easily torn when the skull is fractured. The second hypothesis proposes that the skull is thinner, less stiff, and more deformable, and in deforming it can more readily tear the dura. In the early stage of GSF, the main damages to the brain and bone are caused by the injury itself. However, the damages as well as the neurologic deficits will increase during the progression of GSF, especially in the late stage. The neurologic deficits cause the main disruption in the quality of life for most patients with GSF. Against this background, reasonable classification of the progression of GSF as well as early



**Fig. 2** Images showing large dural defect closed primarily with reconstruction using titanium mesh.



**Table 1** Demographic table

Sex distribution (n = 36)		
Male	22	61%
Female	14	39%
Age at presentation (n = 36)		
0–6 mo	03	8.3%
6–12 mo	15	41.6%
1–3 y	12	33.3%
3–5 y	04	11.1%
5–7 y	01	2.7%
7–9 y	0	0
9–12 y	01	2.7%
History of trauma (n = 36)		
< 1 mo	13	36%
1–6 mo	15	41.6%
> 1 y	04	11.1%
2–5 y	03	8.3%
5–10 y	01	2.7%
Cause of injury (n = 36)		
Fall from height	27	75%
Vehicular accident	07	19%
Child abuse	02	5.5%
Presenting symptom (n = 36)		
Pulsatile scalp swelling	31	86%
Seizure	14	39%
Neurologic deficits	07	20%
Skull defect	36	100%
CT findings (n = 36)		
Bony defect	36	100%
Herniation of brain parenchyma	27	75%
Leptomeningeal cyst	09	25%
Encephalomalacia	17	47%
Unilateral ventricular dilation	09	25%
Hydrocephalus	03	8%
Treatment strategies (n = 36)		
Duraplasty using pericranium	23	63%
Duraplasty with cranioplasty	13	37%
Graft used for cranioplasty (n = 13)		
Autologous bone	05	
Titanium mesh	03	
Osteomesh	05	
Outcome (included)		
Scalp swelling resolved (n = 31)	31	100%
Contralateral weakness improved (n = 7)	5	72%

Abbreviation: CT, computed tomography.

diagnosis and rational surgical treatment for GSF will lead to improvement in prognosis.<sup>1</sup>

In 1961, Lende and Erickson reviewed the literature on this subject and emphasized on four essential features<sup>7</sup>: (1) skull fracture in infancy or early childhood; (2) dural tear at the time of fracture; (3) brain injury underlying the fracture; and (4) subsequent enlargement of the fracture resulting in a cranial defect. During trauma, which leads to fracture skull, the underlying dura gets torn. The developing brain exerts continuous pulsatile pressure, which widens the defects. Associated injury to the leptomeninges and brain facilitates the process, and increases the chance of growing fracture of skull. There is progressive resorption of the dural and bone edges, which leads to increase in size of the defect and cranial asymmetry. Repair of the defect should therefore be performed as soon as the diagnosis is made. Delay in the procedure makes the operation more difficult. It may also increase neurologic deficits by producing parenchymal herniation with subsequent gliosis. Every infant/child who has sustained the trauma should undergo a plain X-ray to rule out any fracture. If a fracture is found, CT scan should be done to rule out injury to the brain. Based on the CT appearance, GSFs are subdivided into three types. Type I refers to GSF with a leptomeningeal cyst, which may be seen herniating through the skull defect into the subgaleal space. Associated brain damage or gliosis is seen in type II, whereas type III is associated with porencephalic cyst. At surgical repair, the scalp is separated from the swelling, bone is drilled all around, and the dural margin is identified. The stretched pericranium is preserved for duraplasty after excision of gliotic brain. Skull defect can be closed using split-thickness bone graft, Osteomesh or titanium mesh. Titanium mesh is used in children with younger than 5 years in whom the skull growth is completed.<sup>1,2</sup>

## Conclusion

GSFs although uncommon can occur in infants and children of younger than 3 years. Children with significant scalp hematoma should undergo X-ray skull to rule out underlying fracture.

Herniation of the brain matter and underlying dural tear that can extend beyond the bony defect can make management challenging.

## References

- Liu XS, You C, Lu M, Liu JG. Growing skull fracture stages and treatment strategy. *J Neurosurg Pediatr* 2012;9(6):670–675
- Diyora B, Nayak N, Kamble H, Kukreja S, Gupte G, Sharma A. Surgical treatment and results in growing skull fracture. *Neurol India* 2011;59(3):424–428
- Sener RN. Growing skull fracture in a patient with cerebral hemiatrophy. *Pediatr Radiol* 1995;25(1):64–65
- Pia HW, Tonnis W. [Growing skull fractures of childhood]. *Zentralbl Neurochir* 1953;13(1):1–23
- Howship J. *Practical Observations in Surgery and Morbid Anatomy*. London, UKA Strahan 1816
- Rahimizadeh A, Haddadian K. Bilateral traumatic leptomeningeal cysts. *Neurosurgery* 1986;18(3):386–387
- Lende RA, Erickson TC. Growing skull fractures of childhood. *J Neurosurg* 1961;18:479–489