

# Idiopathic Spinal Cord Herniation—Case Report

## Herniação medular idiopática—relato de caso

Rogério Cirineo Sacco<sup>1</sup> Ricardo de Amoreira Gepp<sup>1</sup> Marco Rolando Sainz Quiroga<sup>1</sup>  
Henrique Caetano de Souza<sup>1</sup> Vitor Viana Bonan de Aguiar<sup>1</sup> Romel Corecha Santos<sup>1</sup>

<sup>1</sup> Rede SARAH de Hospitais, Brasília, DF, Brazil

Arq Bras Neurocir 2018;37:280–283.

Address for correspondence Rogério Cirineo Sacco, MD, Rede SARAH de Hospitais, SMHS 501, Conjunto A - Asa Sul, Brasília, DF, Brazil (e-mail: saccorc@uol.com.br).

### Abstract

#### Keywords

- ▶ spinal cord diseases
- ▶ Brown-Séguard syndrome
- ▶ myelography
- ▶ magnetic resonance imaging
- ▶ hernia
- ▶ surgery

### Resumo

#### Palavras-chave

- ▶ doenças da medula espinal
- ▶ síndrome de Brown-Séguard
- ▶ mielografia
- ▶ ressonância magnética
- ▶ hérnia
- ▶ cirurgia

Idiopathic spinal cord herniation is a rare cause of progressive myelopathy, especially in the absence of a history of spinal or surgical trauma. The radiological diagnosis is made through a myelography or an MRI exam. The spinal cord is pushed anteriorly, buffering the dural defect and leading in most cases to Brown-Séguard syndrome. The present study describes the case of a male patient with a clinical picture of progressive thoracic myelopathy. In the clinical and radiological investigation, an idiopathic spinal cord herniation on the chest level was identified. During the surgery, the spinal cord was reduced to the natural site, taking its usual elliptical shape, and the dural defect was repaired with a dural substitute. The numbness of the patient improved, and the shocks in the lower limbs disappeared. A postoperative MRI confirmed the surgical reduction of the herniation and the restoration of the anterior cerebrospinal fluid (CSF) column to the spinal cord. The authors describe the clinical, radiological, intraoperative, and postoperative evolution.

A herniação medular idiopática é uma causa rara de mielopatia progressiva, especialmente na ausência de história clínica de trauma raquimedular (TRM) ou cirúrgico. O diagnóstico radiológico é feito por meio de mielotomografia ou de ressonância magnética. A medula espinal é deslocada anteriormente, tamponando o defeito dural e levando na maioria dos casos a uma síndrome de Brown-Séguard. O presente estudo descreve o caso de um paciente do sexo masculino com quadro clínico de mielopatia torácica progressiva. Na investigação clínica e radiológica, foi identificada uma herniação medular idiopática ao nível torácico. Durante a cirurgia, a medula espinal foi reduzida ao local natural, tomando sua forma elíptica habitual, e a falha dural foi reparada com um substituto dural. O paciente melhorou da dormência e houve desaparecimento dos choques nos membros inferiores. A ressonância pós-operatória confirmou a redução cirúrgica da herniação e o restabelecimento de coluna líquórica anterior à medula espinal. Os autores descrevem os achados clínicos, radiológicos e intraoperatórios, bem como a evolução pós-operatória.

### Introduction

Idiopathic spinal cord herniation is a rare cause of progressive myelopathy, especially in the absence of trauma in the spinal cord or after a surgical procedure.<sup>1</sup> Most often, the clinical evaluation of the patient shows signs and symptoms

of myelopathy compatible with Brown-Séguard syndrome. The thoracic cord is the most affected, mainly between the levels of the T4 and T7 vertebrae.<sup>2</sup>

The radiological diagnosis is made by magnetic resonance imaging (MRI), which has favored an increase in the diagnosis of spinal cord herniation in recent years. Myelotomography can

received  
October 20, 2015  
accepted  
February 6, 2016  
published online  
April 14, 2016

DOI <https://doi.org/10.1055/s-0036-1581084>.  
ISSN 0103-5355.

Copyright © 2018 by Thieme Revinter Publicações Ltda, Rio de Janeiro, Brazil

License terms



also be used to perform the differential diagnosis. However, its interpretation may be difficult, since the radiological findings may mimic an arachnoid cyst.<sup>3,4</sup>

The pathophysiology of spinal cord herniation comprises an idiopathic anterior dural defect, into which the spinal cord is pushed, blocking the dural defect and leading to a progressive myelopathy as a result of secondary admission, distortion and vascular injury. However, the exact cause of the dural defect remains unknown.<sup>5</sup> There is no consensus in the literature about a diagnostic algorithm and surgical treatment, nor is there any clinical evolution data.

The present study describes the case of a male patient accompanied by the Rede SARA de Hospitais since 2008 with a diagnosis of idiopathic spinal cord herniation in the thoracic segment of the spinal cord. The authors report the clinical, radiological and intraoperative findings, as well as the long-term postoperative evolution.

## Case Report

A 36-year-old male presented a progressive clinical picture of muscle weakness in the right lower limb associated with bilateral shocks and altered sensitivity of a progressive character in the left lower limb. He did not report a history of previous trauma or surgery.

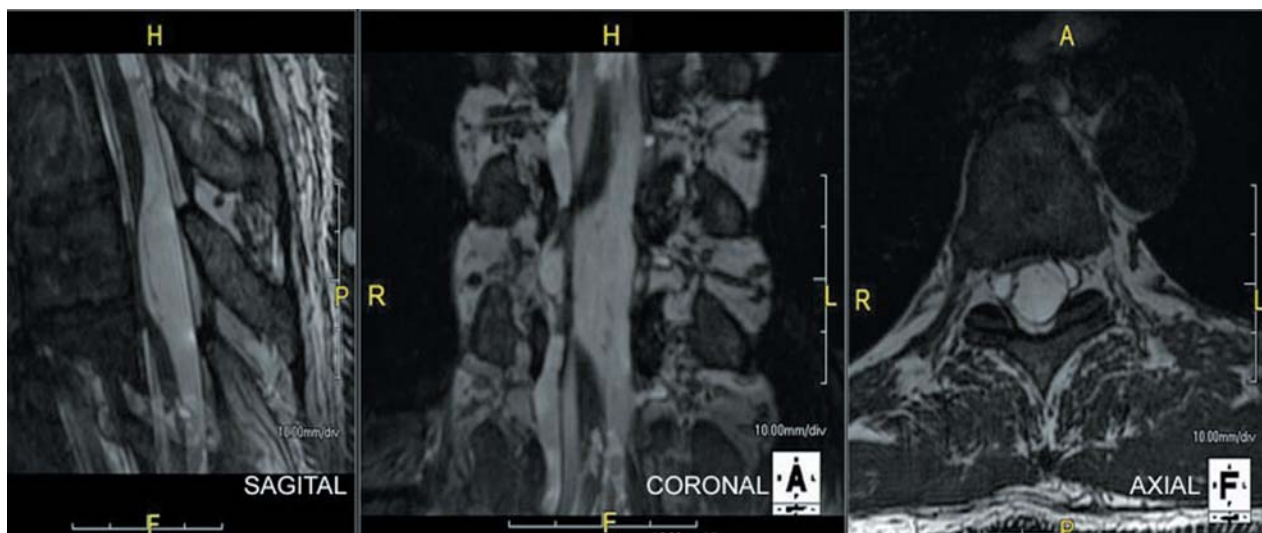
The physical evaluation showed a worsening of muscle strength at the level of the iliopsoas muscles, the gluteus medius, the triceps sural, and the right anterior tibialis. The clinical examination also showed hyperreflexia in the lower limbs and Babinski sign. In addition, the evaluation, performed in the movement laboratory, showed a worsening in the pattern and gait performance, with decreased speed and greater difficulty in passing the right lower limb, associated with reduced muscle strength and increased spasticity. These results were in line with the physical examination data of the patient.

The preoperative MRI (►Fig. 1) showed a thoracic medullary herniation in the T6 plane, confirmed by a myelotomography (►Fig. 2). The two exams showed the output of the spinal cord due to a dural defect. Another important radiological data in the differential diagnosis was the absence of cerebrospinal fluid (CSF) flow anterior to the spinal cord (►Figs. 1 and 2).

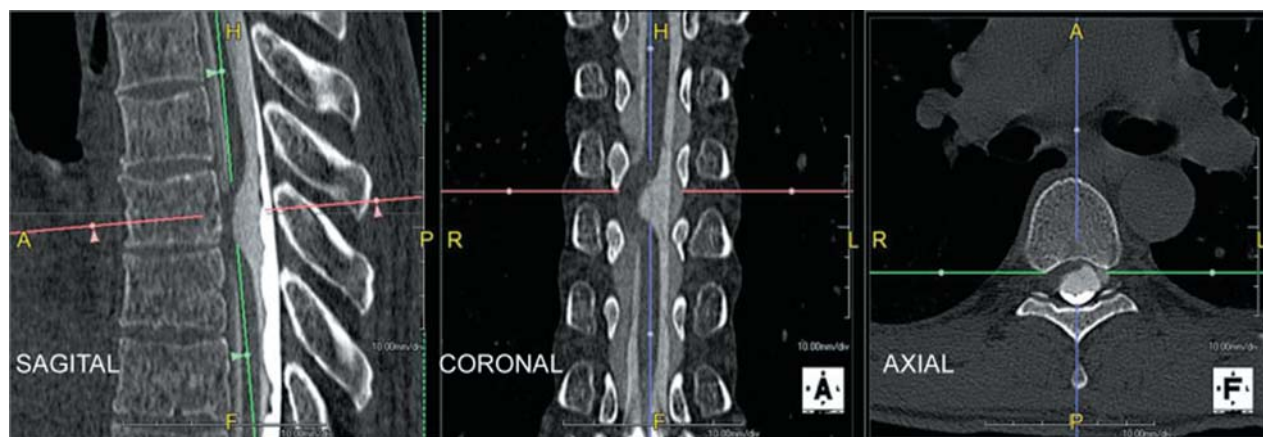
Due to the clinical progression of the myelopathy, surgery was indicated. A thoracic laminectomy of the T5 to the T7 was performed for complete lesion exposure. After the durotomy, the medullary herniation and the foramen of the dura mater were observed. The spinal cord entered through the dural defect (►Fig. 3). Then, under surgical microscope view, the spinal cord was reduced, gently tractioning the dentate ligament, and displaced with Rhoton microsurgery dissectors, to assume the anatomical positioning. The dural defect was repaired with a dural substitute that integrates to the dura mater without the need for surgical stitches. The lamina was replaced, being fixed with miniplates and titanium screws at each level, bilaterally. The surgical procedure was performed under neurophysiological monitoring, using somatosensory and motor evoked potentials as well as the D wave electrode. The evoked potentials remained unchanged during the procedure. The surgery was uneventful, and the patient had good postoperative recovery, being discharged on the 8th day.

## Results

In the late postoperative period, the patient reported an improvement in the numbness and disappearance of the shocks in the lower limbs, associated with a significant improvement in the tactile and pain sensitivity of the left lower limb and in the motricity of the right lower limb. A postoperative MRI confirmed the surgical reduction of the herniation and the reestablishment of the anterior CSF



**Fig. 1** Magnetic resonance imaging examination in sagittal, coronal, and axial views of the ventral herniation of the thoracic medulla through the dural defect. At this level, the spinal cord appears narrowed and deformed, with accumulation of cerebrospinal fluid in the subarachnoid space.



**Fig. 2** Myelotomography examination demonstrating the anterior medullary herniation with deviation to the right side. The test assists in the differential diagnosis of hypertensive arachnoid cyst.

column (→ **Fig. 4**). The imaging examination also demonstrated medullary hypersignal suggestive of gliosis due to a prolonged ischemia. The gait evaluation, performed in the movement laboratory 2 months after the surgical procedure, showed an improvement in the pattern and gait performance associated with improved strength in the right lower limb.

Currently, the patient can easily pass the lower limb right, reducing stumbling and eliminating falls. In addition, there was an improvement in weight bearing on lower limb right, with elimination of pain in the left knee.

## Discussion

Idiopathic spinal cord herniation is a rare clinical condition, increasingly recognized as a cause of progressive myelopa-

thy. However, the natural history of this disease is slow, and for this reason the diagnosis is usually late.

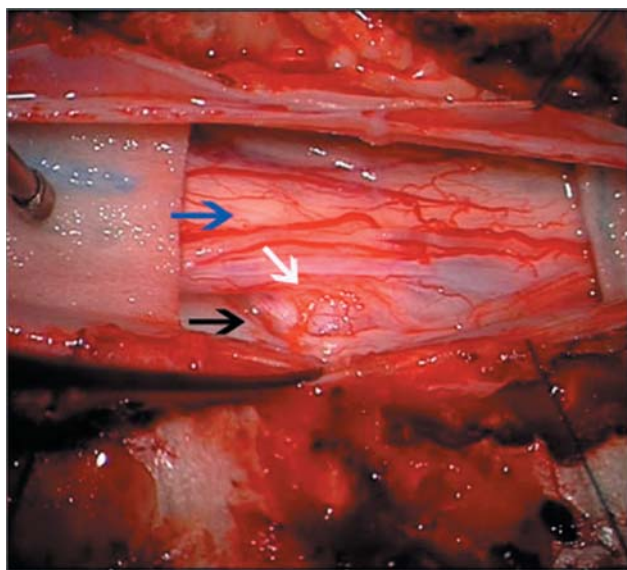
Spinal cord herniation is probably a more frequent cause of myelopathy than what is currently diagnosed.<sup>5,6</sup>

Due to the rarity and the atypical presentation of spinal cord herniation, its diagnosis and treatment may be delayed.<sup>7,8</sup> The presence of a dural defect is the primary pathophysiological factor in the development of this condition, but its etiology remains unknown.<sup>5</sup> This defect in the dura mater can occur at more than one point and cause herniation of two sites.<sup>5</sup> It is believed that the trauma may be related to hernia formation, a fact not shown in this case.<sup>8</sup>

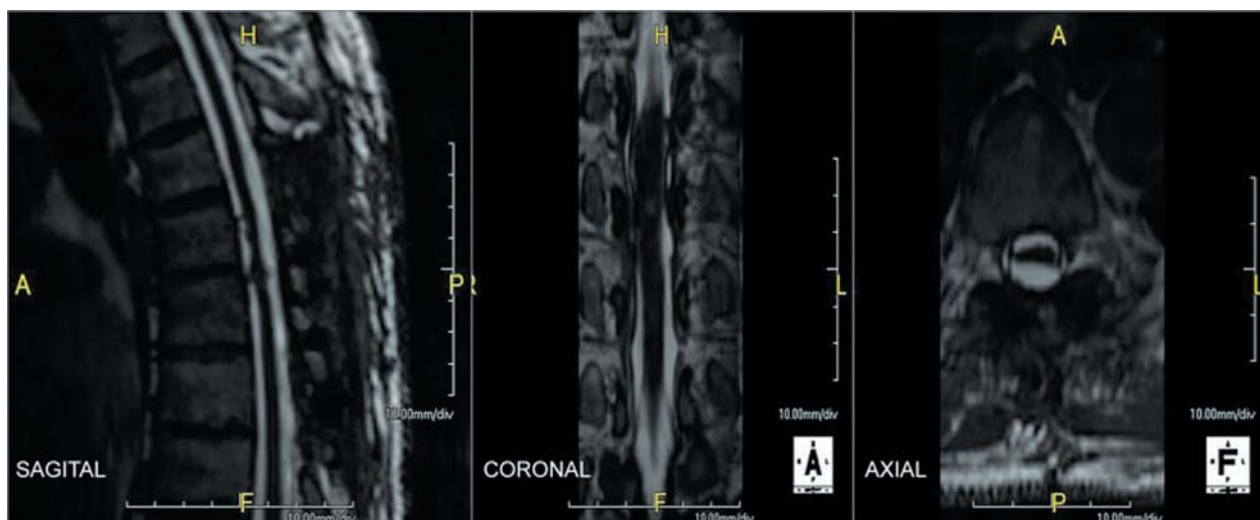
The definitive diagnosis is obtained by imaging examinations.<sup>2-4</sup> Myelography by CT often helps in the diagnosis, which was observed in the present case. The exam of choice for defining herniation is the MRI, and it is possible to observe the output of the spinal cord through the foramen of the dura mater and the lack of CSF.<sup>1,2</sup> Among the differential diagnoses, the arachnoid cyst is radiologically similar.

Most publications on spinal cord herniation are isolated descriptions or series consisting of a few cases.<sup>4-6</sup> Currently, ~200 cases are found in the literature.<sup>9</sup> Surgical treatment is described by several authors as a way to reverse the resulting myelopathy of this clinical condition. Even in patients with long-term neurological deficits, the neurosurgical intervention provides significant functional gains, as was observed in the present case.<sup>10</sup> The direct suture of the dura, when possible, or the interposition of a dura mater anatomy, are techniques used to occlude the orifice of the dura mater and to prevent a new herniation. Despite these descriptions, Samuel et al reported a case of spontaneous resolution without the need for surgery.<sup>11</sup>

The goal of the surgery is to restore the anatomy by undoing the spinal cord herniation. However, the manipulation of the marrow in the dural defect may aggravate the myelopathy by different mechanisms, such as traction of the affected spinal cord tissue or inadvertent coagulation of spinal vessels. For these reasons, if possible, this



**Fig. 3** Intraoperative finding of the spinal cord herniation (white arrow) by dural defect (black arrow), posterior view of the medulla (blue arrow).



**Fig. 4** Control magnetic resonance imaging exam in sagittal, coronal and axial views. The spinal cord is returned to its position after surgery.

traction should be done by the dentate ligament, minimizing the direct manipulation of the spinal cord. D-wave monitoring, which is more sensitive than the somatosensory and motor potentials, increases the surgical safety because at the least sign of additional impairment during the procedure, the stage in question is interrupted to avoid aggravation.

A worsening of the myelopathy is the most feared complication. However, there are other complications associated with worsening kyphosis due to the laminectomy and its replacement reduces this risk. If reoperation is required, the anatomical planes will be more identifiable, minimizing the risk of dural injury. Infection is another common problem with spinal procedures, leading to a discussion in the light of this theme. Of course, in addition to the concerns related to asepsis and antisepsis, the total length of the surgery is often extensive, as is the use of the retractors. It would be convenient, from time to time, to bring about a loosening of the retractors, contributing to the improvement of the circulation in the tissue.

## Conclusion

In the investigation of patients with progressive neurological deficit, idiopathic spinal cord herniation should be considered as one of the differential diagnoses. An early recognition and the appropriate surgical treatment may reverse the clinical course. The present case report aims to emphasize this diagnosis as one of the causes of reversible myelopathy and, with this, to highlight the importance of the early recognition of this condition.

## References

- 1 Brus-Ramer M, Dillon WP. Idiopathic thoracic spinal cord herniation: retrospective analysis supporting a mechanism of diskogenic dural injury and subsequent tamponade. *AJNR Am J Neuroradiol* 2012;33(01):52–56
- 2 Parmar H, Park P, Brahma B, Gandhi D. Imaging of idiopathic spinal cord herniation. *Radiographics* 2008;28(02):511–518
- 3 Imagama S, Matsuyama Y, Sakai Y, et al. Image classification of idiopathic spinal cord herniation based on symptom severity and surgical outcome: a multicenter study. *J Neurosurg Spine* 2009;11(03):310–319
- 4 Karadeniz-Bilgili MY, Castillo M, Bernard E. Transdural spinal cord herniation: pre- and postoperative MRI findings. *Clin Imaging* 2005;29(04):288–290
- 5 Aydin AL, Sasani M, Erhan B, Sasani H, Ozcan S, Ozer AF. Idiopathic spinal cord herniation at two separate zones of the thoracic spine: the first reported case and literature review. *Spine J* 2011;11(08):e9–e14
- 6 Berg-Johnsen J, Ilstad E, Kolstad F, Züchner M, Sundseth J. Idiopathic ventral spinal cord herniation: an increasingly recognized cause of thoracic myelopathy. *J Cent Nerv Syst Dis* 2014;6(06):85–91
- 7 Saito T, Anamizu Y, Nakamura K, Seichi A. Case of idiopathic thoracic spinal cord herniation with a chronic history: a case report and review of the literature. *J Orthop Sci* 2004;9(01):94–98
- 8 White BD, Tsegaye M. Idiopathic anterior spinal cord hernia: under-recognized cause of thoracic myelopathy. *Br J Neurosurg* 2004;18(03):246–249
- 9 Hawasli AH, Ray WZ, Wright NM. Symptomatic thoracic spinal cord herniation: case series and technical report. *Neurosurgery* 2014;10(3, Suppl 3):E498–E504, discussion E504
- 10 Miyaguchi M, Nakamura H, Shakudo M, Inoue Y, Yamano Y. Idiopathic spinal cord herniation associated with intervertebral disc extrusion: a case report and review of the literature. *Spine* 2001;26(09):1090–1094
- 11 Samuel N, Goldstein CL, Santaguada C, Fehlings MG. Spontaneous resolution of idiopathic thoracic spinal cord herniation: case report. *J Neurosurg Spine* 2015;23(03):306–308