

Diode Laser for Laryngeal Surgery: a Systematic Review

Helena Hotz Arroyo¹ Larissa Neri¹ Carina Yuri Fussuma¹ Rui Imamura¹

¹Department of Otorhinolaryngology, Hospital das Clínicas, School of Medicine, Universidade de São Paulo, São Paulo, Brazil

Address for correspondence Helena Hotz Arroyo, MD, Universidade de São Paulo, Avenida Doutor Eneas de Carvalho Aguiar 155, 6o andar sala 6167, Sao Paulo, Brazil (e-mail: helenaharroyo@hotmail.com).

Int Arch Otorhinolaryngol 2016;20:172–179.

Abstract

Introduction The diode laser has been frequently used in the management of laryngeal disorders. The portability and functional diversity of this tool make it a reasonable alternative to conventional lasers. However, whether diode laser has been applied in transoral laser microsurgery, the ideal parameters, outcomes, and adverse effects remain unclear.

Objective The main objective of this systematic review is to provide a reliable evaluation of the use of diode laser in laryngeal diseases, trying to clarify its ideal parameters in the larynx, as well as its outcomes and complications.

Data Synthesis We included eleven studies in the final analysis. From the included articles, we collected data on patient and lesion characteristics, treatment (diode laser's parameters used in surgery), and outcomes related to the laser surgery performed. Only two studies were prospective and there were no randomized controlled trials. Most of the evidence suggests that the diode laser can be a useful tool for treatment of different pathologies in the larynx. In this sense, the parameters must be set depending on the goal (vaporization, section, or coagulation) and the clinical problem.

Conclusion: The literature lacks studies on the ideal parameters of the diode laser in laryngeal surgery. The available data indicate that diode laser is a useful tool that should be considered in laryngeal surgeries. Thus, large, well-designed studies correlated with diode compared with other lasers are needed to better estimate its effects.

Keywords

- diode laser
- larynx
- vocal fold
- glottis
- laryngeal neoplasms

Introduction

Lasers have been used in laryngeal surgeries since 1972, when Strong and Jako first reported the use of carbon dioxide laser (CO₂) in the human larynx.¹ Despite initial criticism, endoscopic laser treatments have achieved universal acceptance and been successfully used in endolaryngeal microsurgery (EMS).² Most of the laser procedures involve either excision or tissue vaporization, depending on the interaction between the wavelength (λ) and the chromophores of the tissue. For years, the CO₂ (λ = 10600 nm) seemed to be the preferred laser for transoral laser microsurgery due to its

precise cut,³ given that it is better absorbed by water. However, there are some disadvantages of the CO₂ device, namely, its straight line beam delivery from surgical microscope, narrow penetration depth to tissue, difficult transportation, and increased cost. These drawbacks favored the study and application of other wavelengths in larynx, such as Thulium YAG (λ = 2000 nm), Nd:YAG (neodimium:yttrium-aluminum-garnet - λ = 1064 nm), diode (λ = 805 - 980 nm), PDL (pulsed dye laser - λ = 585 nm) and KTP (potassium titanyl phosphate - λ = 532 nm).^{3,4}

The diode laser has excellent hemostatic properties as a result of high absorption by hemoglobin and particularly by

received
October 6, 2015
accepted
December 11, 2015
published online
March 4, 2016

DOI <http://dx.doi.org/10.1055/s-0036-1579741>.
ISSN 1809-9777.

Copyright © 2016 by Thieme Publicações Ltda, Rio de Janeiro, Brazil

License terms



oxyhemoglobin. It is also absorbed by water, but less so than the CO₂ laser.⁵ Furthermore it is portable, small, relatively inexpensive, and simple to use. It also has stable power output, long lifetime, and low installation and maintenance costs.^{2,6} Moreover, the diode laser is delivered down by a fine glass fiber that allows the surgeon to hold it in a pencil-like holder for accurate manipulation.² The fiber guidance system tip can be angled, which allows access to areas that are difficult to handle with the CO₂ laser.⁷ As a result, the use of diode laser in EMS has increased in recent years.⁸ Nonetheless, the ideal parameters of diode laser in EMS and long-term results remain unclear. Therefore, we conducted a systematic review to clarify the use of diode laser in laryngeal diseases and outcomes shown so far.

Methods

A systematic search was performed in PubMed, Cochrane Library, Ovid, Web of Science, and Scielo databases. Search terms and Boolean operators used were “larynx” OR “glottic” OR “airway” OR “laryngeal surgery” OR “vocal fold” AND “diode laser.” We only included publications in English or Spanish languages. The final search was performed on September 28th, 2015. We screened titles and abstracts for relevance and relevant articles for assessment. Reference lists were manually searched for further relevant articles.

We considered all studies relating to human laryngeal pathologies (from superior edge of epiglottis to inferior edge of cricoid cartilage). We only included studies that provided information on patient and lesion characteristics, treatment (diode laser’s parameters used in surgery – at least two items described among wavelength, fiber diameter, output power, frequency, wave radiation, and contact mode), and outcomes related to the laser surgery performed. Outcomes could be “cure of the initial pathology,” “need of complementary operation,” “recurrence of the lesion,” or even “complications or adverse/side effects.” Studies were excluded if they consisted of less than two subjects or case report. Patients with tracheal disease were not included. Finally, studies that described the use of diode laser with non-surgical intent were excluded.

We collated data from included studies using an Excel (Microsoft, Redmond, Washington) spreadsheet. Specifically, data on sample demographics and clinical characteristics, sample size, diode laser parameters used, duration of follow-up, main outcome findings, and complications were extracted from each study. Article authors were contacted directly to obtain further information in cases of incomplete reported data.

The internal validity of included studies was low overall. We identified no randomized clinical trial and only two experimental controlled studies (not randomized) were included.

Results

Our search strategy yielded a total of 284 articles (including duplicates). By screening the titles alone, 234 articles could be excluded, as they were either review articles, obviously not relating to the use of diode laser in larynx, or clearly not

eligible for inclusion (for example, studies looking at diode laser in animals). This left 50 abstracts, of which 36 were duplicate. After reading the abstracts, one was removed due to its focus on endobronchial diseases. Then, the 13 eligible articles were full-text assessed, but two more were excluded due to failure to meet eligibility criteria (one that did not describe the laser parameters used at one single surgery and another that included patients with lesions outside the larynx). This left 11 articles appropriate for inclusion in the review. We manually searched reference lists for further relevant articles, but none was eligible (► Fig. 1).

The 11 studies selected for inclusion were published between 2003 and 2014 and originated from 5 different countries. Two studies were experimental controlled but not randomized^{8,9} and another one was a prospective experimental uncontrolled study.⁷ The other studies comprised of 8 retrospective reviews.^{2,3,5,6,10–13} We found no randomized controlled trial or multicenter trials.

A total of 357 subjects made up the study population from the 11 included studies. The average number of participants per study was 32.45 (range: 8–72). ►Table 1 details the characteristics of the study population. The laryngeal pathologies included were supraglottic granuloma, laryngomalacia, ventricular dysphonia, vocal polyp, glottic web, papillomas, glottic carcinoma, bilateral cord palsy, subglottic cysts, subglottic stenosis, and subglottic hemangioma/lymfangioma.

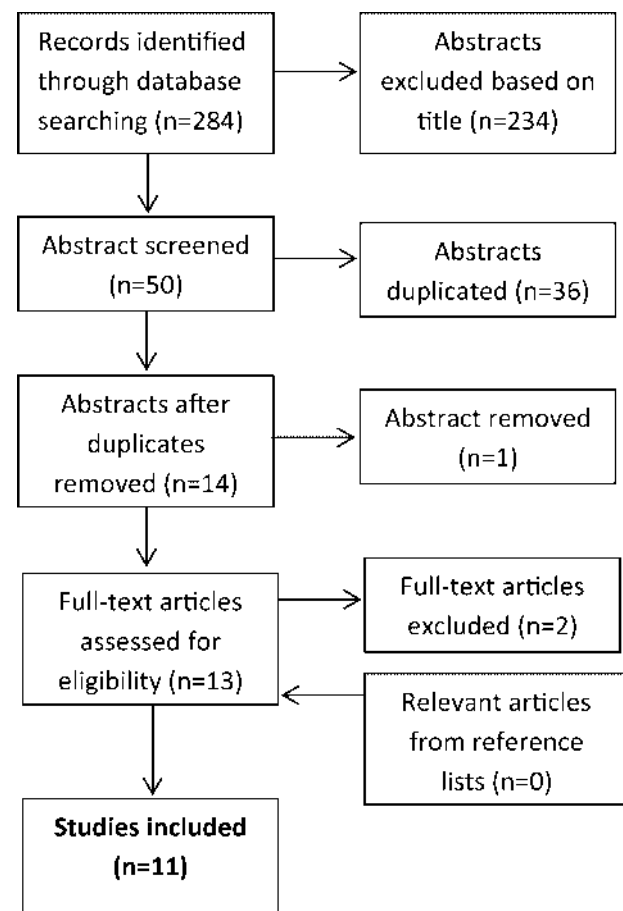


Fig. 1 Diagram of eligibility criteria.

Table 1 Population characteristics for included studies

Study	Year	Country	No. of patients	Sex		Age		Type of Laryngeal Disease										
				F	M	Range	Mean	Suprastomal granuloma	Laryngo malacia	Ventricular dysphonia	Vocal polyp	Glottic web	Papillomas	Glottic carcinoma	Bilateral cord palsy	Subglottic cysts	Subglottic stenosis	Subglottic hemangioma / lymphangioma
Saetti et al	2003	Italy	39	-	-	-	-	0	0	0	0	0	0	0	39	0	0	0
Ferri et al	2006	Italy	18	3	15	35-84y	59	0	0	0	0	0	0	18	0	0	0	0
Saetti et al	2008	Italy	27	-	-	-	-	0	0	0	0	0	0	0	0	0	0	27
Bajaj et al	2008	UK	31*	-	-	1m-16y	-	5	1	0	1	6	6	3	4	16	0	0
Fanjul et al	2008	Spain	21**	11	11	1m-13y	year11m	3	5	0	0	0	0	1	3	3	6	0
Ferri et al	2008	Italy	45	6	39	35-81y	51y	0	0	0	0	0	0	45	0	0	0	0
Edizer et al	2013	Turkey	58	7	51	42-78y	60.43y	0	0	0	0	0	0	58	0	0	0	0
Liu et al	2013	Taiwan	8	1	7	24-83y	48.8y	0	0	8	0	0	0	0	0	0	0	0
Tunçel et al	2013	Turkey	64	3	61	35-69y	52y	0	0	0	0	0	0	64	0	0	0	0
Karasu et al	2014	Turkey	26	10	16	28-61y	49.96y	0	0	0	26	0	0	0	0	0	0	0
Cömert et al	2014	Turkey	72	-	-	31-75y	51.8	0	0	0	0	0	0	72	0	0	0	0
Total	-	-	357	-	-	-	-	8	6	8	27	6	6	239	61	7	19	33

* There was more than one laryngeal pathology in many patients. ** One patient data excluded (tracheal stenosis).

- = data not available.

Abbreviations: m, months; y, years F = female M = male.

Intervention included diode laser surgery performed in various combinations of parameters between wavelength, fiber diameter, output power, frequency, wave radiation and contact mode, as illustrated in ►Table 2. The preferred wavelength changed from 810 nm to 980 nm since 2013. The minor fiber diameter described was 300 µm and the isolated major one was 1400 µm. The output power varied from 3 W to 60 W. All authors with available data opted for the direct contact of the fiber to the tissue as well as the continuous mode of energy.

Length of follow-up was variable among the studies, ranging from two to 86 months. A summary of the main findings of each study is illustrated in ►Table 3.

Five of 11 authors (46%) declared to have experienced no complications or side effects by the use of the diode laser. Granulation and posterior synechia were described related to treatment of vocal fold paralysis.¹⁰ Tracheal posterolateral bridge synechia and laser-induced subglottic granuloma related to treatment of subglottic hemangioma/lymfangioma.⁵ Regarding glottic cancer surgeries, no authors reported edema requiring tracheostomy. Intraoperatively, thyroid cartilage exposure was described and laser-induced fire occurred due to thermal injury of the laser on the intubation tube. Two patients developed cutaneous emphysema that resolved in one day without intervention.¹² In the postoperative period, synechia and granuloma formation was reported.⁷ Some rare side effects were infection, foul smelling halitosis (in whom relatively more extended laser surgery was performed), laryngeal stenosis,¹² hemorrhage, and fistula formation.⁷

Discussion

Carbon dioxide laser has been predominantly used since the introduction of laser surgery. However, it has some limitations, such as increased cost and difficulty in the management of deep and curved areas. In addition, it has short penetration in tissues (0.1–0.3 mm on average), which reduces effective sealing of vessels (it coagulates vessels of calibers smaller than 0.5 mm), thus, increasing bleeding during surgery.^{3,4} The diode laser emits wavelengths that are absorbed predominantly by hemoglobin and melanin (near infrared spectrum). The penetration depth depends on the concentration of these chromophores and, generally, it reaches 0.3–1.0 mm in diode laser application, which makes it ideal for photocoagulation.^{4,6,14} In conformity to that, some authors advocate that the diode laser ~3–5W allows thermal coagulation that had been unimaginable with the CO₂ laser.¹⁰ All of these characteristics, according to some authors, confer on diode laser a surgical precision only slightly inferior to the CO₂ laser one, but with a superior coagulation capability for treating laryngeal vascular lesions.⁵ Compared with other devices, diode laser also appears to be more precise and less invasive. For instance, the cutting precision of the NdYAG (1064 nm) is considerably lower, and the instrument also led to greater immediate and deferred inflammatory damage due to thermal diffusion (high penetration capacity of up to 4 mm).^{3,10}

Furthermore, the diode laser's beam, in contrast to the carbon dioxide laser, is carried by flexible optic fibers that can

Table 2 Intervention treatment - parameters of diode laser in larynx

Study	Year	No. of patients	Parameters					
			Wavelength (nm)	Fiber diameter (μm)	Output power (W)	Frequency (Hz)	Wave Radiation	Contact Mode
Saetti et al	2003	39	810	300–600	10	–	–	Direct contact
Ferri et al	2006	18	810	600	10	–	Continuous	Direct contact
Saetti et al	2008	27	810	300–600	5–8	–	Continuous/Low frequency pulsation	–
Bajaj et al	2008	31	805	400	3–5	–	Continuous	Direct contact
Fanjul et al	2008	21	820 + 20	400–600	10–15	–	–	Direct contact
Ferri et al	2008	45	810	600–1000	5–60 (mean 30)	60 Hz	Continuous	Direct contact
Edizer et al	2013	58	–	–	6–12	–	Continuous	–
Liu et al	2013	8	810	1400	max 5	–	Continuous	–
Tunçel et al	2013	64	980	400	4–9	–	Continuous	Direct contact
Karasu et al	2014	26	980	400	3–5	–	Continuous	Direct contact
Cömert et al	2014	72	980	400	4–9	–	Continuous	Direct contact

–= data not available.

be coupled with telescopes permitting access to sites that are difficult to explore with other techniques, such as the subglottic region.⁵ Recently, a CO₂ laser beam delivered through a flexible hollow tube has become available that delivers the beam close to the target.¹⁵ However, the use of diode laser by contact (or extremely close distance) makes it much safer than other laser sources by avoiding damage due to “beam scape” in an open field.⁵

As this review shows, the diode laser can be a useful tool for treatment of different laryngeal pathologies, such as supraglottic granuloma, laryngomalacia, ventricular dysphonia, vocal polyp, glottic web, papilloma, glottic carcinoma, bilateral cord palsy, subglottic cyst, subglottic stenosis, subglottic hemangioma and lymphangioma. In this sense, the laser parameters must be set depending on the goal (vaporization, section or coagulation) and the clinical problem.

With respect to output power, diameter of fiber and wavelength, the articles selected in this review presented different arrangements for diode laser. This reveals the lack of standardization in setting the best parameters of diode laser for laryngeal surgery. Although these parameters may influence collateral tissue damage, the studies are difficult to compare, based on the following concepts of laser's physics. Power, given in watts (W), measures the rate that the laser beam transmits. Beam energy, measured in joules (J), can be found by multiplying the power (W) by exposure time (in seconds). Power density, also called irradiance or spot brightness, determines the rate at which tissue is removed at the surgical site, measured in units of watts per square centimeter (W/cm²). Fluence is a key parameter once it combines previously mentioned parameters of power density and dosage, and is measured in units of joules per square centimeter (J/cm²). It is important to understand this to provide minimal damage to tissues adjacent to the incision site, as

using a higher pulse power for a shorter period of time results in less tissue damage than using lower power for a longer period of time. Tissue damage is dependent upon the tissue absorption coefficient, the wavelength of the laser, power density, and the length of time over which the energy is delivered, which is largely technique dependent.¹⁶ These data were not provided by any of the included studies.

An additional property that can affect the severity of tissue damage is thermal relaxation time, the time required for tissue to lose 50% of its heat through diffusion.¹⁷ One can decrease tissue damage by allowing heated tissue to cool during a procedure. However, it could be accomplished through the use of a pulsed laser, spacing out laser impact, even for a continuous incision, that decreases thermal damage by allowing time for the tissue to cool between impacts.¹⁶ In contrast, the authors of studies included in this review opted for the continuous wave radiation, some followed by manual tissue cooling.

Special attention must be given to laser surgery for the treatment of glottic cancer, once it can be more cost-effective than ‘cold surgery’ when managing laryngeal tumors, as they allow briefer hospital stays and shorter wound recovery periods.¹⁸ The CO₂ laser surgery was presented as one of the most accepted treatment options of early glottic carcinoma due to its high local control rates, low morbidity, and good postoperative voice quality.¹⁹ However, if the surgeon has difficulty in managing laryngeal anterior commissure tumors, he or she is encouraged by some authors to avoid CO₂ laser microsurgery. Alternatively, the 810 nm diode laser has been recently used for the treatment of glottic tumors and may allow better exposure and resection of tumors in the anterior commissure. The first to establish long-term results for glottic cancer treatment were Ferri et al, in 2008. However, it seems that diode laser has not been well accepted worldwide for

Table 3 Main outcome findings

Study	Year	Follow-up Range (Mean)	Type of laryngeal disease	Main outcome findings	Complications
Saetti et al	2003	(6m)	bilateral vocal cord palsy	Good (no exertional dyspnea after physical effort), sufficient (no resting dyspnea and normal everyday activity) results, and decannulation of previously tracheotomised patients were obtained from all patients after one or two procedures.	No significant intraoperative complications occurred. The only complications observed, in the post-operative period, were 3 cases of granulation, which was removed on an outpatient basis, and 1 case of posterior synechia that required no further treatment.
Ferri et al	2006	(20m)	bilateral vocal cord palsy	The improvement in respiratory function was evident already between the first hours, stabilizing on the first week. By the second day, all patients could eat without aspiration. The nine patients with tracheostomy cannula previous from the endoscopic surgery were decannulated in a maximum of sixty days after surgery.	None
Saetti et al	2008	–	Subglottic heman-gioma / lymphangioma	Diode laser was the primary treatment in 22 patients, showing a success rate of 95% (21 of 22). One children experienced a recurrence of stridor after systemic steroids therapy and required diode laser vaporization. The same secondary laser treatment was used in 2 cases in which a progression of the tumor with worsening of respiratory symptoms was recorded notwithstanding steroid treatment. Other 2 patients that underwent intrale-sional corticosteroid injection underwent secondary laser treatment.	No early complications (intra-operative or postoperative bleeding). One tracheal posterolateral bridge synechia (resolved after treatment with a diode laser section); and one laser-induced subglottic granuloma - successfully removed by means of videoscopic forceps.
Bajaj ey al	2008	6m - 3y	Mainly subglottic stenosis, but included various (8) diagnosis	19/31 (61.3%) patients have been cured of their initial pathologies and were not under further review. Another 9/31 (29.0%) had to undergo different operations. The remaining 3/31 (9.6%) (all three recurrent respiratory papillomato-sis) are undergoing repeated laser and other adjuvant treatments.	None
Fanjul et al	2008	–	Various (5) diagnosis	The saccular lesions, mucous membranes, granulomas and arytenoid abnormalities resolved by the exclusive application of laser (78.6% with a single procedure). In other situations, such as vascular anomalies (hemangiomas and lymphangiomas) and subglottic stenosis, we have pointed to other treatments (surgical and medical in 87.5% and 12.5% respectively) for resolution.	None

Table 3 (Continued)

Study	Year	Follow-up Range (Mean)	Type of laryngeal disease	Main outcome findings	Complications
Ferri et al	2008	24–86m (36m)	Glottic carcinoma	There were 5 recurrences (11.1%): 4 local (8.9%), in which 3 were salvaged, and 1 (2.2%) regional (N2a). Three patients (6.7%) developed second primary cancers on the opposite cord after a mean of 18 months (range, 9–47 months) (1 was salvaged with total laryngectomy, 1 with repeat laser surgery and RT, 1 with partial laryngectomy with open surgery).	No major complications were observed. The development of small granulomas was uncommon (6.6%) and they usually resorbed within a few weeks without any further surgery.
Edizer et al	2013	24–48m (35.3m)	Glottic carcinoma	The involvement of the anterior-commissure was present in 13 (22%) of the patients. During the follow-up period, in 8 of these patients, granulation tissue or synechia developed at the anterior part of the larynx. Local recurrence was encountered in 5 (8%) patients (1 case with T1a, 3 with T2 and one patient with T3 primary tumor at the initial presentation).	Thyroid cartilage exposure in 1 patient. Intraoperative laser-induced fire occurred due to thermal injury of the laser on the intubation tube in 1 patient. Two patients developed cutaneous emphysema which resolved in one day without intervention. In the postoperative period, infection and foul smelling halitosis developed in 5 patients in whom relatively more extended laser surgery was performed. Laryngeal stenosis was seen in 2 patients.
Liu et al	2013	13–58 m (40.8m)	Ventricular dysphonia	No neo-growth of false folds was noted. (OBS: the role of diode laser was not improving the vocal quality but offering better visualization of true vocal behavior).	None
Tunçel et al	2013	15–32m (20.4m)	Glottic carcinoma	Local control and larynx preservation rates were 93.8% and 100%, respectively. There were 4 recurrences (6.2%), all within the first 15 months after treatment (range, 10–15 months).	Fistula formation (1.5%), hemorrhage (1.5%), and massive recurrent granuloma formation (1.5%) were the main complications. Minor complications, including synechia and granuloma, were seen in 20.2% of the patients. Four (6.2%) patients had synechia, and 25% of these patients needed surgical treatment. Nine (14%) patients had mild granuloma formation. Almost all complications were related to anterior commissure surgery.
Karasu et al	2014	2m	Vocal polyp	Postoperatively, in terms of voice handicap index and voice analyses, no statistically significant differences were found between the diode laser group and cold knife group and both improved significantly from baseline measurement ($p < 0.001$)	None
Cömert et al	2014	12–37m (29.3m)	Glottic carcinoma	Initial control of the primary lesions was achieved in 97.4% ($n = 38$) for T1 and 87.8% ($n = 29$) for T2 patients.	5 patients (6.9%) developed a locoregional recurrence.

Abbreviations: m, months; y, years.

laryngeal surgery, as our review shows a gap of publications between 2008 and 2013. According to that, we speculate that most institutions continued using the CO₂ laser, due to doctors' familiarity with its use, capabilities, and limitations.^{9,16} On the other hand, the 980 nm diode laser is a new technology, and has been reported for the treatment of early glottic tumors and vocal fold polyps since 2013.^{7–9} The main difference between these two diode laser wavelengths is their distinct absorption by the vocal fold, as the 980 nm is slightly more absorbed by water than the 810 nm one. The three studies that used the 980 nm diode laser were among those with a better design in our review. Two referred to controlled trials^{8,9} and the other was an uncontrolled trial.⁷ These studies showed good efficacy results and low rates of major complications.

Concerning functional outcomes, as measured by the voice handicap index (VHI), Karasu et al showed good results of 980 nm diode laser in treating vocal fold polyps.⁸ A comparison between diode and CO₂ laser could be quite useful to

highlight the differences and compare the results, especially the functional ones. The ideal comparison to assess both types of lasers would involve a randomized clinical trial with these two techniques, which is nonexistent in the literature. Even though the comparison of non-controlled studies of two different techniques can involve bias, in ▶ **Table 4** we show some results of some authoritative works related to the use of CO₂ laser for larynx surgery in the literature in similar conditions to those with diode laser on our review, so that the reader can grossly compare with ▶ **Table 3**.^{17,20–23}

Regarding safety issues, five authors reported no complications or side effects by the use of the diode laser, but none of these studies was related to glottic cancer or extensive procedures. The major complications were related to more extensive surgeries and with anterior commissure involvement.⁷ Possibly the most feared complication is the endotracheal tube airway fire, which can be catastrophic or even fatal.²⁴ To avoid that, some authors use reinforced tubes for laser surgery⁶ while others described the tube being inflated

Table 4 Results of comparable studies of CO₂ laser in larynx surgery

Study / Country	Year	Follow-up Range (Mean)	Type of laryngeal disease	No. of patients	Main outcome findings	Complications
Bajaj et al / UK	2009	3m–4y (28m)	Bilateral vocal cord palsy	9	None of the patients required post-operative tracheostomy, and all three patients with a previous tracheostomy were successfully decannulated within one month of their operation.	There was a single complication in this study group, in a patient who developed breathing difficulty 48 hours after the procedure and had to be readmitted. He improved with antibiotics and steroids, and was observed for any worsening of dyspnea for six days in hospital.
Özdemir et al / Turkey	2013	4–120m (40m)	Bilateral vocal cord palsy	66	For 58 patients (88%), airway restoration was maintained by performing a successful 1-step surgical procedure, 7 patients (11%) had vocal edema in the postoperative hospitalization period. Medical treatment with oral corticosteroids corrected edema in 3 patients.	Tracheotomy was performed on 4 (6%) patients postoperatively because of dyspnea caused by vocal edema; 12 patients (18%) required a second operation, including the 4 who underwent postoperative tracheotomies. Four patients (6%) required a revision procedure because of shortness of breath caused by granulomas on the operated-on side. In addition, 4 patients (6%) underwent contralateral posterior cordotomy because of an insufficient airway in a second operation.
Bitar et al / USA	2005	12–69m (33m)	Subglottic hemangioma	81	Thirty-six patients receiving CO ₂ laser combined with systemic corticosteroids had 80.6% success rate.	Complications in all patients receiving CO ₂ laser included subglottic stenosis (5.5%), web formation, pneumothorax, and interarytenoid scarring. Used on 58 tracheotomized patients, the CO ₂ laser resulted in a decrease in the mean cannulation duration from 21 to 7.3 months.
Canis et al / Germany	2015	0.03–236.3m (78.2m)	Glottic cancer	404	Recurrence developed in 56 patients (14.4%). Site of recurrence was local in 50 patients and locoregional in 6 patients. Nineteen patients experienced a second and 7 patients a third recurrence. A total laryngectomy was required in 11 patients for salvage after primary laser microsurgical resection.	The overall complication rate was 1% (4 of 404) and included airway obstruction in 2 patients (0.5%), which were successfully treated with corticosteroids and postoperative bleeding that required microlaryngoscopic electrocoagulation in 2 patients (0.5%). Sixty-six patients (15.1%) underwent a second microlaryngoscopy for removal of granulation tissue. No patient needed a tracheostomy or nasogastric feeding tube.
Benninger / USA	2000	5–12 w	Benign lesions	37	Significant improvements in videostroboscopic parameters were found over time.	None

Abbreviations: m, months; y, years.

using saline with methylene blue dye, so that a puncture could be immediately diagnosed.⁷

This review highlights the lack of good evidence for the use of diode laser in laryngeal surgery. Furthermore, it is clear that there is wide variation in how it is used around the world. The 980 nm diode laser seems to be a promising laser device, so we would expect that, as experience increases, it will be more extensively used as well as new lasers wavelengths can emerge.⁸

Final Comments

Despite the heterogeneous populations, varied inclusion criteria, and retrospective designs of most the studies considered in this review, they do provide useful information to the surgeon who intends to use diode laser for transoral laser microsurgery. The evidence from recent studies suggests an improvement in diode laser technology (especially the 980 nm wavelength). Further long-term multicenter prospective research is needed, although the findings of this review suggest that diode laser is a useful tool that should be considered in laryngeal surgeries.

References

- Strong MS, Jako GJ. Laser surgery in the larynx. Early clinical experience with continuous CO₂ laser. *Ann Otol Rhinol Laryngol* 1972;81(6):791–798
- Bajaj Y, Pegg D, Gunasekaran S, Knight LC. Diode laser for paediatric airway procedures: a useful tool. *Int J Clin Pract* 2010;64(1):51–54
- Fanjul M, García-Casillas MA, Parente A, et al. Utilización del láser diodo en la vía aérea pediátrica. *Cir Pediatr* 2008;21(2):79–83
- Vilaseca I, Bernal-Sprekelsen M, Luis Blanch J. Transoral laser microsurgery for T3 laryngeal tumors: Prognostic factors. *Head Neck* 2010;32(7):929–938
- Saetti R, Silvestrini M, Cutrone C, Narne S. Treatment of congenital subglottic hemangiomas: our experience compared with reports in the literature. *Arch Otolaryngol Head Neck Surg* 2008;134(8):848–851
- Ferri E, Armato E. Diode laser microsurgery for treatment of Tis and T1 glottic carcinomas. *Am J Otolaryngol* 2008;29(2):101–105
- Tunçel U, Cömert E. Preliminary results of diode laser surgery for early glottic cancer. *Otolaryngol Head Neck Surg* 2013;149(3):445–450
- Karasu MF, Gundogdu R, Cagli S, et al. Comparison of effects on voice of diode laser and cold knife microlaryngology techniques for vocal fold polyps. *J Voice* 2014;28(3):387–392
- Cömert E, Tunçel Ü, Dizman A, Güney YY. Comparison of early oncological results of diode laser surgery with radiotherapy for early glottic carcinoma. *Otolaryngol Head Neck Surg* 2014;150(5):818–823
- Saetti R, Silvestrini M, Galiotto M, Derosas F, Narne S. Contact laser surgery in treatment of vocal fold paralysis. *Acta Otorhinolaryngol Ital* 2003;23(1):33–37
- Ferri E, García Purriños FJ. [Diode laser surgery in the endoscopic treatment of laryngeal paralysis]. *Acta Otorrinolaringol Esp* 2006;57(6):270–274
- Edizer DT, Cansız H. Transoral Laser Microsurgery for Glottic Cancers - Complications and Importance of the Anterior Commissure Involvement. *Istanbul Med J*. 2013;14:12–15
- Liu S-C, Lin D-S, Su W-F. The role of diode laser in the treatment of ventricular dysphonia. *J Voice* 2013;27(2):250–254
- Sullins KE. Diode laser and endoscopic laser surgery. *Vet Clin North Am Small Anim Pract* 2002;32(3):639–648, vii vii
- Rubinstein M, Armstrong WB. Transoral laser microsurgery for laryngeal cancer: a primer and review of laser dosimetry. *Lasers Med Sci* 2011;26(1):113–124
- Yan Y, Olszewski AE, Hoffman MR, et al. Use of lasers in laryngeal surgery. *J Voice* 2010;24(1):102–109
- Benninger MS. Microdissection or microspot CO₂ laser for limited vocal fold benign lesions: a prospective randomized trial. *Laryngoscope* 2000;110(2 Pt 2, Suppl 92):1–17
- Xu W, Han D, Hou L, Zhang L, Yu Z, Huang Z. Voice function following CO₂ laser microsurgery for precancerous and early-stage glottic carcinoma. *Acta Otolaryngol* 2007;127(6):637–641
- Lucioni M, Marioni G, Bertolin A, Giacomelli L, Rizzotto G. Glottic laser surgery: outcomes according to 2007 ELS classification. *Eur Arch Otorhinolaryngol* 2011;268(12):1771–1778
- Bajaj Y, Sethi N, Shayah A, et al. Vocal fold paralysis: role of bilateral transverse cordotomy. *J Laryngol Otol* 2009;123(12):1348–1351
- Özdemir S, Tuncer Ü, Tarkan Ö, Kara K, Sürmelioğlu Ö. Carbon dioxide laser endoscopic posterior cordotomy technique for bilateral abductor vocal cord paralysis: a 15-year experience. *JAMA Otolaryngol Head Neck Surg* 2013;139(4):401–404
- Bitar MA, Moukarbel RV, Zalzal GH. Management of congenital subglottic hemangioma: trends and success over the past 17 years. *Otolaryngol Head Neck Surg* 2005;132(2):226–231
- Canis M, Ihler F, Martin A, Matthias C, Steiner W. Transoral laser microsurgery for T1a glottic cancer: review of 404 cases. *Head Neck* 2015;37(6):889–895
- Dhar P, Malik A. Anesthesia for laser surgery in ENT and the various ventilatory techniques. *Trends Anaesth Crit Care*. 2011;1:60–66