

Clinical Curiosity: Transnasal Head Trauma Caused by a Toilet Paper Holder

Olaf Süß¹ Frank Bode²

¹Spine and Neurotrauma Centre, DRK Kliniken Westend, Berlin, Germany

²Neurosurgical Department, Klinikum Darmstadt GmbH, Darmstadt, Germany

Address for correspondence Olaf Süß, MD, Spine and Neurotrauma Centre, DRK Kliniken Westend, Spandauer Damm 130, 14050 Berlin, Germany (e-mail: o.suess@drk-kliniken-berlin.de).

Indian J Neurotrauma 2016;13:35–38.

Abstract

Keywords

- ▶ penetrating head injury
- ▶ epileptic seizure
- ▶ head trauma

The risk of severe head injury during a seizure is usually small. Penetrating bony injuries to the skull caused by a fall on a sharp object during a seizure account for less than 3% of all ictal head injuries. Only few reports have been published on transoral, transnasal, and transorbital penetrating injuries suffered by patients who fell during a seizure. We report on a case of transnasal penetrating injury extending to the skull base and its treatment in a patient who fell on a toilet paper holder.

Introduction

About 6 to 15% of patients who suffer a first seizure sustain head injuries that require medical attention.^{1–6} Most seizure-related head injuries are accounted for by laceration and cerebral commotion. Intracranial injuries such as subarachnoid or subdural bleeding are rare. Penetrating bony injuries to the skull caused by a fall on a sharp object during a seizure have also been reported, but they account for less than 3% of all ictal head injuries.^{5–7} Even less common include transoral, transnasal, or transorbital injuries. However, there are some case reports describing such rare types of penetrating injuries associated with generalized seizures.^{8,9}

We report on a case of transnasal penetrating injury extending to the skull base and its treatment in a patient who fell on a toilet paper holder.

Case Presentation

A 51-year-old patient suffered a generalized seizure at home. When the emergency physician arrived, she was sleepy and had no apparent neurologic deficits. Bronchial cancer had been diagnosed half a year earlier, and the patient had a first episode of generalized seizure while going to the bathroom at night. Her head fell on a toilet paper

holder with two pointed vertical metal rods (▶**Fig. 1**). The tip of one of the rods entered the patient's right nostril where the conical tip remained trapped. This prevented the pulling back of the toilet paper holder. The toilet paper roll compressed the patient's nose from the opposite side, thus preventing a hemodynamically significant blood loss. The patient was brought to the emergency room with the toilet paper holder in place (▶**Fig. 1**).

On admission, the patient had recovered from her postictal state, was awake, responsive, and fully oriented. Cranial nerve function was normal. A computed tomographic (CT) scan of the head showed that one of the metal rods of the toilet paper holder extended through the right nasal vestibule along the middle and superior nasal conchae up to the cribriform lamina. There was no evidence of intracranial air or hemorrhage (▶**Fig. 2**). The cerebral CT scans obtained with soft tissue window showed multiple contrast-enhancing lesions, suggesting cerebral metastases (▶**Fig. 3**).

The patient was immediately operated on. First, the toilet paper holder was removed with a bolt cutter by cutting the rod at a distance of approximately 3 cm from where it entered the patient's nostril. This procedure was necessary to allow transoral intubation for anesthesia. The penetration pathway of the rod along the nasal mucosa up to the skull base was explored with a speculum and then the rod including its tip was extracted retrogradely. Inspection of

received

July 18, 2015

accepted after revision

November 20, 2015

published online

March 15, 2016

© 2016 Neurotrauma Society of India

DOI <http://dx.doi.org/>

10.1055/s-0036-1572518.

ISSN 0973-0508.

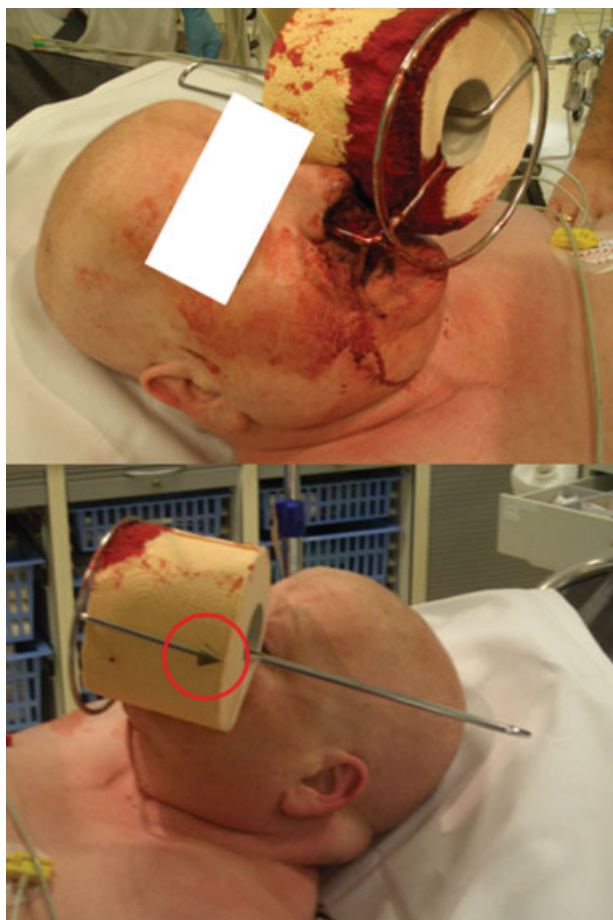


Fig. 1 A 51-year-old patient with transnasal penetrating injury caused by a fall on a toilet paper holder. Photographs show the patient immediately after arrival to the emergency room.

the cribriform lamina showed moderate mucosal injury and confirmed that the rod had not extended beyond the skull base. Following local wound management and nasal tamponade, the patient received a broad-spectrum antibiotic for 10 days. Electroencephalography (EEG) showed epileptiform discharges. Oral antiepileptic therapy was initiated. The patient was discharged on the third postoperative day without any neurologic deficit. Outpatient antiepileptic therapy was initiated, as well as further oncologic therapy against the multiple brain metastases.

Discussion

Until otherwise proven, a generalized seizure that first occurs on an adult is indicative of a brain tumor.^{1,10} About 5 to 10% of cerebral tumors come to clinical attention because of a focal or generalized seizure.¹⁻⁴ The risk of severe head injury during a seizure is usually small.⁵⁻⁷ Only few reports have been published on transoral, transnasal, and transorbital penetrating injuries suffered by patients who fell during a seizure. Such injuries are typically caused by long, pointed objects such as pencils, items of cutlery, or other hand tools.^{9,11} To our knowledge, a head injury

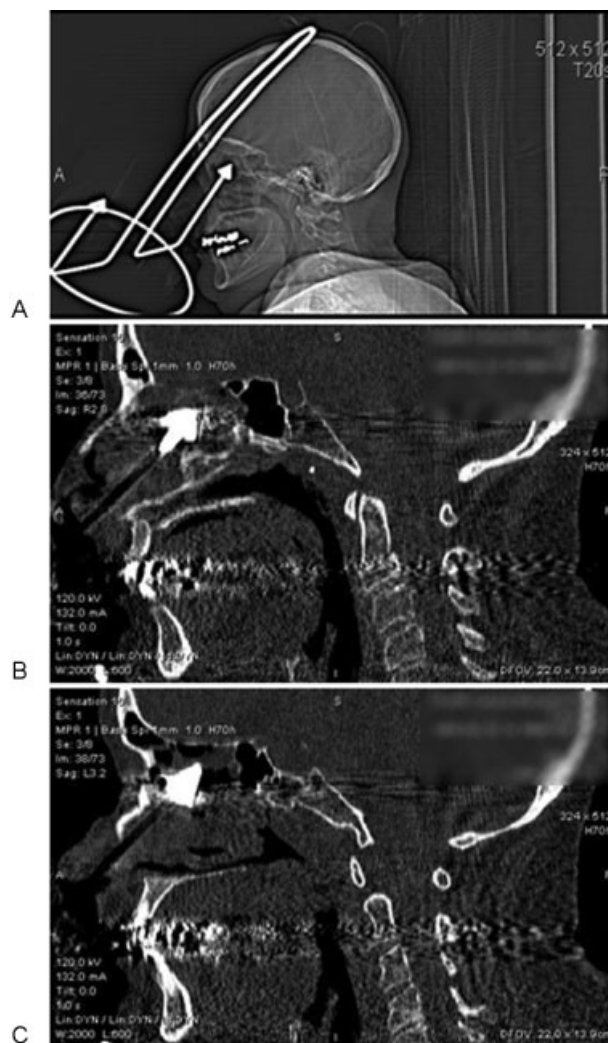


Fig. 2 Computed tomography of the head. The scout image (A) and sagittal reconstructions (B and C) show one of the rods of the toilet paper holder extending through the nose and up to the skull base. The conical tip is in direct contact with the cribriform lamina.

resulting from a fall in the bathroom, as in our patient, has not been reported hitherto in the literature.

Patients with skull penetrating injuries may develop posttraumatic complications such as a posttraumatic aneurysm, AV fistula, or meningitis.¹²⁻¹⁵ This is why prophylactic antibiotic treatment is recommended in such cases.^{14,15} The antibiotic is chosen on the basis of the contamination expected to be found on the object that caused the injury or on the results of an antibiogram. The penetrating object in our case was probably diffusely contaminated with aerobic and anaerobic pathogens, which is why a broad-spectrum antibiotic agent was chosen.

The CT scans allowed good visualization of the metal rod within the skull and the relationship of its tip to the skull base. Magnetic resonance imaging (MRI) was not possible in our patient because the penetrating object was metallic, as is the case in most patients with this kind of injury.

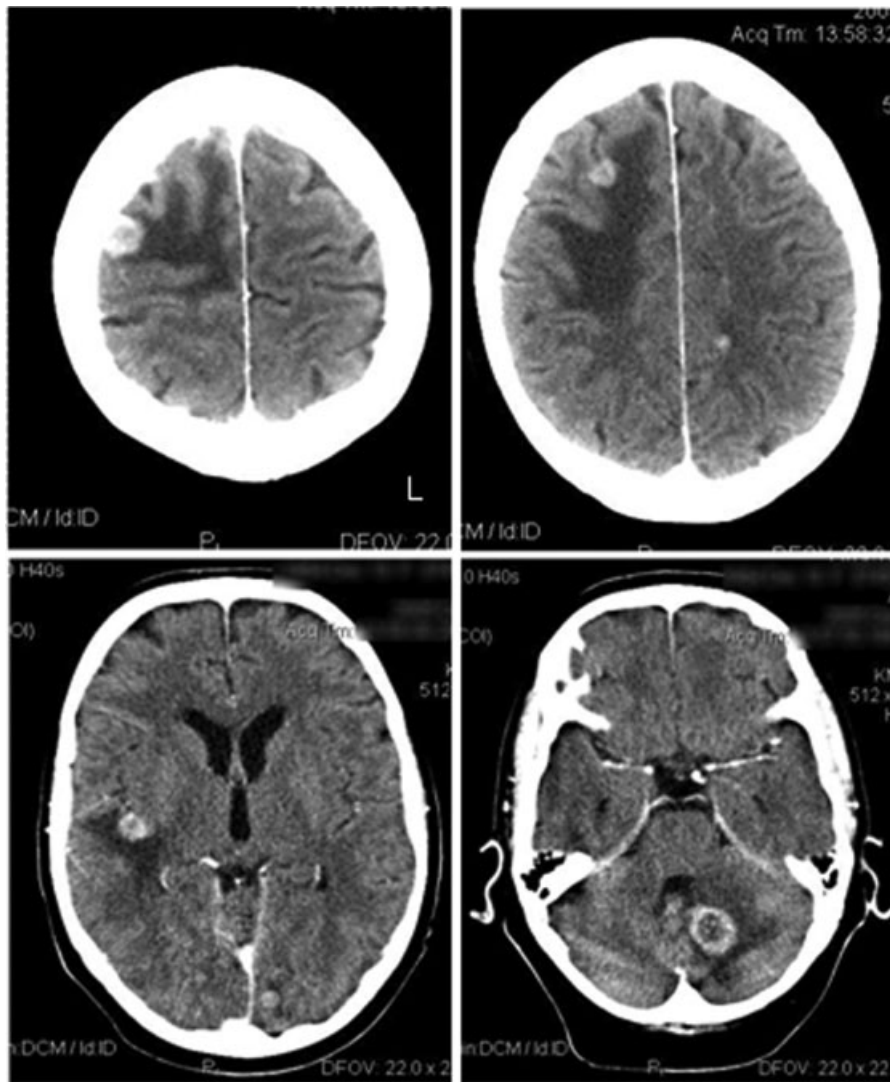


Fig. 3 Computed tomography of the head after contrast medium administration. The soft tissue window shows multiple intracranial contrast-enhancing lesions suggestive of multiple cerebral metastases from the patient's known bronchial cancer.

In patients in whom a posttraumatic vascular lesion is suspected, imaging can be supplemented by conventional pan-angiography.¹⁶ Subsequent MRI may help localize the source of a cerebrospinal fluid leakage.

In patients with transnasal penetrating injuries, the strategy is to leave the penetrating object in place until the patient has been brought to a suitable trauma center. Only the careful evaluation of all imaging findings in each individual case allows deciding whether it is possible to extract the object retrogradely or whether craniotomy is required for anterograde removal. The latter is associated with a high risk of infection and should therefore be performed only under administration of meningeal doses of a broad-spectrum antibiotic. Anticonvulsive medication should be monitored by means of EEG and blood-level determination of anticonvulsants prior to discharge. Otherwise, posttraumatic seizures could

potentiate the risk of epileptic seizures in patients with brain tumors.¹⁷

References

- 1 Siomin V, Angelov L, Li L, Vogelbaum MA. Results of a survey of neurosurgical practice patterns regarding the prophylactic use of anti-epilepsy drugs in patients with brain tumors. *J Neurooncol* 2005;74(2):211–215
- 2 Weiss GH, Feeney DM, Caveness WF, et al. Prognostic factors for the occurrence of posttraumatic epilepsy. *Arch Neurol* 1983; 40(1):7–10
- 3 Stephen LJ, Kelly K, Mohanraj R, Brodie MJ. Pharmacological outcomes in older people with newly diagnosed epilepsy. *Epilepsy Behav* 2006;8(2):434–437
- 4 van Rijckevorsel K. Medical treatment of newly diagnosed epilepsy. *Acta Neurol Belg* 1999;99(4):226–230

- 5 Unglaub F, Woodruff S, Demir E, Pallua N. Patients with epilepsy: a high-risk population prone to severe burns as a consequence of seizures while showering. *J Burn Care Rehabil* 2005;26(6): 526–528, discussion 525
- 6 Day SM, Wu YW, Strauss DJ, Shavelle RM, Reynolds RJ. Causes of death in remote symptomatic epilepsy. *Neurology* 2005;65(2): 216–222
- 7 Vestergaard P. Epilepsy, osteoporosis and fracture risk—a meta-analysis. *Acta Neurol Scand* 2005;112(5):277–286
- 8 Ey W. [Orbital involvement in frontobasal injuries]. *Laryngol Rhinol Otol (Stuttg)* 1981;60(4):162–167
- 9 de Villiers JC. Proceedings: sixteen cases of transorbital stab wounds of the head. *J Neurol Neurosurg Psychiatry* 1975;38(8): 822
- 10 Ramirez-Lassepas M, Cipolle RJ, Morillo LR, Gumnit RJ. Value of computed tomographic scan in the evaluation of adult patients after their first seizure. *Ann Neurol* 1984;15(6): 536–543
- 11 Fallon MJ, Plante DM, Brown LW. Wooden transnasal intracranial penetration: an unusual presentation. *J Emerg Med* 1992;10(4): 439–443
- 12 Jacob OJ, Rosenfeld JV, Taylor RH, Watters DA. Late complications of arrow and spear wounds to the head and neck. *J Trauma* 1999; 47(4):768–773
- 13 Hagan RE. Early complications following penetrating wounds of the brain. *J Neurosurg* 1971;34(2 Pt 1):132–141
- 14 Neal G, Downing EF. Clostridial meningitis as a result of craniocerebral arrow injury. *J Trauma* 1996;40(3):476–480
- 15 de Tribolet W, Guignard G, Zander E. Brain abscess after transnasal intracranial penetration of a paint-brush. *Surg Neurol* 1979;11(3):187–189
- 16 Kaal EC, Taphoorn MJ, Vecht CJ. Symptomatic management and imaging of brain metastases. *J Neurooncol* 2005;75(1):15–20
- 17 Hauser WA, Anderson VE, Loewenson RB, McRoberts SM. Seizure recurrence after a first unprovoked seizure. *N Engl J Med* 1982; 307(9):522–528