

# Prophylactic Venous Supercharged Radial Collateral Artery Perforator Propeller Flap: Improved Outcome in Perforator Propeller Flaps

Damir Kosutic, MD, PhD, FRCS (Plast)<sup>1</sup> Pratap Dutta, MBBS, MS, MRCSEd<sup>1</sup>  
Ingrid Kieran, MD, MRCS, MB, BCh, BAO<sup>1</sup>

<sup>1</sup> Department of Plastic Surgery, The Christie NHS Foundation Trust, Manchester, United Kingdom

J Reconstr Microsurg Open 2016;1:45–47.

Address for correspondence Damir Kosutic, MD, PhD, FRCS (Plast), Department of Plastic Surgery, The Christie NHS Foundation Trust, Wilmslow Road, M20 4BX, Manchester, United Kingdom (e-mail: dkosutic@hotmail.com).

Propeller flaps provide a safe and reliable reconstructive option. Following flap rotation intraoperatively, a degree of venous stasis occurs. Difficulty lies in predicting whether this is likely to be transient or not. These flaps are therefore frequently at risk of venous congestion which can result in partial or total flap necrosis.<sup>1</sup> This results in delayed wound healing and often necessitates further surgical procedures to achieve the final outcome. This defeats the original intention of performing a reliable, one-stage, and aesthetically pleasing reconstructive technique. Subsequent management of flap necrosis can include conservative and surgical management. Long-term dressings and negative pressure therapy, with or without eventual skin grafting, will result in wound healing, but can take time and are incapacitating for patients. The final result, by these means, can potentially negatively impact upper limb function in terms of scar contracture and appear less aesthetically pleasing. We present two prophylactically venous supercharged radial collateral artery perforator (RCAP) propeller flaps in the upper limb and suggest this is a more reliable approach than the standard RCAP flap technique.

## Case 1

A 57-year-old man underwent a 2-cm-wide local excision of his left proximal dorsal forearm for a 1.6-mm-thick melanoma. The resultant defect measured 10 × 7 cm. Using a Doppler, an RCAP propeller flap was designed around a perforator located in close proximity to the lateral humeral epicondyle (→Fig. 1A, B). A 13 × 7 cm RCAP flap was raised (→Fig. 1C) along with a superficial vein found close to the distal tip of the flap (→Fig. 1D). A recipient superficial vein was dissected at the distal end of the forearm defect.

The flap was rotated 180 degrees on this single perforator and set into the defect. The flap remained largely well perfused; however, there were signs of congestion at the distal end of the flap. The dissected superficial vein in the flap was therefore anastomosed to the recipient superficial vein in the forearm defect (→Fig. 2A). The congestion initially observed rapidly dissipated several minutes after the venous anastomosis. Excellent blood flow was observed.

The donor site was closed directly. Postoperative wound healing was uneventful and the entire flap survived. Full range of movement was maintained at the elbow, and the patient had an excellent aesthetic outcome. This was observed by surgeon and reported by the patient in terms of a highly satisfied outcome (→Fig. 2B).

## Case 2

A 73-year-old woman underwent a 2-cm-wide local excision of a recurrent melanoma on her right arm. The subsequent defect measured 12 × 9 cm. Using a Doppler, an RCAP propeller flap was designed on the dorsal proximal forearm around a perforator located in close proximity to the lateral humeral epicondyle (→Fig. 3A). The flap was raised and an additional superficial vein was dissected for prophylactic augmentation of venous drainage. The flap was rotated 130 degrees counterclockwise into the defect and the superficial vein on its tip was anastomosed to a branch of the cephalic vein (→Fig. 3B). No venous congestion was observed.

The donor site was closed directly. Postoperative wound healing was uneventful, the entire flap survived, and full range of movement of the elbow was maintained (→Fig. 3C).

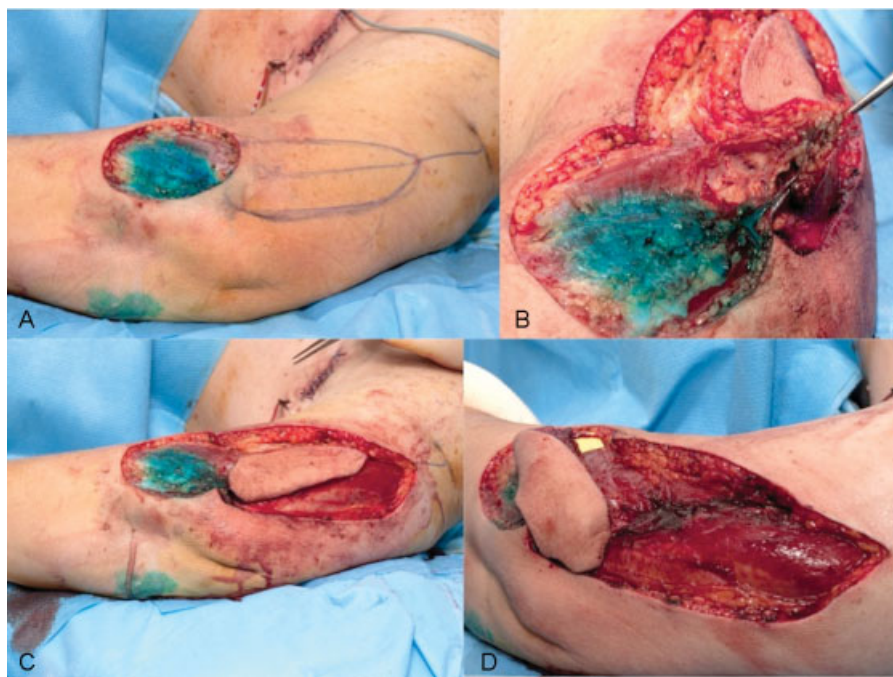
received  
April 26, 2015  
accepted after revision  
August 23, 2015  
published online  
February 11, 2016

DOI <http://dx.doi.org/10.1055/s-0035-1570533>.  
ISSN 2377-0813.

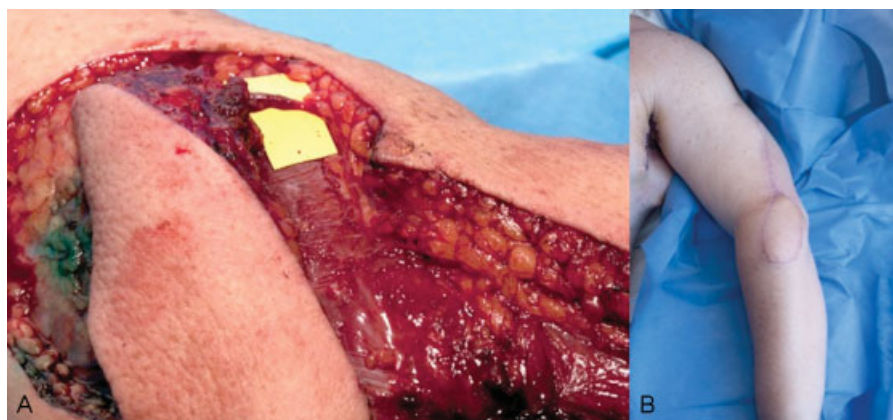Copyright © 2016 by Thieme Medical Publishers, Inc., 333 Seventh Avenue, New York, NY 10001, USA.  
Tel: +1(212) 584-4662.

License terms





**Fig. 1** A–D Left upper arm RCAP propeller flap designed around the perforator in close proximity to lateral epicondyle and harvested from upper arm.



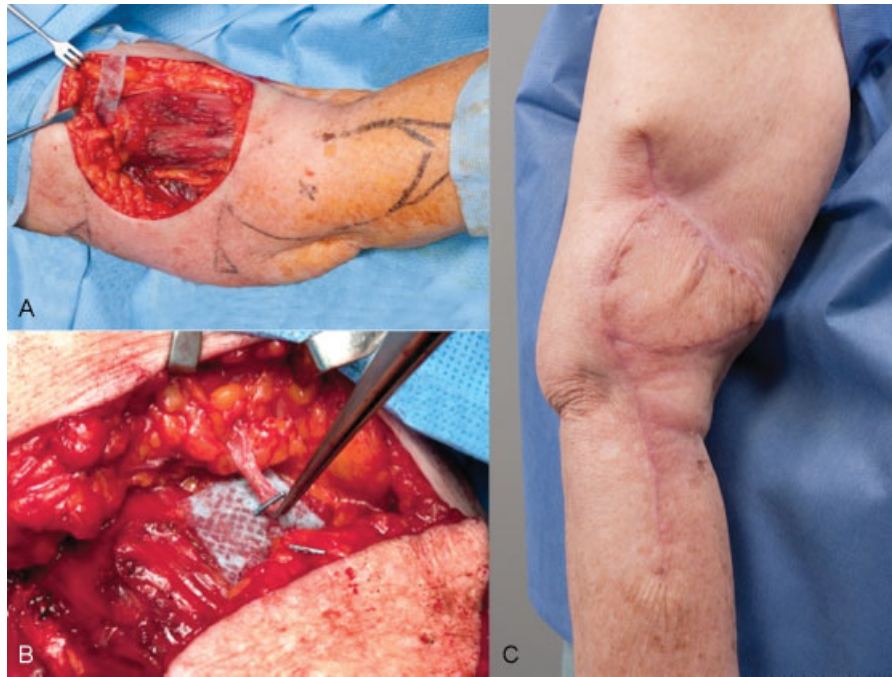**Fig. 2** A Prophylactic venous supercharging of RCAP flap by anastomosing superficial vein at the tip of the flap with superficial vein on the dorsal forearm following flap rotation. B Excellent functional and aesthetic outcome at 6-month follow-up.

## Discussion

Favorable characteristics of the RCAP propeller flap include a reliable perforator, ease of dissection, and avoidance of sacrificing major pedicles and muscle in a single-stage reconstructive procedure for small- to medium-sized defects,<sup>2</sup> including both skin and the bone.<sup>3</sup> However, as with all propeller flaps, there is a risk of venous congestion following rotation and flap inset. This can delay wound healing, entail further surgical procedures, and negatively impact final overall function and aesthetics.<sup>1</sup> This undermines the benefits of the propeller flap technique which

can be used as a reliable, one-stage, and aesthetically pleasing reconstructive technique. The time taken for dissection of this superficial vein within the distal end of the flap, as well as the recipient vessel, is minimal with an abundance of veins of adequate caliber available in the dorsal forearm and arm.

These cases illustrate that with inclusion of an additional superficial vein for augmenting venous drainage, larger flaps can safely be raised and the risk of venous congestion as well as flap necrosis can be reduced. This also introduces the possibility of performing this more robust technique safely as a day case eliminating the need for hospital



**Fig. 3** A, B Forearm RCAP flap for reconstruction of upper arm defect based on perforator next to lateral epicondyle, rotated into upper arm defect. Branch of cephalic vein dissected as a recipient for venous supercharging. C Flap healed with full range of motion in elbow on follow-up.

admission and flap observations. We propose the prophylactically venous supercharged RCAP propeller flap as a safe and reliable option in reconstructing challenging defects in the arm, forearm, and elbow region.

#### Acknowledgment

The authors thank the Medical Illustration Department at Christie Hospital for preparation of excellent quality clinical photographs.

#### References

- 1 Innocenti M, Menichini G, Baldrighi C, Delcroix L, Vignini L, Tos P. Are there risk factors for complications of perforator-based propeller flaps for lower-extremity reconstruction? *Clin Orthop Relat Res* 2014;472(7):2276–2286
- 2 Murakami M, Ono S, Ishii N, Hyakusoku H. Reconstruction of elbow region defects using radial collateral artery perforator (RCAP)-based propeller flaps. *J Plast Reconstr Aesthet Surg* 2012;65(10):1418–1421
- 3 Song D, Xu J, Lv H, Liu J, Li J. Wraparound chimeric radial collateral artery perforator flap for reconstruction of thumb loss. *J Reconstr Microsurg* 2015;31(2):95–101