

Brainstem Hemorrhage after Evacuation of Chronic Subdural Hematoma: A Case Report and Review of Literature

Vinu V. Gopal¹ K. Mahadevan¹

¹Department of Neurosurgery, Medical College, Kottayam, Kerala
Indian J Neurotrauma 2015;12:152–155.

Address for correspondence Dr. Vinu. V. Gopal, MBBS, MS, MCh,
Department of Neurosurgery, Government Medical College,
Kottayam, Kerala 686008, India (e-mail: vinoogopa@gmail.com).

Abstract

Brainstem hemorrhage following evacuation of chronic subdural hematoma is extremely rare and its pathogenesis is unclear. In our case report, we present a rare case of brainstem hemorrhage following evacuation chronic subdural hematoma. Our patient was a 50-year-old man, with no comorbidities, presented with dorsal midbrain hemorrhage with ventricular extension and symptomatic progression of contralateral small chronic subdural hematoma following evacuation of chronic subdural hematoma. Contralateral subdural hematoma was evacuated and midbrain hemorrhage was managed conservatively. He was discharged with minimal neurologic deficit. Review of literature and pathogenesis of remote hemorrhage after evacuation of chronic subdural hematoma were discussed.

Keywords

- ▶ brainstem
- ▶ hemorrhage
- ▶ chronic
- ▶ subdural

Chronic subdural hematoma is a common neurosurgical condition among elderly.¹ Treatment includes evacuation of hematoma by burr hole drainage.² Postoperative complications are usually rare and give gratifying postoperative results.

Although rare, unexpected complications may occur. Spontaneous brainstem hemorrhage following evacuation of chronic subdural hematoma is extremely rare.³ Literature review showed only five cases of brainstem hemorrhage following chronic subdural hematoma evacuation of chronic subdural hematoma.

Pathogenesis of brainstem hemorrhage and other remote site hematoma following evacuation of chronic subdural hematoma is not clear.^{4,5} Rapid evacuation of hematoma increases the cerebral blood flow due to defective autoregulation.^{4,6} This along with massive brain shift and transtentorial herniation due to raised intracranial pressure^{7,8} damages fragile atherosclerotic intracerebral vessels⁹ leading to remote hemorrhage.¹⁰ Altered coagulation, massive air reflux through burr hole, and labile hypertension are the other initiating risk factors.

Here we report an extremely rare case of dorsal midbrain hemorrhage and symptomatic progression of contra lateral hematoma following evacuation of chronic subdural hematoma. Possible mechanism of remote hemorrhage is discussed in detail after reviewing literature.

Case Report

Our patient, a 50-year-old man, with no comorbidities, was admitted to our hospital with headache following alleged assault 3 weeks back. Preoperative coagulation profile was normal. Computed tomography (CT) showed isodense subdural hematoma on the right-sided frontoparietal region with mass effect to the left side (▶ **Fig. 1**).

The patient was taken up for burr hole craniectomy on the right side after obtaining informed written consent. Two burr hole craniectomies were performed on the right side in supine position under general anesthesia (GA). Dural opening revealed black motor oil looking chronic subdural hematoma. Hematoma was evacuated. Irrigation was done till effluents were clear. The patient was extubated and

received
April 29, 2015
accepted
October 19, 2015
published online
December 17, 2015

© 2015 Neurotrauma Society of India DOI <http://dx.doi.org/10.1055/s-0035-1569471>.
ISSN 0973-0508.

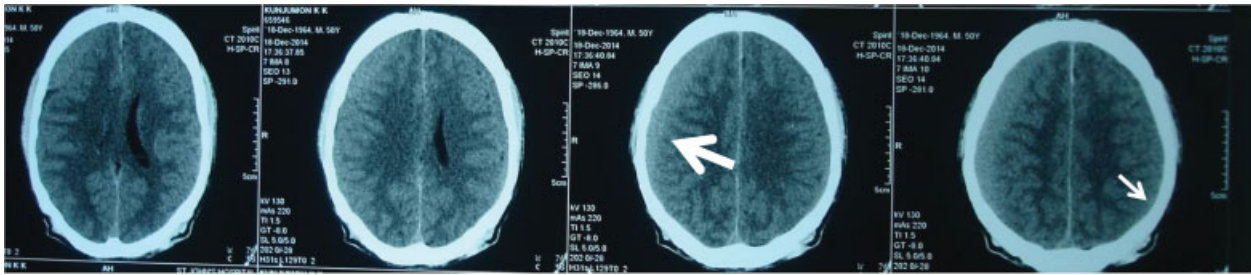


Fig. 1 Preoperative CT axial view: thick white arrow showing isodense subdural hematoma on the right frontoparietal area with small high parietal isodense subdural hematoma on the left side (thin white arrow).

shifted to the intensive care unit (ICU). He was drowsy following extubation and decerebrated 3 hours later, and hence was reintubated and ventilated. Emergency CT scan was taken, which showed contralateral frontoparietal acute on chronic subdural hematoma with mass effect to the right side (►**Fig. 2A**). There was associated dorsal midbrain hemorrhage with intraventricular extension (►**Fig. 2B**). The patient was taken up for emergency burr hole craniectomy for evacuating the left-sided subdural hematoma (►**Fig. 3**). Two burr hole craniectomies were done. Dural opening revealed black motor oil looking chronic subdural hematoma with fresh clots. Irrigation was done till effluents are clear.

Postoperatively, the patient was electively ventilated for 24 hours. He was weaned off the ventilator to synchronized intermittent mandatory ventilation (SIMV) the next day. The patient was localizing to pain with no asymmetry of limbs

with the eye opening on calling and making inappropriate words. There were vertical gaze palsy and truncal ataxia. Next day, he started obeying commands with spontaneous eye opening and hence extubated. After 6 weeks postoperative follow-up, he was able to sit with support and communicate with minimal dysarthria. Six weeks postoperative follow-up showed near-complete resolution of brainstem hemorrhage with no significant hydrocephalus (►**Fig. 4**).

Discussion

Chronic subdural hematoma is a common neurosurgical condition among elderly.¹ Burr hole craniectomy is the safest and most effective treatment of chronic subdural hematoma.² Postoperative complications such as residual hematoma, rebleeding, cerebral edema, infection, seizures, and, rarely, remote intracerebral hemorrhage can occur.

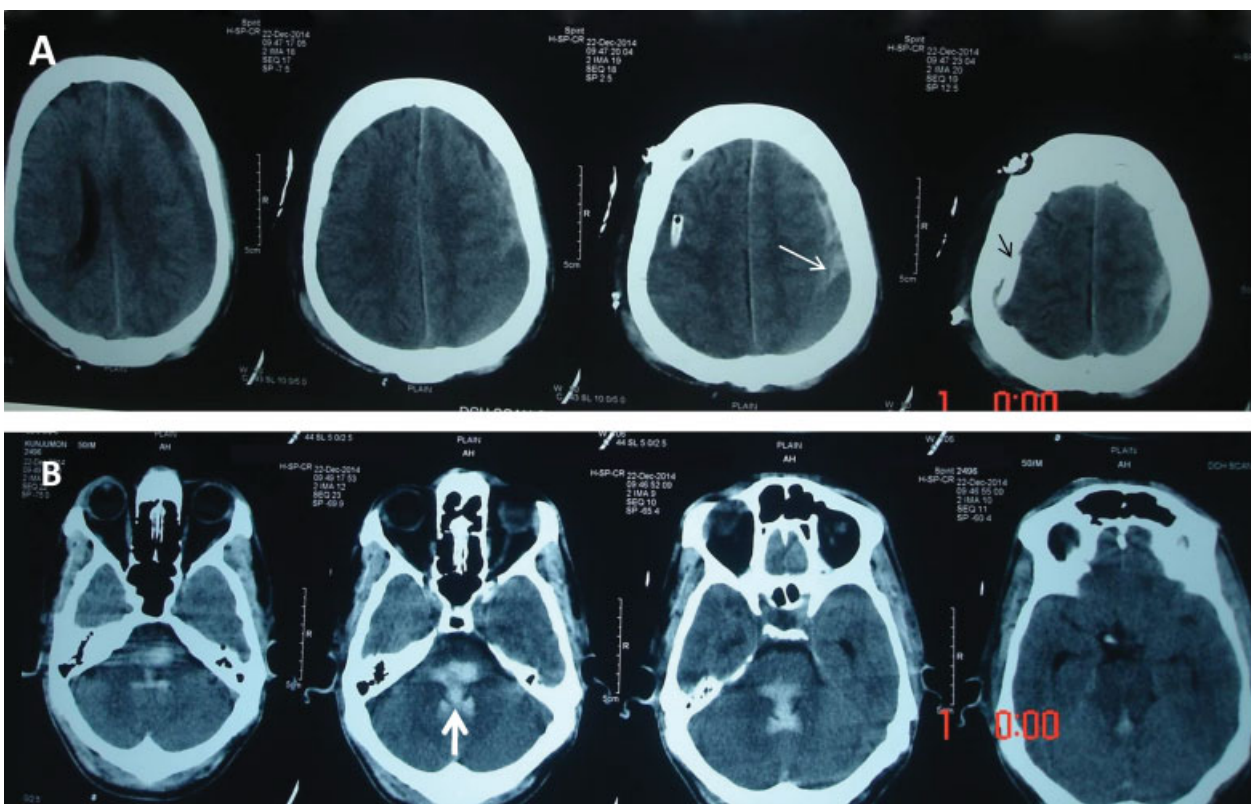


Fig. 2 (A) Postoperative CT scan showing progression of contralateral thin high parietal subdural hematoma (white arrow). Black arrow showing drain. (B) Dorsal pons midbrain hemorrhage extending into the ventricular system with minimal hydrocephalus (thick white arrow).

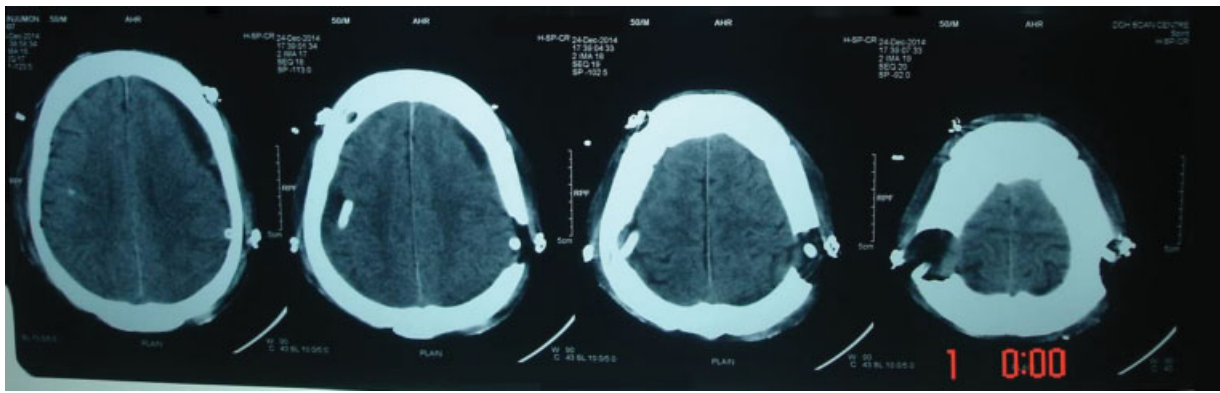


Fig. 3 Postoperative CT scan after evacuation of contralateral subdural hematoma.

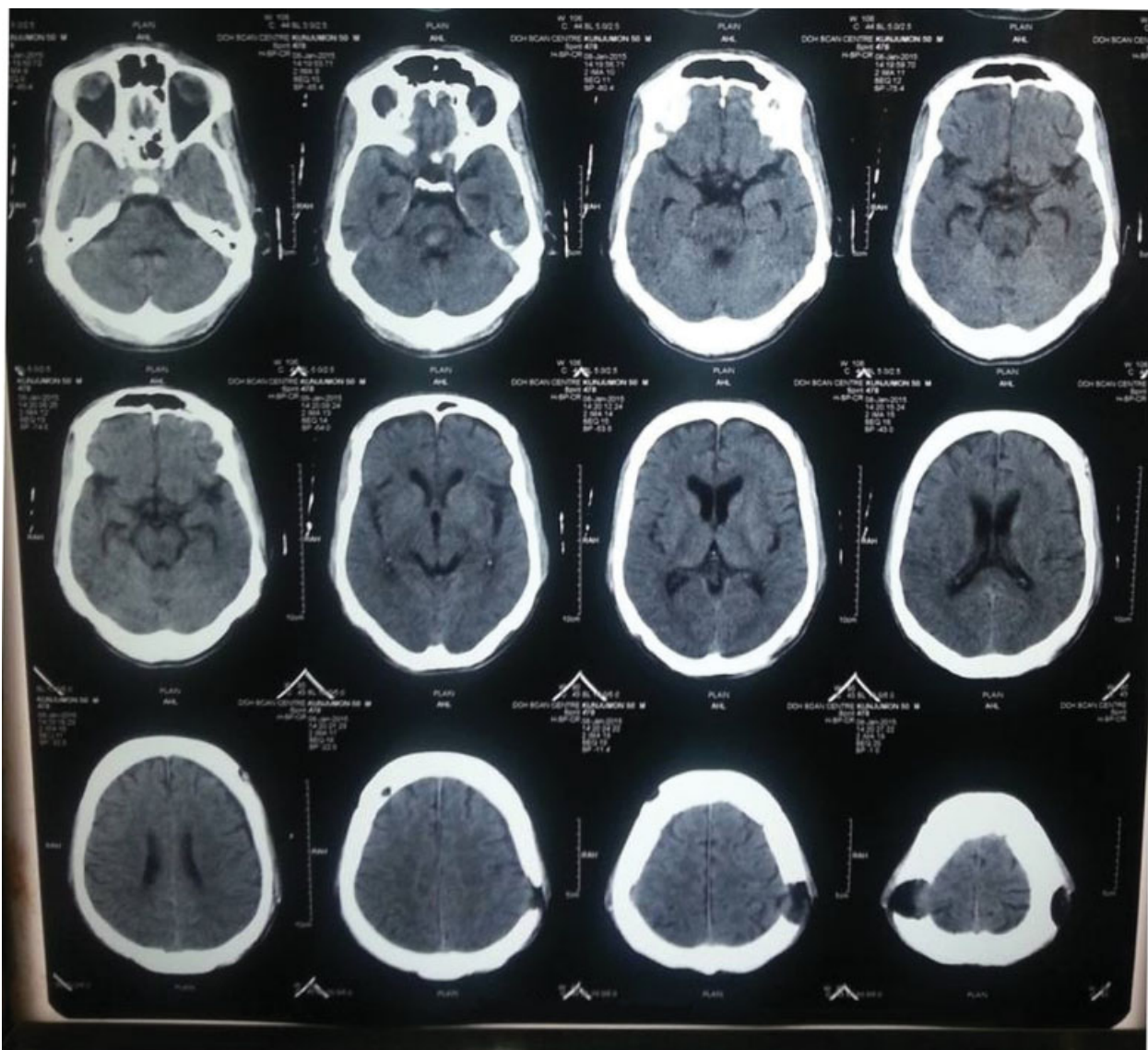


Fig. 4 Postoperative CT scan 2 weeks later showing resolving dorsal midbrain hemorrhage.

Spontaneous intracranial hematoma associated with evacuation of chronic subdural hematoma is uncommon and often associated with significant mortality and

morbidity. Spontaneous intracranial hemorrhage can occur on contralateral side and rarely infratentorial sites such as cerebellum,¹¹ and intra-axial brainstem can get involved.⁸

Literature review showed only five cases of brainstem hemorrhage. Two cases were detected following autopsy.¹² One patient succumbed and the fourth gradually improved⁸ whereas the fifth died. Here we report an extremely rare case of dorsal midbrain hemorrhage following evacuation of chronic subdural hematoma, who gradually improved with conservative management.

Incidence of spontaneous intracerebral hematoma following evacuation of chronic subdural hematoma is as low as 1 to 5%.³⁻⁵ Pathophysiology of postoperative remote site hematoma following evacuation of chronic subdural hematoma is not clear.^{4,5} Rapid evacuation of hematoma increases the cerebral blood flow because of defective autoregulation.⁶ This along with massive brain shift and transtentorial herniation due to raised intracranial pressure⁷ damages fragile atherosclerotic intracranial vessels⁹ producing remote site hematoma. Altered coagulation, massive air reflux through burr hole, labile hypertension, and loss of carbon dioxide reactivity in ischemic brain may be other initiating risk factors.^{4,5,8,10}

Pathophysiology of brainstem hemorrhage following evacuation of chronic subdural hematoma is difficult to study as it often causes immediate death. A previous animal study suggested that brainstem hemorrhage was likely due to disruption of damaged atherosclerotic fragile vessels following raised intracranial pressure.⁸ In our case, blood vessels near the brainstem might be stretched and distorted due to raised intracranial pressure that led to early vascular disruption. Physiologic aging of cerebral vasculature is associated with poor tolerance of sudden variation in cerebral blood flow due to defective autoregulation.^{4,8} Thus the mechanism of brainstem hemorrhage in our patient who was elderly might be due to mechanical disruption of small fragile intracranial blood vessels. We had not ruled out secondary pathology such as arteriovenous malformation (AVM), cavernous malformation, and neoplasm, considering the urgent nature of the condition. Dorsal midbrain is an extremely rare site for remote hemorrhage following evacuation of chronic subdural haematoma.^{4,5,8}

The main surgical strategy to avoid the occurrence of remote hemorrhage following evacuation of chronic subdural hematoma is to do a gradual decompression avoiding rapid changes in cerebral blood flow. This can be accomplished by applying cotton strips near the burr hole immediately after opening the outer membrane.^{5,8} Copious irrigation during the procedure can prevent the sudden brain shift also.^{5,8,10} Continuous closed-system drainage has also been proposed, as this allows the brain to reexpand slowly to obliterate subdural space.^{5,8} Head rotation should be minimized as flexion and hyperextension can obstruct the cerebral venous flow, thus increasing the chance for remote hemorrhage.^{4,8}

Conclusion

Although evacuation of subdural hematoma gives gratifying results, it is not free from complications. This case report

gives us an insight into the possible mechanism of remote intracerebral hemorrhage following evacuation of chronic subdural hematoma. The importance of careful slow decompression of chronic subdural hematoma to avoid perioperative brain shift is stressed. The need for good postoperative monitoring to detect early complications is also emphasized.

Conflicts of Interest

All authors have nothing to declare. This study has not received any financial support. The authors alone are responsible for the content of the paper.

Acknowledgment

I would like to thank Dr. K. Mahadevan and other staff members in neurosurgery department for helping me in preparing this manuscript.

References

- 1 Sambasivan M. An overview of chronic subdural hematoma: experience with 2300 cases. *Surg Neurol* 1997;47(5): 418-422
- 2 Weigel R, Schmiedek P, Krauss JK. Outcome of contemporary surgery for chronic subdural haematoma: evidence based review. *J Neurol Neurosurg Psychiatry* 2003;74(7):937-943
- 3 Modesti LM, Hodge CJ, Barnwell ML. Intracerebral hematoma after evacuation of chronic extracerebral fluid collections. *Neurosurgery* 1982;10(6 Pt 1):689-693
- 4 Rojas-Medina LM, Goel A. Brainstem hemorrhage secondary to evacuation of chronic subdural hematoma. *Neurol India* 2014; 62(4):435-437
- 5 Rusconi A, Sangiorgi S, Bifone L, Balbi S. Infrequent hemorrhagic complications following surgical drainage of chronic subdural hematomas. *J Korean Neurosurg Soc* 2015;57(5): 379-385
- 6 d'Avella D, De Blasi F, Rotilio A, Pensabene V, Pandolfo N. Intracerebral hematoma following evacuation of chronic subdural hematomas. Report of two cases. *J Neurosurg* 1986; 65(5):710-712
- 7 Marmarou A, Shulman K, Rosende RM. A nonlinear analysis of the cerebrospinal fluid system and intracranial pressure dynamics. *J Neurosurg* 1978;48(3):332-344
- 8 Park KJ, Kang SH, Lee HK, Chung YG. Brain stem hemorrhage following burr hole drainage for chronic subdural hematoma—case report. *Neurol Med Chir (Tokyo)* 2009;49(12):594-597
- 9 Miyazaki T, Matsumoto Y, Ohta F, Daisu M, Moritake K. A case of unknown origin subarachnoid hemorrhage immediately following drainage for chronic subdural hematoma. *Kurume Med J* 2004;51(2):163-167
- 10 Kollatos C, Konstantinou D, Raftopoulos S, et al. Cerebellar hemorrhage after supratentorial burr hole drainage of a chronic subdural hematoma. *Hippokratia* 2011;15(4):370-372
- 11 Ulivieri S, Oliveri G. Intracerebral haemorrhage following surgical evacuation of chronic subdural haematoma: case report. *G Chir* 2008;29(5):233-234
- 12 Robinson RG. Chronic subdural hematoma: surgical management in 133 patients. *J Neurosurg* 1984;61(2):263-268