

# Tension Pneumocephalus in Head Injury

P. K. Nayak<sup>1</sup>

<sup>1</sup>Department of Neurosurgery, Sparsh Hospital, Bhubaneswar, Odisha, India  
Indian J Neurotrauma 2015;12:162–163.

Address for correspondence Dr. P. K. Nayak, MS, MCh, L-10, Netaji Subhas enclave, Chandrasekharpur, Near Railway Stadium, Bhubaneswar, Odisha 751017, India (e-mail: drmichaelpn@gmail.com).

## Abstract

Occurrence of pneumocephalus following a head trauma is relatively rare. Tension pneumocephalus can manifest as severe headache, dizziness, mental changes, and even seizure; therefore, urgent diagnosis and treatment are mandatory. The Mount Fuji sign on CT scans of the brain is useful in discriminating tension pneumocephalus from nontension pneumocephalus. Deterioration due to an increase in subdural air volume can be evacuated by craniotomy. Though uncommon, tension pneumocephalus is a life-threatening complication that requires urgent diagnosis and treatment.

## Keywords

- ▶ head injury
- ▶ tension pneumocephalus
- ▶ Mount Fuji sign

The usual causes of pneumocephalus are traumatic fractures involving the ethmoidal or frontal sinuses. Untreated pneumocephalus can progress to tension pneumocephalus, manifested as severe headache, dizziness, nerve palsy, mental changes, and even seizure; therefore urgent diagnosis and treatment are mandatory.<sup>1</sup>

A 23-year-old man presented to us with head injury due to road traffic accident. He was having transient loss of consciousness. There was also no cerebrospinal fluid (CSF) leak or seizure. He was conscious and no other deficit was noted on clinical evaluation.

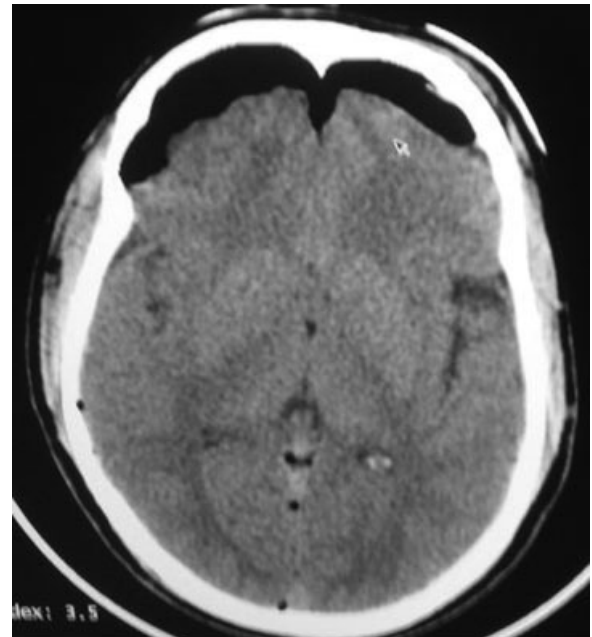
Computed tomographic (CT) scan of the brain revealed gross pneumocephalus and fractures of the basifrontal bone involving the frontal sinus and nasal bone (▶ **Fig. 1**). The patient was advised for twist drill aspiration of pneumocephalus, but he refused for surgery.

## Discussion

Chiari is credited with the first description of intracranial air, detailed in an autopsy report in 1884.<sup>2</sup> Pneumocephalus following head trauma is relatively rare, with tension pneumocephalus occurring in an even smaller group of patients.<sup>3</sup> Pneumocephalus can occur due to head trauma and fractures involving the frontal sinus area, skull base, and associated dural tear. Not much is described about tension pneumocephalus and its treatment in the available literature.

The Mount Fuji sign on CT scans of the brain is useful in discriminating tension pneumocephalus from nontension pneumocephalus.<sup>4</sup> The Mount Fuji sign is a finding that can

be observed on CT scans of the brain, in which bilateral subdural hypoattenuating collections cause compression and separation of the frontal lobes. The collapsed frontal lobes and the widening of the interhemispheric space between the tips of the frontal lobes have the appearance of the silhouette of Mount Fuji.<sup>4</sup>



**Fig. 1** CT of the brain showing tension pneumocephalus.

received  
October 20, 2015  
accepted  
November 2, 2015  
published online  
December 17, 2015

© 2015 Neurotrauma Society of India DOI <http://dx.doi.org/10.1055/s-0035-1569468>.  
ISSN 0973-0508.

Deterioration of neurologic status and even cardiac arrest can occur in some cases.<sup>5</sup> Deterioration due to an increase in subdural air volume can be evacuated by craniotomy.<sup>6</sup> Though uncommon, tension pneumocephalus is a life-threatening complication that requires urgent diagnosis and treatment.<sup>7</sup> Early surgery can save the patient from other complications and can be survived with good outcome.

### References

- 1 Moon HS, Lee SK, Chung SH, et al. Recurred pneumocephalus in a head trauma patient following positive pressure mask ventilation during induction of anesthesia—a case report. *Korean J Anesthesiol*. 2010;59:183–186
- 2 Paul T, Eric JM, Francis H, et al. Incidence, radiographical features, and proposed mechanism for pneumocephalus from intravenous injection of air. *West J Emerg Med* 2010;11:180–185
- 3 Nicholson B, Dhindsa H. Traumatic tension pneumocephalus after blunt head trauma and positive pressure ventilation. *Prehosp Emerg Care* 2010;14(4):499–504
- 4 Michel SJ. The Mount Fuji sign. *Radiology* 2004;232(2):449–450
- 5 Joshi SM, Demetriades A, Vasani SS, Ellamushi H, Yeh J. Tension pneumocephalus following head injury. *Emerg Med J* 2006; 23(4):324
- 6 Oge K, Akpınar G, Bertan V. Traumatic subdural pneumocephalus causing rise in intracranial pressure in the early phase of head trauma: report of two cases. *Acta Neurochir (Wien)* 1998;140(7): 655–658
- 7 Prabhakar H, Bithal PK, Garg A. Tension pneumocephalus after craniotomy in supine position. *J Neurosurg Anesthesiol* 2003; 15(3):278–281