

Assessment of Cardiac Rate and Rhythm in Fetuses with Arrhythmia via Maternal Abdominal Fetal Electrocardiography

Hari K. Narayan, MD¹ Emilia F. Vignola, MSPH² William P. Fifer, PhD³ Ismee A. Williams, MD, MS⁴

¹Division of Cardiology, Department of Pediatrics, The Children's Hospital of Philadelphia, Philadelphia, Pennsylvania

²Department of International Health, Johns Hopkins School of Public Health, Baltimore, Maryland

³Department of Developmental Neuroscience, Columbia University Medical Center, Sackler Institute of Developmental Psychobiology, New York, New York

⁴Division of Pediatric Cardiology, Department of Pediatrics, Columbia University Medical Center, New York, New York

Address for correspondence Hari K. Narayan, MD, Division of Cardiology, Department of Pediatrics, The Children's Hospital of Philadelphia, 8NW-25, 3401 Civic Center Blvd, Philadelphia, PA 19104 (e-mail: narayanh@email.chop.edu).

Am J Perinatol Rep 2015;5:e176–e182.

Abstract

Objective This study aims to report our experience using the Monica AN24 (Monica Healthcare Ltd., Nottingham, United Kingdom), a maternal transabdominal fetal electrocardiographic monitor, in a case series of fetuses with arrhythmias.

Study Design We recorded fetal electrocardiograms (fECGs) on subjects with fetal arrhythmias diagnosed by fetal echocardiogram. Fetal heart rate and rhythm were determined via manual fECG analysis.

Results Overall, 20 fECGs were recorded from a pool of 13 subjects. Fetal heart rate acquisition was determined to be high, medium, and poor quality in 10, 3, and 7 tracings, respectively. High-quality tracings were obtained in 9 of 11 subjects with gestational age < 26 or > 34 weeks. P waves were detectable in five tracings.

Conclusion In subjects < 26 or > 34 weeks' gestational age, there was reasonable success in fetal heart rate acquisition. Further study is warranted to determine the potential role of this device in the monitoring of subjects with fetal arrhythmias.

Keywords

- ▶ fetal electrocardiogram
- ▶ fetal arrhythmia
- ▶ atrial flutter
- ▶ fetal heart rate

Fetal arrhythmias occur in 1 to 2% of pregnancies and account for 10 to 20% of fetal echocardiogram referrals.^{1,2} They can lead to significant morbidity including hydrops fetalis and fetal demise. Current methods of diagnosis and monitoring are limited. The most accurate test for diagnosis of fetal arrhythmias may be magnetocardiography, but this modality has limited availability because of its prohibitive expense.³ Ultrasound is currently the standard of care in the clinical setting for diagnosis and monitoring of fetal arrhythmias. However, ultrasound also has limitations as electrical events are inferred via M-mode assessment of the timing of atrial and ventricular contractions or via pulse-

wave Doppler assessment of blood flow as a result of contractions. After the diagnosis of fetal arrhythmia is established, continued assessment of the fetal rate and rhythm with serial fetal echocardiograms is necessary to monitor the effects of maternally ingested antiarrhythmic medications as well as the natural progression of the arrhythmia.⁴ Admission of the expectant mother to the hospital is sometimes required and fetal heart rate monitoring is achieved by cardiotocography, standard obstetric monitoring of the fetal heart rate variability via Doppler ultrasound. This monitoring method may be inaccurate in the case of high, low, or irregular heart rates, can be

received
January 1, 2015
accepted after revision
April 30, 2015
published online
September 9, 2015

DOI <http://dx.doi.org/10.1055/s-0035-1558401>.
ISSN 2157-7005.

Copyright © 2015 by Thieme Medical Publishers, Inc., 333 Seventh Avenue, New York, NY 10001, USA.
Tel: +1(212) 584-4662.

License terms



cumbersome to an expectant mother, and may require frequent repositioning to maintain fetal signal.

Fetal electrocardiography has the potential to be a more cost-effective and accurate method of fetal rate and rhythm assessment. Obstacles to fetal electrocardiographic assessment of rate and rhythm include interference from the maternal cardiac signal along with maternal uterine and abdominal muscle-related electrical artifact. Although previous devices had difficulty overcoming these obstacles, recent advances have led to a greater degree of success in fetal heart rate and rhythm assessment.⁵⁻¹⁰ The Monica AN24 (Monica Healthcare Ltd., Nottingham, United Kingdom) is a relatively new maternal transabdominal fetal electrocardiographic monitor. The device is widely available and approved for clinical use of fetal heart rate assessment in Europe and the United States. It acquires fetal heart rate during labor and in the antenatal period in normal fetuses, in cases with high maternal body mass index, as well as remotely with the expectant mother at her home.¹¹⁻¹⁵ The device is not designed to discern individual P waves in fetuses with normal sinus rhythm, but its ability to discern P waves in the cases of arrhythmias has not been previously tested. To determine feasibility of fetal heart rate monitoring with the Monica AN24, we report a series of fetal arrhythmia cases with heart rates assessed using this monitor. Although the device is not designed to perform rhythm assessment, we attempted to discern fetal cardiac rhythm as well.

Methods

This study was approved by the Columbia University Medical Center Institutional Review Board. Between 2008 and 2012, maternal subjects were recruited after a fetal echocardiogram confirmed the diagnosis of a fetal arrhythmia. Fetal electrocardiograms (fECGs) were recorded using the Monica AN24 fetal monitor. The method of signal acquisition and

processing has been described in detail.^{13,16} When possible, repeated fECGs were performed throughout gestation period. fECGs were included in the analysis when fetal arrhythmia was demonstrated by either fetal echocardiogram on the same day or by fetal echocardiograms performed before and after the fECG.

The duration of fECG recordings varied based on maternal subject availability, with an ideal minimum recording time of 45 minutes. Data were processed utilizing the Monica DK v1.8 software program (Monica Healthcare Ltd.) which provides the following two modes of data viewing: (1) as an electrocardiographic tracing collected at 300 Hz, and (2) as a review of the fetal heart rate in a style similar to standard obstetric cardiotocography monitors. In the fECG mode, the electrocardiographic tracing contains the high resolution fetal and maternal cardiac signal along with a separate fetal tracing with the maternal signal filtered out (→Fig. 1). In the fetal heart rate mode, calculated beat-to-beat fetal and maternal heart rates are displayed in graph format (→Fig. 2). At the time of our analysis, the software program detected fetal beats at a limited range of rates (between 60 and 200 beats per minute [bpm]) precluding automated analysis when fetal heart rates were outside of this range. Manual analysis was performed on all tracings by means of physician review of the raw and filtered fetal signal to look for fetal QRS complexes and assign ventricular rate. To perform limited rhythm assessment, we determined whether the heart rate was regular or irregular, and we also determine whether there were identifiable P waves. If P waves were identifiable, then the rhythm was analyzed and reported.

The quality of fetal QRS acquisition on the electrocardiographic tracing was rated for each fECG. High-quality recordings were defined as clearly discernible individual fetal QRS complexes detected in at least 10% of the tracing. This definition was used because we expected relatively low rates of heart rate acquisition in the short term, ambulatory setting

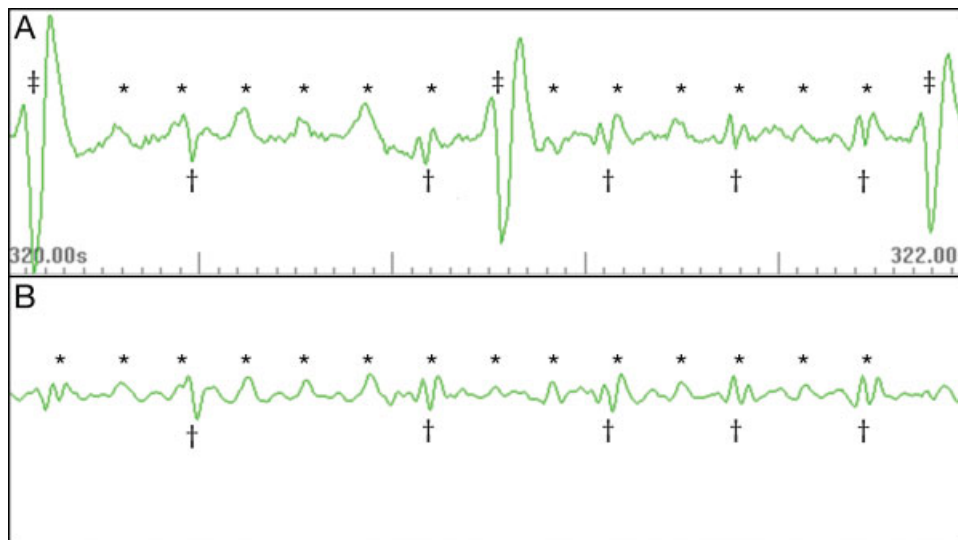


Fig. 1 Electrocardiographic tracing mode in Monica DK v1.8 demonstrating fetal atrial flutter. There is an atrial rate of 500 beats per minute and variable atrioventricular conduction. (A) The top panel represents unfiltered signal with maternal forces being dominant; (B) The bottom panel represents a filtered fetal tracing with maternal signal subtracted out. *Fetal P waves; †fetal QRS; ‡maternal QRS.

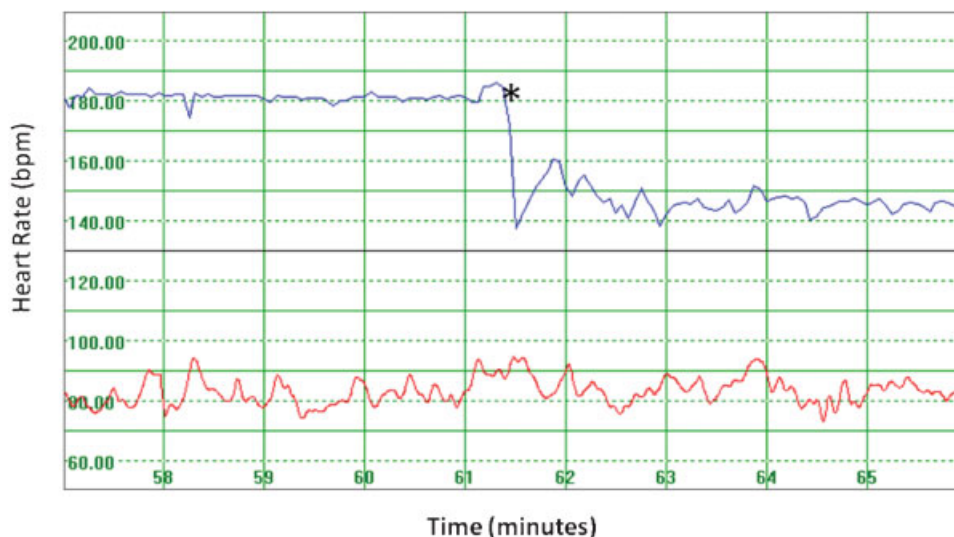


Fig. 2 Fetal heart rate monitoring mode in Monica DK v1.8 in a case of atrial flutter. The higher tracing represents the fetal heart rate. The lower tracing represents the maternal heart rate. Time at which the fetal rhythm converts from atrial flutter with 2:1 atrioventricular conduction to normal sinus rhythm.

in comparison with the high rate of fetal heart rate acquisition that has been previously described during longer term recordings.¹³ Medium-quality recordings were defined as having intermittently discernable fetal signal for less than 10% of the tracing. Poor-quality recordings had no clearly demonstrated fetal signal. Fetal echocardiogram reports were reviewed and the cardiac rate and rhythm were reported. In addition, medical records of subjects were retrospectively reviewed to determine the details of the pregnancy history, medical interventions, and outcomes for each case.

Results

Subject and Recording Characteristics

Over the 4-year study period, 13 subjects underwent one or more fetal echocardiograms that demonstrated fetal arrhythmia and had a fECG performed. ►Table 1 outlines the clinical summary of each subject. A total of 20 fECGs were performed. ►Table 2 reviews the findings on fetal echocardiogram and fECG in each case. The average recording time was 44 minutes with a range of 6 minutes to 115 minutes. High-quality recordings were obtained in 10 cases, medium-quality recordings were obtained in 3 cases, and poor-quality recordings were obtained in 7 cases. Individual fetal P waves were demonstrated in five of the recordings on the raw electrocardiographic tracing.

Tachycardias

We recorded five fECGs on five subjects with fetal atrial flutter. Three of these tracings were of high quality and demonstrated tachycardia, and the remaining two tracings demonstrated no clear fetal signal. In two of the three high-quality tracings (subject numbers 1 and 12), P waves were intermittently identified at a more rapid, regular rate (►Fig. 1). In one tracing, the fECG initially revealed tachycardia associated with atrial flutter and subsequently

demonstrated spontaneous conversion back to sinus rhythm 61 minutes into monitoring (►Fig. 2). In another subject diagnosed by fetal echocardiogram to have atrial flutter (subject number 5), a subsequent fetal echocardiogram demonstrated atrial fibrillation. The fECG performed at the time the fetus was in atrial fibrillation demonstrated intermittently identifiable QRS complexes with a highly variable rate of 136 to 250 bpm, but because clear QRS complexes were only rarely visible, the rhythm could not be determined definitively from the fECG. One tracing from a fetus in intermittent supraventricular tachycardia (subject number 8) did not demonstrate a clear fetal signal.

Bradycardias

We enrolled three patients with fetal heart block and recorded 5, 3, and 1 fECGs per subject. Of these nine tracings, seven demonstrated QRS complexes at a bradycardic rate and the remaining two were technical failures with no fetal signal. Three fECGs obtained from subject number 6 had intermittently identifiable P waves that were regular, at a normal rate, and dissociated from fetal QRS (►Fig. 3). This subject was described in a previous case report by our group.⁸ In two recordings obtained from subject number 11, early beats were observed, suggesting rare conduction or premature ventricular contractions not appreciated on the fetal echocardiograms performed on this subject. One tracing of a subject with fetal sinus bradycardia confirmed a regular bradycardia at a rate of 100 bpm.

Premature Atrial Contractions

We enrolled three subjects with premature atrial contractions and obtained one fECG on each patient. Of the three, one demonstrated intermittent fetal QRS complexes in a regular pattern without evidence of premature P waves and the other two were technical failures.

Table 1 Clinical summary of cases

Subject	Fetal arrhythmia diagnosis	Fetal comorbidities	Maternal medications for fetal arrhythmia	Outcome of fetus	Neonatal rhythm
1	Atrial flutter	Bilateral renal pyelectasis	Digoxin, propranolol	Unavailable	Atrial flutter resolved by 33 wk GA
2	Sinus bradycardia	None	None	Live birth at FT	NSR
3	PACs	None	None	Unavailable	Unavailable
4	PACs	Ureterocele	None	Live birth at FT	NSR
5	Atrial flutter/fibrillation	Thickened tricuspid valve	Propranolol	Live birth at FT	NSR
6	Advanced 2 degree heart block	HLHS with restrictive atrial septum	None	Live birth at FT; expired DOL 3	Advanced 2 degree heart block
7	Complete heart block	IUGR, trace abdominal ascites	Prednisone	Fetal demise (29 wk GA)	N/A
8	SVT	Tricuspid stenosis, PS, hypoplastic RV	Digoxin	Live birth at FT	NSR
9	SVT, PACs	IUGR	Digoxin, propranolol	Premature live birth (34 wk GA)	NSR
10	Atrial flutter	None	Digoxin, sotalol, amiodarone	Live birth at FT	Intermittent SVT
11	Complete heart block	Dilated RV, decreased RV function	Terbutaline, dexamethasone	Live birth at FT	Complete heart block
12	Atrial flutter	Tricuspid stenosis, VSD, hypoplastic RV	Digoxin	Live birth at FT	NSR; flutter resolved by 37 wk GA
13	Atrial flutter	Small pericardial effusion, decreased RV function, mild TR	Digoxin	Live birth at FT	NSR; flutter resolved by 34 wk GA

Abbreviations: DOL, day of life; FT, full term; GA, gestational age; HLHS, hypoplastic left heart syndrome; IUGR, intrauterine growth restriction; NSR, normal sinus rhythm; PAC, premature atrial contraction; PS, pulmonic stenosis; RV, right ventricle; SVT, supraventricular tachycardia; TR, tricuspid regurgitation; VSD, ventricular septal defect.

Note: This table summarizes the clinical history of each subject including the maternal history, medical details of the pregnancy, and fetal medical and arrhythmia history.

Discussion

Fetal electrocardiography has the potential to be a relatively easy and cost-effective modality that can monitor the fetal heart rate and directly measure fetal cardiac rhythm with high temporal resolution. This resolution of the signal could allow for fine grain analyses of the fECG waveform, previously available only with intrapartum scalp electrodes. A previous large sample study utilizing the Monica AN24 to monitor fetuses with normal cardiac rhythm showed > 90% success in fetal heart rate acquisition during overnight monitoring.¹³ That study demonstrated the least success in fetal heart rate acquisition in the 26- to 34-week gestational age period, putatively because of the increased vernix during this period of fetal development. In addition, there was a much higher success rate observed between 12 AM and 6 AM, likely during maternal sleep. Our experience has shown tracing quality improves over the course of the recording period, which we believe may be because of the maternal relaxation and diminishment of electrical interference from maternal

abdominal muscle tone. On the basis of this experience and reports from other groups, we have since instituted the practice of overnight recordings.

In the cases described earlier, among 11 tracings obtained at the expected high yield gestational ages (< 26 or > 34 weeks), 9 were of high quality and readily demonstrated the fetal heart rate. One of the two low-quality recordings taken at greater than 34 weeks was only 6 minutes in duration, which is likely insufficient time to make a proper assessment. Among the nine recordings taken during the suboptimal gestation of 26 to 34 weeks, six were technical failures but three nonetheless were consistent with the previously diagnosed arrhythmia: one case of atrial flutter, one case of atrial fibrillation, and one case of heart block. In one fetus with atrial flutter (subject number 12), the fECG demonstrated the time spent in arrhythmia and the exact moment of spontaneous conversion to sinus rhythm. Although tracings were acquired for research purposes and did not guide clinical management, this case demonstrates the potential clinical utility of the longer monitoring period allowed by fECG as

Table 2 Fetal cardiac rate and rhythm

Subject	GA (wk)	Rhythm on fECHO	Rate on fECHO (bpm)	fECG recording time (min)	Quality of QRS on fECG	P Waves on fECG	Rhythm on fECG	Rate on fECG (bpm)
1	31	Atrial flutter	A: 418-440, V: 209-220	56	High	Yes	Atrial flutter	A: 500, V: 100-250
2	20	Sinus bradycardia	V: 100	28	High	No	Regular bradycardia	V: 100
3	36	PACs	V: 80-130	6	Medium	No	Regular rhythm, no PACs	V: 120
4	36	PACs	V: 136	46	Poor	No	^a	^a
5	30	Atrial flutter	A: 480, V: 240-480	43	Poor	No	^a	^a
6	33	Atrial fibrillation	A: 489-500, V: 120-240	37	Medium	No	Variable rate	V: 136-250
	29	Advanced 2-degree heart block	A: 140, V: 70	28	Poor	No	^a	^a
	31	Advanced 2-degree heart block	V: 51-66	38	Medium	No	Irregular bradycardia	V: 42-47
	34	Advanced 2-degree heart block	V: 48-60	36	High	No	Irregular bradycardia	V: 47-60
	35	No fECHO	N/A	46	High	Yes	Advanced 2-degree heart block	A: 130, V: 48-107
	37	Advanced 2-degree heart block	V: 51	49	High	Yes	Advanced 2-degree heart block	A: 142, V: 48-107
7	25	Complete heart block	A: 111-127, V: 81-83	38	High	No	Regular bradycardia	V: 82
8	27	Intermittent SVT	SVT-V: 300; NSR-V: 150	80	Poor	No	^a	^a
9	30	PACs	Rate not documented	41	Poor	No	^a	^a
10	29	Atrial flutter	A: 460, V: 230	59	Poor	No	^a	^a
11	22	Complete heart block	A: 120-158, V: 52	56	High	Yes	Complete heart block	A: 136-150, V: 52-91
	23	Complete heart block	A: 150, V: 56-58	38	High	No	Regular bradycardia, one 3 beat run of faster rate	V: 57-91
12	26	Complete heart block	A: 140, V: 56-59	38	Poor	No	^a	^a
	34	NSR (atrial flutter on day prior)	A: 333-428, V: 170-180	115	High	Yes ^b	Atrial flutter; conversion to NSR at 61:20 minutes	Flutter-A: 360, V: 180; NSR-V: 135-145
13	34	Atrial flutter	A: 416, V: 208	6	High	No	Regular tachycardia	V: 211

Abbreviations: A, atrial; bpm, beats per minute; fECG, fetal electrocardiogram; fECHO, fetal echocardiogram; GA, gestational age; NSR, normal sinus rhythm; PAC, premature atrial contraction; SVT, supraventricular tachycardia; V, ventricular.

Note: This table describes the fetal rate and rhythm on each fetal echocardiogram and electrocardiogram. Atrial rates are listed when available.

^aNo clear fetal signal

^bp waves demonstrated during atrial flutter, but not while in sinus rhythm.

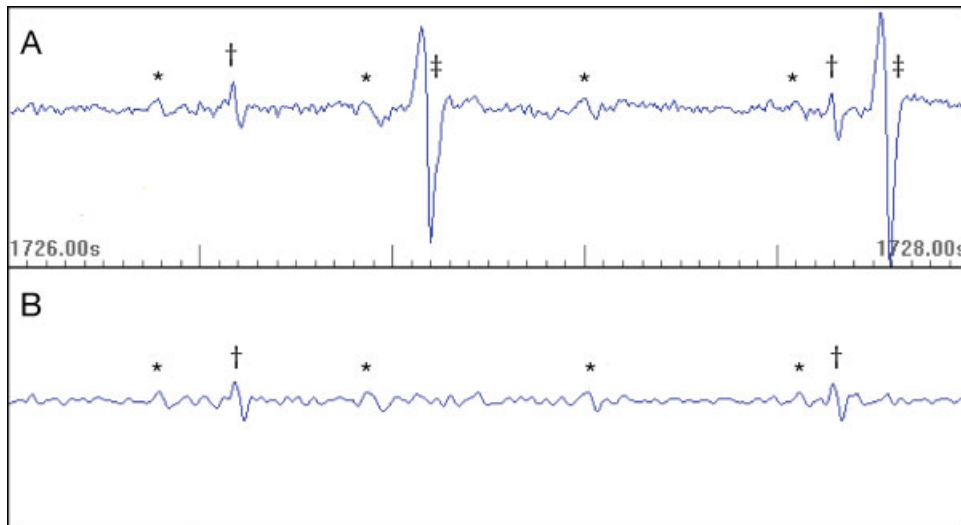


Fig. 3 Electrocardiographic tracing mode in Monica DK v1.8 demonstrating fetal heart block. There is P QRS dissociation with an atrial rate of 132 beats per minute and a ventricular rate of 48 beats per minute. (A) The top panel represents unfiltered signal with maternal forces being dominant; (B) The bottom panel represents a filtered fetal tracing with maternal signal subtracted out. *Fetal P waves; †fetal QRS; ‡maternal QRS.

compared with fetal echocardiography. Fetal electrocardiographic heart rate monitoring could potentially be performed to monitor fetuses with arrhythmias remotely or guide antiarrhythmic dosing adjustments. However, further study of these applications is needed before its use in the clinical setting of arrhythmias.

To characterize fetal cardiac rhythm, it is important to identify P waves in addition to QRS complexes. In normal fetuses, individual fetal P waves are generally not visible on the real-time Monica AN24 tracing, but the fetal P wave is often seen on the signal-average waveform. We hypothesize that this is because of the relatively small electrical signal from the fetal atria compared with the ventricular depolarization, the possible overshadowing of maternal ECG and overfiltering by the software program. We were concerned that this would limit the utility of the fECG for fetal arrhythmia diagnosis. Not surprisingly, individual P waves were not identified in fetuses with predominantly normal P wave and QRS associations, namely, the fetuses with sinus bradycardia and premature atrial contractions. P waves are unlikely to be visualized even on a standard ECG in the cases of reentrant supraventricular tachycardia with 1:1 atrioventricular conduction and atrial fibrillation, and thus were not expected to be discernable on fECG. However, somewhat unexpectedly, in 5 of the 14 cases with atrial flutter or advanced heart block, fetal P waves were demonstrated on the real-time tracing. It is possible that this is because of the abnormal P wave to QRS association reducing the overshadowing of QRS complexes adjacent to P waves, in addition to factors specific to each arrhythmia. In atrial flutter, there may be a larger electrical signal produced by the “fluttering” fetal atria. In heart block, the paucity of fetal QRS complexes may allow for better visualization of fetal P waves. Of note, all five of the tracings that demonstrated P waves were from the higher clarity gestational ages.

This case series was not designed to determine the reliability or validity of the Monica AN24 fetal electrocardiographic monitor. The results do not support its use in the primary diagnosis of arrhythmia. Further study, ideally with automated analysis of slow and fast heart rates and with overnight monitoring, is warranted to determine whether there is a role for this device in fetal heart rate monitoring in the case of arrhythmias.

Conclusion

In this case series of 13 fetuses with arrhythmia documented on fetal echocardiogram, 20 fECGs were performed. Overall, 13 of these tracings demonstrated identifiable QRS complexes and 5 demonstrated identifiable P waves. The lowest quality tracings were concentrated in the 26- to 34-week gestational age group. Lengthening recording duration, including overnight studies, may improve fetal ECG signal detection during this difficult gestational period. Further study is warranted to determine whether this device can be used to reliably monitor the fetal heart rate in the case of fetal arrhythmias.

Acknowledgments

I. A. Williams received support from Grant Number K23HD061601 from the National Institute of Child Health & Human Development of the National Institutes of Health. W. P. Fifer received support from Grant Number R37 HD032774. This publication was also supported by the National Center for Advancing Translational Sciences, National Institutes of Health, through Grant Number UL1 TR000040. The contents of this article are solely the responsibility of the authors and do not necessarily represent the official views of the National Institutes of Health.

References

- 1 Southall DP, Richards J, Hardwick RA, et al. Prospective study of fetal heart rate and rhythm patterns. *Arch Dis Child* 1980;55(7):506–511
- 2 Srinivasan S, Strasburger J. Overview of fetal arrhythmias. *Curr Opin Pediatr* 2008;20(5):522–531
- 3 Strasburger JF, Cheulkar B, Wakai RT. Magnetocardiography for fetal arrhythmias. *Heart Rhythm* 2008;5(7):1073–1076
- 4 Maeno Y, Hirose A, Kanbe T, Hori D. Fetal arrhythmia: prenatal diagnosis and perinatal management. *J Obstet Gynaecol Res* 2009;35(4):623–629
- 5 Hon EH. The electronic evaluation of the fetal heart rate; preliminary report. *Am J Obstet Gynecol* 1958;75(6):1215–1230
- 6 Taylor MJO, Smith MJ, Thomas M, et al. Non-invasive fetal electrocardiography in singleton and multiple pregnancies. *BJOG* 2003;110(7):668–678
- 7 Sato N, Hoshiai T, Ito T, et al. Successful detection of the fetal electrocardiogram waveform changes during various states of singletons. *Tohoku J Exp Med* 2011;225(2):89–94
- 8 Narayan HK, Fifer W, Carroll S, Kern J, Silver E, Williams IA. Hypoplastic left heart syndrome with restrictive atrial septum and advanced heart block documented with a novel fetal electrocardiographic monitor. *Ultrasound Obstet Gynecol* 2011;38(4):472–474
- 9 Gardiner HM, Belmar C, Pasquini L, et al. Fetal ECG: a novel predictor of atrioventricular block in anti-Ro positive pregnancies. *Heart* 2007;93(11):1454–1460
- 10 Fujimoto Y, Matsumoto T, Honda N, et al. Prenatal diagnosis of long QT syndrome by non-invasive fetal electrocardiography. *J Obstet Gynaecol Res* 2009;35(3):555–561
- 11 Reinhard J, Hayes-Gill BR, Schiermeier S, et al. Intrapartum signal quality with external fetal heart rate monitoring: a two way trial of external Doppler CTG ultrasound and the abdominal fetal electrocardiogram. *Arch Gynecol Obstet* 2012;286(5):1103–1107
- 12 Reinhard J, Hayes-Gill BR, Yi Q, Hatzmann H, Schiermeier S. Comparison of non-invasive fetal electrocardiogram to Doppler cardiocogram during the 1st stage of labor. *J Perinat Med* 2010;38(2):179–185
- 13 Graatsma EM, Jacod BC, van Egmond LAJ, Mulder EJJ, Visser GHA. Fetal electrocardiography: feasibility of long-term fetal heart rate recordings. *BJOG* 2009;116(2):334–337, discussion 337–338
- 14 Graatsma EM, Miller J, Mulder EJ, Harman C, Baschat AA, Visser GH. Maternal body mass index does not affect performance of fetal electrocardiography. *Am J Perinatol* 2010;27(7):573–577
- 15 Rauf Z, O'Brien E, Stampalija T, Ilioniu FP, Lavender T, Alfirevic Z. Home labour induction with retrievable prostaglandin pessary and continuous telemetric trans-abdominal fetal ECG monitoring. *PLoS ONE* 2011;6(11):e28129
- 16 Piéri JF, Crowe JA, Hayes-Gill BR, Spencer CJ, Bhogal K, James DK. Compact long-term recorder for the transabdominal foetal and maternal electrocardiogram. *Med Biol Eng Comput* 2001;39(1):118–125