

Acute Fatty Liver of Pregnancy and its Differentiation from Other Liver Diseases in Pregnancy

Die akute Schwangerschaftsfettleber und die Abgrenzung zu anderen Lebererkrankungen der Gestationsperiode

Authors

J. T. Maier¹, E. Schalinski¹, C. Häberlein¹, U. Gottschalk², L. Hellmeyer¹

Affiliations

¹ Abteilung für Gynäkologie und Geburtshilfe, Vivantes Klinikum im Friedrichshain, Berlin

² Abteilung für Gastroenterologie, Vivantes Klinikum im Friedrichshain, Berlin

Key words

- acute fatty liver of pregnancy
- HELLP syndrome
- premature birth
- high-risk pregnancy
- disseminated intravascular coagulation
- maternal mortality

Schlüsselwörter

- akute Schwangerschaftsfettleber
- HELLP-Syndrom
- Frühgeburt
- Hochrisikoschwangerschaft
- disseminierte intravasale Gerinnung
- mütterliche Sterblichkeit



Deutschsprachige

Zusatzinformation unter:
www.thieme-connect.de/ejournals/gebfra

received 30.3.2015

revised 29.5.2015

accepted 24.6.2015

Bibliography

DOI <http://dx.doi.org/10.1055/s-0035-1557818>
 Geburtsh Frauenheilk 2015; 75: 844–847 © Georg Thieme Verlag KG Stuttgart · New York · ISSN 0016-5751

Correspondence

Dr. med. **Josefine Theresia Maier**

Vivantes Klinikum im Friedrichshain
 Abteilung für Gynäkologie und Geburtshilfe
 Landsberger Allee 49
 10249 Berlin
Josefine.Maier@gmail.com

Abstract



Background: There are a number of threatening liver diseases that occur during pregnancy. Acute fatty liver of pregnancy is a rare disease associated with high maternal and foetal mortality.

Case Report: We report on a young gravida 1 woman who presented to our level 1 perinatal centre in the 36+5 week of pregnancy with an isolated elevation of transaminases together with diffuse upper abdominal complaints. After comprehensive diagnostic work-up we performed an emergency delivery by Caesarean section. This was followed by interdisciplinary management.

Discussion: The differentiation from other liver diseases seems not to be obvious in all cases. Here we consider the following differential diagnoses: hyperemesis gravidarum, intrahepatic gestational cholestasis, preeclampsia, HELLP syndrome.

Conclusion: Rapid diagnosis and delivery as well as interdisciplinary aftercare are necessary in order to reduce maternal and foetal mortality.

Zusammenfassung



Hintergrund: Es gibt eine Reihe von bedrohlichen Lebererkrankungen in der Schwangerschaft. Die akute Schwangerschaftsfettleber ist eine seltene Erkrankung, assoziiert mit einer hohen kindlichen und mütterlichen Sterblichkeit.

Fallbericht: Wir berichten über eine junge Primigravida, die sich 36+5 SSW in unserem Perinatalzentrum Level 1 mit isolierter Erhöhung der Transaminasen sowie diffusen Oberbauchbeschwerden vorstellte. Nach eingehender Diagnostik erfolgte die eilige Entbindung per Sectio. Die Patientin wurde im Anschluss interdisziplinär betreut.

Diskussion: Die Unterscheidung zu anderen Lebererkrankungen der Schwangerschaft erscheint nicht immer offensichtlich. Wir gehen hier auf folgende Differenzialdiagnosen zur Abgrenzung ein: Hyperemesis gravidarum, intrahepatische Schwangerschaftscholestase, Präeklampsie, HELLP-Syndrom.

Zusammenfassung: Um die Morbidität und Mortalität von Mutter und Kind gering zu halten, bedarf es einer zügigen Diagnostik und Entbindung sowie interdisziplinärer Betreuung.

Background



A number of liver diseases can occur during pregnancy and some of them may be accompanied with severe consequences for mother and baby. They often have very similar presentations. Herein we report on a case of acute fatty liver of pregnancy that is associated with a high maternal and foetal mortality (maternal mortality 18%, foetal mortality 23% [1]). Typically this disease is often diagnosed too late [8]. Because of the high mortality, an early diagnosis and prompt interdisciplinary therapy are essential.

Case Report



The 28-year-old gravida 1 was referred by her gynaecologist to our level 1 perinatal centre in the 36+4 week of pregnancy with unspecific upper abdominal symptoms and the suspicion of HELLP syndrome. The previous course of the pregnancy was unremarkable. At admission all vital parameters were in the normal range. Subjectively and apart from mild oedemas of the lower extremities the patient did not feel ill. The CTG was normal. On ultrasound an appropriately for age developed foetus (estimated weight 3156 g, 73th percentile) as well as an unremarkable anterior placenta and

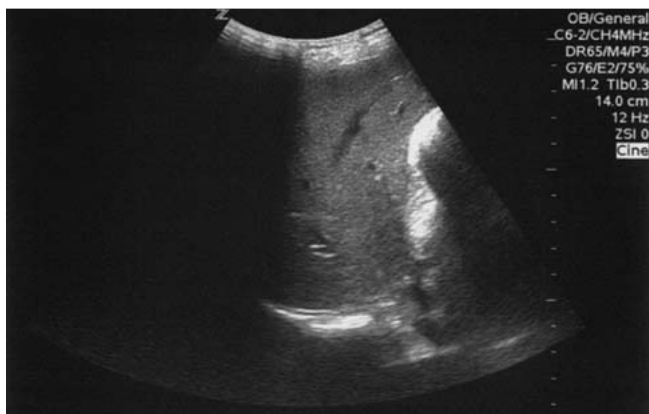


Fig. 1 Upper abdominal ultrasound with visualisation of the liver. Echo-rich internal pattern with rounded liver margins.

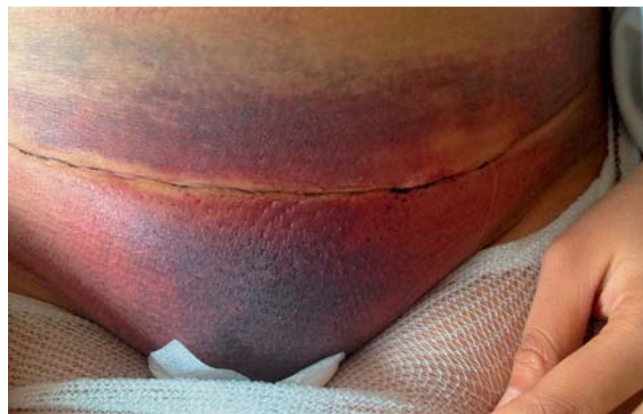

Fig. 2 Haematoma in the region of the laparotomy scar on the third postoperative day after Caesarean section. Further haematomas on arms and legs.

normal amount of amniotic fluid were seen. The Doppler scan did not show any pathological findings except for a borderline elevated resistance in the right uterine artery with an intimated notch. The blood picture was dominated by an isolated 30-fold elevation of the transaminases (Table 1).

Diagnostics, therapy and course

The patient was admitted for further diagnostic work-up. Her vital parameters were stable and the CTG control was, on the whole, unremarkable. Further laboratory samples were taken to follow the course and for further diagnostic work-up (hepatitis of infectious/viral/autoimmune origin). The further increase in transaminases was highly remarkable as was also the markedly elevated D-dimer. The INR was in the upper part of the normal range, AT3 was markedly reduced (Table 1). Retention parameters were slightly elevated (creatinine elevated, urea and electrolytes as well as glucose normal), urinary secretion was inconspicuous. Upper abdominal ultrasound demonstrated a diffuse echo-intense liver parenchyma, and no ascites (Fig. 1). Thus there was the urgent suspicion of an acute fatty liver of pregnancy (upper abdominal complaints, elevated transaminases, coagulopathy, sonographic steatosis hepatitis, furthermore the increasing retention parameters). A primary Caesarean section was promptly carried out under spinal anaesthesia in the 36 + 6 week

of pregnancy. A baby boy, 2990 g, Apgar 9/9/10 in cephalic presentation was delivered. The intraoperative loss of blood was minimal. The course of the operation was altogether unremarkable. After surgery the patient was closely monitored on the ICU. A transfusion of AT3 was undertaken. During the monitoring a recurrent hypoglycaemia was noticed but could be easily compensated. In the further course the patient's circulation was stable and she could be transferred with her baby to the normal ward. Conspicuous were pronounced haematomas, especially in the region of the Caesarean scar (Abb. 2) as well as on her arms and hands. The laboratory values returned to normal and the haematomas receded in the further course of time. The patient and her baby were released on the 5th postoperative day. They were followed up as outpatients in a hepatology centre.

Discussion

Differential diagnoses of liver diseases during pregnancy

Liver diseases complicate the courses of ca. 3% of all pregnancies [7]. Some diseases are accompanied by elevated transaminases in the gestational period, some of them are more threatening than others. The correct diagnosis is not always obvious so that a differentiation from other diseases is required. Table 2 lists the

Table 1 Laboratory investigations, pathological values are indicated by bold type.

	Day of admission	preoperative	postoperative	1st postoperative day	Normal range
Hb (g/dL)	12.6	13.7	10.9	11.9	12.0–15.6 g/dL
Thrombocytes (/nL)	157	148	110	116	150–370/nL
Fibrinogen (g/L)		2.86	1.84	2.27	1.6–4.0 g/L
AT3 (%)		36	23	66	80–120%
D-dimer [mg/L]		9.89	10.83	9.04	< 0.5 mg/L
INR	1.18	1.23	1.57	1.32	0.9–1.25
aPTT (sec)	36.8	74.4	42.1	44.7	26.0–40.0
GOT/AST (U/L)	945	1160	822	638	< 35 U/L
GPT/ALT (U/L)	1189	1340	969	823	< 31 U/L
Bilirubin (mg/dL)	0.9	1.02	0.8		< 1.2 mg/dL
LDH (U/L)		1146	786	536	135–214 U/l
Creatinine (mg/dL)		1.37	1.35	1.34	0.50–0.90 mg/dL
Urea (mg/dL)		31		17	17–48 mg/dL
Glucose (mg/dL)			75 (not fasted)	139 (not fasted)	74–106 mg/dL (fasted)

Table 2 Differential diagnoses of acute fatty liver of pregnancy. IUFD =intrauterine foetal death.

	Symptoms	Diagnosis	Therapy
Hyperemesis gravidarum Incidence: 0.3–2% [10]	severe persisting vomiting, above all in the 1st trimester associated with liver disease, especially elevated transaminases [2]	poor general condition, vomiting, nausea ± dehydration hypokalaemia hyponatraemia possibly elevated transaminases [3]	i. v. fluid substitution antiemetics possibly parenteral feeding
Intrahepatic cholestasis of pregnancy Incidence: 0.2–2% [9]	3rd trimester pruritus, steatorrhoea, malabsorption, risk of IUFD [9]	elevated bile acids (fasting > 10 µmol/L) pruritus	induction of labour from 37 + 0 week of pregnancy, depending on bile acids, ursodeoxycholic acid
Pre-eclampsia/eclampsia Incidence: 5% [8]	pre-eclampsia = proteinuria + hypertension late 2nd trimester/3rd trimester [8]	hypertension, oedema, proteinuria, convulsive fits, renal failure, pulmonary oedema	magnesium, beta-blockers, methyldopa, control of blood pressure, early delivery, intensive care monitoring
HELLP syndrome Incidence: 1–6% [8]	HELLP syndrome = haemolysis, elevated liver enzymes, low platelet count late 2nd trimester/3rd trimester	upper abdominal complaints, vomiting, nausea in part overlap with symptoms of pre-eclampsia	delivery, if needed magnesium, for hypertension blood pressure control, intensive care unit monitoring

most important differential diagnoses of liver diseases during pregnancy.

Hyperemesis gravidarum, occurring mostly in the first trimester, can be accompanied by an elevation of the transaminase [3]. **Intrahepatic cholestasis of pregnancy**, a disease of the late second and third trimesters, is defined by pruritus and elevated bile acids (sampled in the fasted state) [9]. This disease is associated with an increased risk for a negative neonatal outcome or, respectively, intrauterine foetal death so that, in some clinics, labour is induced already from the 37 + 0 week of pregnancy [9]. However, there is no actual evidence to support this [9]. **Pre-eclampsia** is considered to be the most frequent cause of functional liver disorders. Research results suggest a two-stage pathogenesis. Firstly, there is an incorrect placentation with resulting placental hypoperfusion. In some patients as a second stage a multisystem disease with the known symptoms of hypertension and proteinuria develops [8]. Timely delivery, adequate antihypertensive therapy together with magnesium as prophylaxis against eclamptic seizures are the most important therapeutic strategies. **HELLP syndrome** overlaps in part with the symptoms of and therapeutic options for pre-eclampsia (▶ **Table 2**). In addition, infectious, viral and autoimmune forms of hepatitis have to be considered. Furthermore, the transaminase elevation may have drug-induced or toxic causes.

Acute fatty liver of pregnancy

Background

With a prevalence of 1/7000–16000 births acute fatty liver of pregnancy is a rare but life-threatening disease [5]. A maternal mortality of 18% and an infant mortality of 23% are mentioned in the literature [1].

Pathogenesis

Acute fatty liver of pregnancy goes hand in hand with an accumulation of fat vesicles in the liver leading to an impairment of normal liver functions [4]. This is actually a mitochondrial hepatopathy caused by defective fatty acid oxidation in the mitochondria [8]. The disease occurs mostly in the last trimester, presumably caused by the increased metabolism of fatty acids to supply energy in this gestational period [8].

Genetic investigations have shown that acute fatty liver of pregnancy and other liver diseases occur above all when the foetus is homozygous or compound heterozygous for an enzyme defect in

fatty acid oxidation (FAO). In particular, the enzyme LCHAD (long chain 3 hydroxyl-acyl-CoA dehydrogenase) is affected [12,13]. Further enzyme defects have been identified in the region of the oxidation of short and medium chain fatty acids [14]. It is assumed that the accumulation of foetal intermediates of fatty acid oxidation (3-hydroxy fatty acid acylcarnitine) directly damage the maternal liver [14]. The mother is a heterozygous carrier of this mutation and passes it on to the foetus in an autosomal recessive inheritance. There is an eighteen-fold higher risk for acute fatty liver of pregnancy when an FAO defect is present [14].

Diagnostics

One study has shown that acute fatty liver of pregnancy can be mistaken for, above all, HELLP syndrome [11]. The Swansea criteria for the diagnosis of acute fatty liver of pregnancy are listed in ▶ **Table 3**. The symptoms range from vomiting, abdominal complaints and icterus through to encephalopathy and ascites [8]. Typical findings indicative of acute fatty liver of pregnancy are: isolated elevation of transaminases, hypoglycaemia, pathological INR, commencing disseminated intravascular coagulation [6], renal failure, hyperuricaemia and leukocytosis [8]. On ultrasound a diffuse fatty liver and, in some cases, ascites are seen. The gold standard is liver biopsy which exhibits a diffuse/perivenular micro-

Table 3 Swansea criteria for the diagnosis of acute fatty liver of pregnancy [8]. At least 6 of 14 criteria in the absence of alternative explanations must be present in order to secure the diagnosis.

Symptoms	<ul style="list-style-type: none"> ▶ abdominal complaints ▶ vomiting ▶ polydipsia/polyuria (as sign of hypoglycaemia) ▶ encephalopathy
Laboratory parameters	<ul style="list-style-type: none"> ▶ hyperbilirubinaemia ▶ elevation of transaminases ▶ hypoglycaemia ▶ pathological INR/commencing disseminated intravascular coagulopathy ▶ renal failure ▶ hyperuricaemia ▶ hyperammonaemia (due to urea cycle disorders) ▶ leukocytosis
Ultrasound/liver biopsy	<ul style="list-style-type: none"> ▶ fatty liver, ascites ▶ diffuse/perivenular microvesicular accumulation of fat vesicles

vesicular accumulation of fat vesicles [8]. However, in the case of an obstetric emergency where prompt action is necessary, this is contraindicated.

Therapy

When there is a suspicion of acute fatty liver of pregnancy prompt delivery by Caesarean section should be performed. Vaginal delivery may be considered in cases with only mild symptoms since the risk of abdominal bleeding is then lower [8]. Exact comparative studies are not available for such cases. There is often a marked clinical and laboratory chemical improvement after birth. This may be due to delivery of the foetus and placenta and thus to a marked reduction of accumulating fatty acids.

Interdisciplinary management of the patient and her baby by a team comprising a gynaecologist, hepatologist, intensive care physician, haematologist, transfusion physician, nephrologist and neonatologist should be assured. Particular attention must be paid to coagulation and, if necessary, coagulation factors should be substituted. The patient should receive post-partum oxytocin i.v. In the case of a haemorrhage bilateral ligation of the uterine arteries may be considered. Severe hypoglycaemia often occurs within the framework of catabolic stress. Ketogenesis is impaired by the FAO defect and less energy may be available. The glucose level should be closely monitored and if necessary corrected. The transaminase levels generally return to normal within a few days [8], only rarely is a liver transplantation necessary.

The baby should be closely monitored by the neonatologist. For the baby there is a higher risk of hepatic encephalopathy, sudden infant death syndrome, myopathy, cardiomyopathy and arrhythmia [8]. Follow-up of mother and baby in a hepatology centre is recommended.

Conclusion

Acute fatty liver of pregnancy is a rare but serious disease of the late gestation period with higher mortality for both mother and baby. It is not always easy to differentiate this disease from other liver diseases of pregnancy. Cardinal symptoms are acute abdominal complaints as well as vomiting. Preeclampsia may be present in parallel. In the course of the disease liver failure, coagulopathy and encephalopathy and even death may occur. Prompt delivery

as well as interdisciplinary intensive care and follow-up for both mother and baby are necessary.

It is recommended that pregnant women who had suffered from liver diseases in previous pregnancies should be monitored closely. Transaminases, coagulation and glucose as well as, if necessary, carnitine and acylcarnitine should be determined regularly when there is a suspicion of an FAO defect.

Conflict of Interest

None.

References

- 1 Ahmed KT, Almashhrawi AA, Rahman RN *et al*. Liver diseases in pregnancy: diseases unique to pregnancy. *World J Gastroenterol* 2013; 19: 7639–7646
- 2 Wong HY, Tan JY, Lim CC. Abnormal liver function tests in the symptomatic pregnant patient: the local experience in Singapore. *Ann Acad Med Singapore* 2004; 33: 204–208
- 3 Abell TL, Riely CA. Hyperemesis gravidarum. *Gastroenterol Clin North Am* 1992; 21: 835–849
- 4 Dey M, Kumar R, Narula GK *et al*. Acute fatty liver of pregnancy. *Medical J Armed Forces India* 2014; 70: 392–393
- 5 Reyes H, Sandoval L, Wainstein A *et al*. Acute fatty liver of pregnancy: a clinical study of 12 episodes in 11 patients. *Gut* 1994; 35: 101–106
- 6 Fries D, Streif W. Gerinnungsmanagement in der Intensivmedizin. Berlin, Heidelberg: Springer; 2014: 49–50
- 7 Castro MA, Fasset MJ, Reynolds TB *et al*. Reversible peripartum liver failure: a new perspective on the diagnosis, treatment and cause of acute fatty liver of pregnancy based on 28 cases. *Am J Obstet Gynecol* 1999; 181: 389–395
- 8 Goel A, Jamwal KD, Ramachandran A *et al*. Pregnancy-related liver disorders. *J Clin Exp Hepatol* 2014; 4: 151–162
- 9 Williamson C, Geenes V. Intrahepatic cholestasis of pregnancy. *Obstet Gynecol* 2014; 124: 120–133
- 10 McCarthy FP, Lutomski JE, Greene RA. Hyperemesis gravidarum: current perspectives. *Int J Womens Health* 2014; 6: 719–725
- 11 Goel A, Ramakrishna B, Zachariah U *et al*. How accurate are the Swansea criteria to diagnose acute fatty liver of pregnancy in predicting hepatic microvesicular steatosis? *Gut* 2011; 60: 139–140
- 12 Ibdah JA, Bennett MJ, Rinaldo P. A fatty-acid oxidation disorder as a cause of liver disease in pregnant women. *N Engl J Med* 1999; 340: 1723–1731
- 13 Innes AM, Seargeant LE, Balachandra K. Hepatic carnitine palmitoyl-transferase 1 deficiency presenting as maternal illness in pregnancy. *Pediatr Res* 2000; 47: 43–45
- 14 Browning MF, Levy HL, Wilkins-Haug LE *et al*. Fetal fatty acid oxidation defects in maternal liver disease in pregnancy. *Obstet Gynecol* 2006; 107: 115–120