

# Current Insights into the Pathogenesis of Graves' Ophthalmopathy

Author

R. S. Bahn

Affiliation

Mayo Clinic College of Medicine, Rochester, MN, USA

## Key words

- Graves' disease
- thyroid stimulating hormone
- TSH-receptor antibodies
- IGF-1

## Abstract

Environmental, genetic, and immune factors are at play in the development of the variable clinical manifestations of Graves' ophthalmopathy (GO). Among the environmental contributions, smoking is the risk factor most consistently linked to the development or worsening of the disease. The close temporal relationship between the diagnoses of Graves' hyperthyroidism and GO have long suggested that these 2 autoimmune conditions may share pathophysiologic features. The finding that the thyrotropin receptor (TSHR) is expressed in orbital fibroblasts, the target cells in GO, supported the notion of a common autoantigen. Both cellular and humeral immunity directed against TSHR expressed on orbital fibroblasts likely initiate the disease process. Activation of helper T cells recognizing TSHR peptides and ligation of TSHR by TRAb lead to the secre-

tion of inflammatory cytokines and chemokines, and enhanced hyaluronic acid (HA) production and adipogenesis. The resulting connective tissue remodeling results in varying degrees extraocular muscle enlargement and orbital fat expansion. A subset of orbital fibroblasts express CD34, are bone-marrow derived, and circulate as fibrocytes that infiltrate connective tissues at sites of injury or inflammation. As these express high levels of TSHR and are capable of producing copious cytokines and chemokines, they may represent an orbital fibroblast population that plays a central role in GO development. In addition to TSHR, orbital fibroblasts from patients with GO express high levels of IGF-1R. Recent studies suggest that these receptors engage in cross-talk induced by TSHR ligation to synergistically enhance TSHR signaling, HA production, and the secretion of inflammatory mediators.

received 30.01.2015  
accepted 01.06.2015

## Bibliography

DOI <http://dx.doi.org/10.1055/s-0035-1555762>  
Horm Metab Res 2015;  
47: 773–778  
© Georg Thieme Verlag KG  
Stuttgart · New York  
ISSN 0018-5043

## Correspondence

**R. S. Bahn**  
Professor of Medicine  
Mayo Clinic College of Medicine  
200 First St. SW  
Rochester  
Minnesota  
USA  
Tel.: +1/507/261 1358  
Fax: +1/507/261 1358  
Bahn.rebecca@mayo.edu

## Introduction

Graves' ophthalmopathy (GO), also known as Graves' orbitopathy or thyroid eye disease, is an inflammatory autoimmune disorder [1]. While the majority of patients with this condition experience only mild eye irritation and redness, some 3–5% suffer from more severe disease. Disease manifestations variably include redness and swelling of the conjunctivae and lids, forward protrusion of the globes (proptosis), ocular pain, debilitating double vision, and even sight loss due to compressive optic neuropathy or breakdown of the cornea [2]. From a mechanistic standpoint, these features derive largely from progressive enlargement of the orbital adipose tissues and extra-ocular muscles within the confines of the bony orbit. As the orbital pressure rises, proptosis may develop and venous drainage may be compromised with impairment of

inflammatory mediator efflux. Diplopia in early disease appears to result from active inflammation within the enlarged and edematous muscles. When encountered in late, inactive disease, diplopia likely reflects muscle fibrosis. This chapter will review current insights into the environmental, genetic, and pathobiological mechanisms responsible for orbital tissue remodeling in GO.

## Risk Factors for the Development of GO

Patients with GO are more likely to be women by a 2:1 ratio while men with Graves' disease appear to be at higher risk for the development of severe GO [3]. Racial differences in the prevalence of GO have also been noted with Asians having a lower likelihood of developing the disease than do Caucasians [4]. Genetic studies have identified candidate genes associated with the development of

Graves' hyperthyroidism including the immune regulatory genes, human leukocyte antigen (HLA)-DR $\beta$ 1-Arg74, cytotoxic T lymphocyte antigen (CTLA)-4, PTPN22, and CD40, and the thyroid-related genes thyroglobulin and thyrotropin receptor (TSHR) [5]. However, none of these genes contribute more than a 4-fold increase in risk, are essential for disease development or have been clearly shown to confer separate risk for GO [6]. Overall these findings suggest that Graves' disease has a complex genetic basis with multiple susceptibility alleles that, in combination with epigenetic, post-translational, and environmental factors, predispose to the various disease phenotypes, including the presence of GO [7,8].

Smoking is the risk factor that has most consistently been linked to the development or worsening of GO [9]. It was the primary risk factor identified for GO outcome with an odds ratio among smokers vs. nonsmokers of 5.2 in a recent trial of patients with newly diagnosed Graves' hyperthyroidism treated with either radioactive iodine or antithyroid drugs [10]. Upon post-hoc analysis with a better outcome definition, smoking was found to impart an even higher odds ratio of 9.8. Overall more than 40% of the smokers either developed GO or experienced deterioration in the disease, a rate almost double that seen in nonsmokers. The GO risk relative to active smoking is proportional to the number of cigarettes smoked per day, and former smokers have significantly lower risk than current smokers [11]. The potential impact of secondhand smoke was suggested in a retrospective, questionnaire-based study demonstrating a higher rate of childhood GO in the European countries having the highest prevalence of adult smoking [12]. While *in vitro* studies have shown that both cigarette smoke extract [13] and hypoxia [14] increase hyaluronic acid (HA) production by orbital fibroblasts and that cigarette smoke extract synergizes with interleukin (IL)-1 [13] to enhance adipogenesis in these cells, mechanisms underlying the deleterious impact of smoking in GO (as well as in other autoimmune diseases) are unclear. Clearly important insights into GO pathogenesis lie in better understanding of this association.

Multiple studies have concluded that radioactive iodine (RAI) treatment of Graves' hyperthyroidism negatively impacts the eyes [15,16] and that smoking may represent an additive risk factor in that setting [10]. The association of GO with RAI may be in part explained by the elevated levels of autoantibodies directed against the thyrotropin receptor (TRAb) seen immediately following RAI therapy that remain above pre-RAI levels for approximately a year's time, then gradually decline over the ensuing several years [17]. In contrast, treatment with antithyroid medication or thyroidectomy is generally followed by a gradual decrease, then disappearance of TRAb in 70–80% of patients after 18 months. While the risk of GO development or progression was found in one randomized controlled trial to be 15% for RAI (compared with 3% for antithyroid drug therapy) [15] other studies reported higher risk for RAI at 33% (compared with 10% for antithyroid drugs and 16% for thyroidectomy) [14], and 39% for RAI (compared with 21% for antithyroid drugs) [10]. Risk factors for RAI-induced activation of GO include male sex, advanced age, and shorter time from onset of GO and post-RAI hypothyroidism [18, 19]. The majority of patients developing GO after RAI therapy have mild and transient disease requiring no treatment and glucocorticoids administered concurrently with RAI therapy with tapering over 6–8 weeks may prevent the development or worsening of mild GO [9,20,21]. However, as these studies included only patients with no GO at the time of

RAI or only mild disease, the risk of disease worsening and the potential impact of corticosteroid administration in patients with more than mild disease is unclear. Recent practice guidelines suggest that hyperthyroidism in patients with severe GO be treated with either antithyroid drugs or thyroidectomy [22]. Finally, both hyper- and hypothyroidism have been independently shown to confer increased risk for development or deterioration of GO [9]. Accordingly, initiating early thyroxine replacement to prevent hypothyroidism following RAI therapy or close monitoring of thyroid hormone levels in patients treated with antithyroid medication is advised.

## Cellular Functions and Interactions

The autoimmune nature of GO is evidenced by the presence within the orbit of a perivascular and diffuse infiltration with mononuclear cells, including predominately CD4+ T cells with occasional populations of CD8+ cells, B cells, and macrophages [1,23]. CD4+ T cells were primarily  $\gamma\delta$ T cells, while  $\alpha\beta$ T helper cells were rare [24]. Activation of infiltrating T cells in early disease initiates the secretion of primarily Th1-type cytokines [including interferon (IFN)- $\gamma$ , tumor necrosis factor (TNF)- $\alpha$ , interleukin (IL)-1 $\beta$ , IL-2] whereas in later disease Th2 responses (IL-4, IL-5, IL-10) predominate [25]. Activated T cells additionally produce leukoregulin, a cytokine capable of potent stimulation of hyaluronic acid (HA) or hyaluronan synthesis by GO fibroblasts [21,26].

The enlarged extraocular muscles (predominately the inferior and medial recti) and expanded orbital adipose tissue volume are a consequence of HA accumulation in the muscles and connective tissues and the development of new fat cells (adipogenesis) within the orbital fat [1]. In addition, as HA is a profoundly hydrophilic glycosaminoglycan, the orbital tissues retain water and become very edematous. Evidence from several laboratories suggests that fibroblasts investing the extraocular muscle fibers and residing within the orbital connective tissues are the autoimmune target cells in GO [27–30]. Early studies showed that orbital-infiltrating CD8+ T cells recognize orbital fibroblasts and not eye muscle extracts, and that they respond by proliferation via major histocompatibility complex (MHC) class II and CD40 signaling [28]. Orbital fibroblasts may be classified based on the presence or absence of the cell surface glycoprotein CD90, also known as thymocyte antigen-1 (Thy-1) [31]. Fibroblasts expressing this antigen are abundant in the extraocular muscles. They are capable of copious HA production and can differentiate into myoblasts when treated with transforming growth factor (TGF)- $\beta$ . In contrast, fibroblasts found within the orbital connective tissues are primarily Thy-1 negative and characteristically undergo adipogenesis under appropriate conditions.

Fibrocytes are CD34+ cells that derive from monocyte and B cell lineages within the bone marrow [32]. These cells circulate as peripheral blood mononuclear cells, infiltrating connective tissues at sites of injury or inflammation in response to chemokines [32]. Recent studies from the laboratory of Dr. Terry J. Smith have suggested that fibrocytes express high levels of thyrotropin receptor (TSHR), produce copious inflammatory cytokines, and may similarly infiltrate orbital tissues in GO [33,34]. If confirmed by other groups, these cells may represent a subset of orbital fibroblasts playing an important role in the orbital tissue remodeling characteristic of GO.

## The Role of TSH Receptor

A close temporal relationship exists between the onset of Graves' hyperthyroidism and the onset of clinically apparent GO; regardless of which occurs first, the other develops in 80% of patients within 18 months [35]. GO can be diagnosed in 25–50% of patients with Graves' hyperthyroidism. However, when sensitive imaging techniques are used, evidence of ocular involvement is detectable in the majority of patients [9]. These clinical observations suggest that Graves' hyperthyroidism and GO share etiologic factors. That said, it is notable that GO is seen on occasion in patients with no thyroid dysfunction. However, using adequately sensitive assays, autoantibodies directed against the thyrotropin receptor (TRAb) can be detected in essentially every patient with GO [36]. Further, levels of TRAb correlate with the severity and clinical activity of the disease [37,38] and high TRAb levels in early GO predict a poor prognosis [39]. As autoantibodies directed against TSHR on thyroid follicular cells stimulate the production of thyroid hormone in Graves' hyperthyroidism, it was postulated early on that immunoreactivity against TSHR in the orbit may play a role in GO pathogenesis.

Insight into the link between the thyroid and the orbit was gained by the demonstration that orbital fibroblasts express TSHR [40,41]. Studies from several laboratories are in general agreement that TSHR mRNA and protein are present in both GO and normal orbital tissues and fibroblast cultures, and that significantly higher levels of the receptor are detectable in GO cells [42–44]. Further, a positive correlation has been demonstrated between TSHR mRNA levels in individual GO orbital adipose tissue specimens and the activity of the patient's disease, suggesting a role for TSHR in the development of the clinical disease [45]. TSHR signaling pathways in orbital fibroblasts are similar to those found in thyrocytes [46], including activation of both adenylyl cyclase/cAMP and phosphatidylinositol 3-kinase (PI3K)/pAkt cascades [47]. In order to investigate whether TSHR activation plays a role in adipogenesis in GO orbital fibroblasts, Zhang and colleagues introduced an activating mutant TSHR into these cells and demonstrated an increase in adipocyte differentiation, as shown by 2 to 8-fold elevations in levels of early to intermediate adipocyte markers [48]. Our laboratory found increased expression of late adipocyte genes (adiponectin and leptin) and accumulation of lipid in GO orbital fibroblasts cultured in the presence of a stimulatory monoclonal TRAb (termed M22) or bovine TSH. This was inhibited by co-treatment with the PI3-kinase inhibitor LY294002, suggesting that PI3K/pAkt signaling in part mediates TRAb and TSH-induced adipogenesis in these cells [49].

As HA accumulation is another histologic feature of GO orbital tissues, several groups have studied the impact of TSHR activation on HA synthesis in orbital fibroblasts. Zhang and colleagues treated cells with bovine TSH or with 2 different monoclonal TRAb and showed increased HA production in normal orbital fibroblast cultures, but not in similarly treated GO fibroblasts [48]. However, when this same group transfected GO orbital fibroblasts with an activating mutant TSHR, they demonstrated the induction of hyaluronan synthases 1 and 2 and elevated HA production compared with control transfected cells. In our studies of GO orbital fibroblasts treated with either bovine TSH or a potent stimulatory TRAb (termed M22), we found elevated levels of cAMP, pAkt and HA [50]. We also determined that these effects could be abrogated by co-treatment with a small molecule TSHR antagonist, termed C-1 [51], further implicating activation of this receptor in the cellular changes characteristic of GO.

Perhaps the strongest evidence to date that TSHR is the primary autoantigen in GO lies in a recently developed animal model. The protocol, developed by Moshkelgosha and colleagues, involves genetic immunization of inbred mice with human TSHR ectoderm plasmid using close field electroporation [52]. The animals develop TSHR stimulating or blocking antibodies and either hyperthyroidism or hypothyroidism. In addition, following prolonged immunization, inflammatory cell infiltrates consisting of CD3+CD4+ T cells, macrophages and mast cells can be demonstrated in the extraocular muscles in the majority of animals. Outward signs of orbital involvement include inflammation of the eyelids and conjunctivae. Expansion of the orbital adipose tissues is evident in about 10% of animals and magnetic resonance imaging (MRI) reveals hypertrophy of extraocular muscles and proptosis in most. While useful animal models of Graves' hyperthyroidism have long been available [53], this is the first demonstrating convincing eye changes similar to those seen in human GO. It is likely that the chronic stimulation of TSHR accomplished in this model, as well as the unique electroporation protocol, allowed for induction of GO in these animals.

## The Potential Role of IGF-1 Receptor

The insulin-like growth factor-1 receptor (IGF-1R) has emerged as potentially involved in GO pathogenesis via interactions with TSHR [26,54]. Indeed IGF-1R is known to participate in cross-talk with several other receptors and signaling pathways [55]. This receptor, as well as the structurally related insulin receptor (IR), contains 2  $\alpha$ - and 2  $\beta$ -chains that form a heterotetrameric structure linked by covalent disulfide bridges [56,57]. Binding of either IGF-1 or insulin initiates dimerization, autophosphorylation, and activation of the receptor complex. Phosphorylation of tyrosine substrates follows and leads to binding and activation of the regulatory subunit of PI3K with subsequent stimulation of PI3K activity. The resulting elevated phosphatidylinositol 3,4,5-triphosphate levels function to phosphorylate and activate Akt at the cell membrane. The PI3K/Akt pathway has been shown to mediate many different cellular functions, including cell survival [58] and the promotion of adipogenesis [59].

Early studies demonstrated IGF-1 binding in orbital cells from patients with GO and not in normal orbital cells [60,61], and later studies showed expression of IGF-1R to be greater in GO orbital fibroblasts than in normal orbital cells [62]. Smith and colleagues treated GO orbital fibroblasts with IGF-1, human recombinant TSH (hrTSH), or immunoglobulins from patients with Graves' disease (GD-IgG) and studied both HA synthesis [63] and T cell chemoattractant expression [62]. While they found GD-IgG to be a potent inducer of both HA synthesis and chemokine expression, hrTSH had no effect in these cells. They additionally showed neutralization of GD-IgG by a potent IGF-1R blocker (termed 1H-7) or by transfection of fibroblasts with a dominant negative mutant IGF-1R [64]. They concluded that HA synthesis and chemokine expression in these cells might be augmented by autoantibodies specifically targeting IGF-1R and that ligation of this receptor might mediate some TSH-induced signaling. Our laboratory performed studies in which GO orbital fibroblasts treated with bovine TSH (potentially more potent than hrTSH), M22 or IGF-1, with or without co-treatment with 1H7. We found that cAMP production, phosphorylation of Akt and HA synthesis stimulated by each of these agents can be abrogated by co-treatment with 1-H7, suggesting that HA syn-

thesis induced by TSHR activation in these cells may involve IGF-1R signaling.

Moshkelgosha and colleagues used their animal model of GO (described above) to address the potential role of IGF-1R as an autoantigen in GO [52]. However, rather than immunizing animals with TSHR cDNA, they used IGF-1R $\alpha$  plasmid. They found that while these mice generated high levels of IGF-1R $\alpha$  antibody, they developed no apparent ocular or other pathology. However, some of the animals immunized with TSHR A subunit alone developed low-titer IGF-1R $\alpha$  antibodies shortly after immunization. How these secondary antibodies are produced and whether they might impact TSHR signaling in orbital fibroblasts is unknown.

Recent studies by Krieger and colleagues suggest that IGF-1R and TSHR increase the production of HA by GO orbital fibroblasts in a synergistic fashion [65]. These investigators showed progressively higher levels of HA production by TSH-treated cells co-treated with increasing IGF-1 doses. In addition, the dose-dependent stimulation of HA secretion by M22 was shown to be biphasic with the higher potency phase mediated in part via IGF-1R signaling. These data provide evidence for the existence of cross-talk between TSHR and IGF-1R in GO orbital fibroblasts induced by TSHR activation. That these receptors might form physical complexes has been suggested in studies demonstrating immunoprecipitation of both receptors from GO orbital fibroblast or thyrocyte preparations using specific monoclonal antibodies directed against either receptor and showing their co-localization in the perinuclear and cytoplasmic compartments of these cells [60].

Despite attempts by several laboratories, antibodies that specifically target IGF-1R have not been found to be more prevalent or elevated in GO than in normal sera, making it unlikely that such antibodies play a role in GO pathogenesis [66]. However, it is possible that TSHR signaling pathways within the GO orbit are influenced by locally produced IGF-1 acting in an autocrine or paracrine fashion and/or that downstream signaling pathways common to both TSHR and IGF-1R are engaged following TSHR activation [54].

### Therapeutic Implications

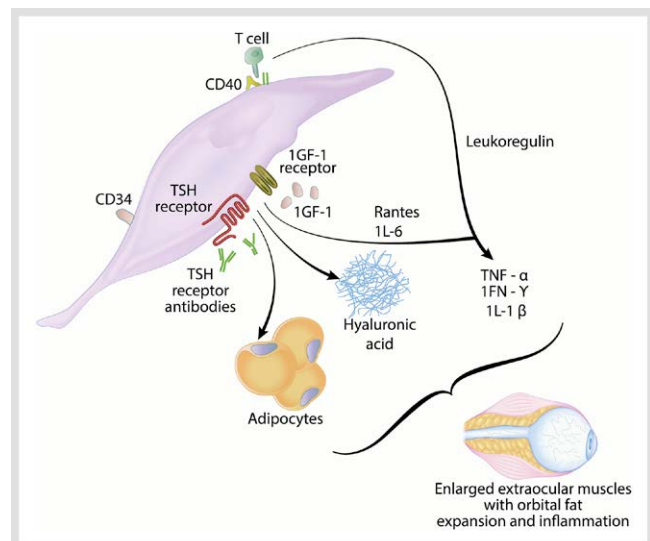
Evidence presented in this review concerning TSHR expression and function in GO orbital cells and cross-talk between this receptor and IGF-1R suggests potential therapeutic avenues involving receptor antagonists. Small molecular ligands that inhibit stimulated as well as constitutive TSHR signaling have been developed via molecular modeling and functional experiments [67]. These allosteric modulators sit within the transmembrane helices of TSHR and prevent contact with intracellular residues essential for agonist activity. As such, their action does not involve competition with extracellular TSH or blockade of TRAb binding sites. Neumann and colleagues found TRAb-stimulated thyroid function in female mice to be reduced following treatment with a small molecule TSHR antagonist [68]. Further, as discussed above, a particular TSHR antagonist, termed C-1, inhibits TSH- and TRAb-mediated HA secretion in GO orbital cells [47]. These early studies suggest that small molecule TSHR antagonists might be useful in the treatment of Graves' hyperthyroidism and ophthalmopathy, and could potentially be used to prevent the development of GO in patients with Graves' disease. Because these compounds can be produced in large quantities and are not degraded in the GI tract, oral administration may be possible. Another antireceptor approach, the blocking of

IGF-1R with teprotumumab, is currently under investigation in a multi-center trial (NCT01868997). Based on current concepts of GO pathogenesis, combined anti-TSHR and anti-IGF-1 therapy might in future prove particularly effective.

Multiple studies implicate both Th-1-type and macrophage-derived cytokines in early GO pathogenesis [1,26]. Therefore, monoclonal antibodies that target proinflammatory cytokines and chemokines might be of therapeutic benefit in the disease. Specifically, biological agents that block IL-1 receptor (anakinra), IL-6 (tocilizumab), TGF- $\beta$  (lerdelimumab, GC1008), or TNF- $\alpha$  (infliximab, adalimumab, or etanercept) are attractive as potential therapy. Case reports have suggested that rituximab, a monoclonal antibody directed against B cell surface CD20, might be useful therapy for patients with active GO. However, 2 recently completed randomized controlled trials showed disparate results, indicating that the agent is not uniformly effective [69,70]. Because GO duration was shorter in the study showing benefit (mean duration 4 months vs. 12 months), it is possible that a subgroup of patients with short disease duration might benefit from the therapy. Other approaches might include modulation of co-stimulatory pathways with agents directed against cytotoxic T-lymphocyte-associated protein (CTLA)-4 (abatacept) or reduction of inflammation and potentially orbital adipogenesis with novel selective peroxisome proliferator-activated receptor (PPAR)- $\gamma$  antagonists.

### Summary

Environmental, genetic and immune factors are at play in the development of the variable clinical manifestations of GO. Both cellular and humeral immunity directed against TSHR expressed on orbital fibroblasts likely initiate the disease process (► Fig. 1).



**Fig. 1** Current insights into the pathogenesis of GO. The cellular processes that lead to the development of GO are set in motion following activation of helper T cells recognizing TSHR peptides presented by CD34+ CD40+ orbital fibroblasts and ligation of TSHR on these cells by TRAb. This leads to the secretion of inflammatory cytokines and chemokines and enhanced HA production and adipogenesis in orbital fibroblasts. In addition, TSHR and IGF-1R may engage in cross-talk induced by TSHR ligation to synergistically enhance TSHR signaling, HA production, and the secretion of inflammatory mediators. The resulting connective tissue remodeling results in varying degrees of extraocular muscle enlargement and orbital fat expansion characteristic of GO. (Color figure available online only).

Activation of helper T cells recognizing TSHR peptides presented by CD40+ cells and ligation of TSHR by TRAb lead to the secretion of inflammatory cytokines and chemokines by activated T cells and orbital fibroblasts, and enhanced HA production and adipogenesis in the latter. The resulting connective tissue remodeling results in varying degrees extraocular muscle enlargement and orbital fat expansion. A subset of orbital fibroblasts express CD34, are bone-marrow derived, and circulate as fibrocytes that infiltrate connective tissues at sites of injury or inflammation. As these cells express high levels of TSHR and are capable of producing copious cytokines and chemokines, they may represent an orbital fibroblast population that plays a central role in GO development. In addition to TSHR, orbital fibroblasts from patients with GO express high levels of IGF-1R. Recent studies suggest that these receptors engage in cross-talk induced by TSHR ligation to synergistically enhance TSHR signaling, HA production, and the secretion of inflammatory mediators.

### Conflict of Interest



The authors declare no conflict of interest.

### References

- Bahn RS. Graves' ophthalmopathy. *N Engl J Med* 2010; 362: 726–738
- Wiersinga WM. Management of Graves ophthalmopathy. *Nat Clin Pract Endocrinol Metab* 2007; 3: 396–404
- Burch HB, Wartofsky L. Graves' ophthalmopathy: current concepts regarding pathogenesis and management. *Endocr Rev* 1993; 14: 747–793
- Tellez M, Cooper J, Edmonds C. Graves' ophthalmopathy in relation to cigarette smoking and ethnic origin. *Clin Endocrinol (Oxf)* 1992; 36: 291–294
- Tomer Y. Genetic susceptibility to autoimmune thyroid disease: past, present, and future. *Thyroid* 2010; 20: 715–725
- Yin X, Latif R, Bahn R, Tomer Y, Davies TF. Influence of the TSH receptor gene on susceptibility to Graves' disease and Graves' ophthalmopathy. *Thyroid* 2008; 18: 1201–1206
- Yin X, Latif R, Bahn R, Davies TF. Genetic profiling in Graves' disease: further evidence for lack of a distinct genetic contribution to Graves' ophthalmopathy. *Thyroid* 2012; 22: 730–736
- Hasham A, Tomer Y. Genetic and epigenetic mechanisms in thyroid autoimmunity. *Immunol Res* 2012; 54: 204–213
- Wiersinga WM, Bartalena L. Epidemiology and prevention of Graves' ophthalmopathy. *Thyroid* 2002; 12: 855–860
- Trask F, Tallstedt L, Abraham-Nordling M, Andersson T, Berg G, Calisanderoff J, Hallgren B, Hedner P, Lantz M, Nystrom E, Ponjavic V, Taube A, Topping O, Wallin G, Asman P, Lundell G. Thyroid-associated ophthalmopathy after treatment for Graves' hyperthyroidism with antithyroid drugs or iodine-131. *J Clin Endocrinol Metab* 2009; 94: 3700–3707
- Pfeilschifter J, Ziegler R. Smoking and endocrine ophthalmopathy: impact of smoking severity and current vs lifetime cigarette consumption. *Clin Endocrinol* 1996; 45: 477–481
- Krassas GE, Segni M, Wiersinga WM. Childhood Graves' ophthalmopathy: results of a European questionnaire study. *Eur J Endocrinol* 2005; 153: 515–521
- Cawood TJ, Moriarty P, O'Farrelly C, O'Shea D. Smoking and thyroid-associated ophthalmopathy: A novel explanation of the biological link. *J Clin Endocrinol Metab* 2007; 92: 59–64
- Metcalfe RA, Weetman AP. Stimulation of extraocular muscle fibroblasts by cytokines and hypoxia: possible role in thyroid-associated ophthalmopathy. *Clin Endocrinol (Oxf)* 1994; 40: 67–72
- Tallstedt L, Lundell G, Topping O, Wallin G, Ljunggren JG, Blomgren H, Taube A. Occurrence of ophthalmopathy after treatment for Graves' hyperthyroidism. *N Engl J Med* 1992; 326: 1733–1738
- Bartalena L, Marcocci C, Bogazzi F, Manetti L, Tanda ML, Dell'Unto E, Bruno-Bossio G, Nardi M, Bartolomei MP, Lepri A, Rossi G, Martino E, Pinchera A. Relation between therapy for hyperthyroidism and the course of Graves' ophthalmopathy. *N Engl J Med* 1998; 338: 73–78
- Laurberg P, Wallin G, Tallstedt L, Abraham-Nordling M, Lundell G, Topping O. TSH-receptor autoimmunity in Graves' disease after therapy with anti-thyroid drugs, surgery, or radioiodine: a 5-year prospective randomized study. *Eur J Endocrinol* 2008; 158: 69–75
- Vannucchi G, Campi I, Covelli D, Dazzi D, Curro N, Simonetta S, Ratiglia R, Beck-Peccoz P, Salvi M. Graves' orbitopathy activation after radioactive iodine therapy with and without steroid prophylaxis. *J Clin Endocrinol Metab* 2009; 94: 3381–3386
- Perras P, Kendall-Taylor P, Neoh C, Frewin S, Dickinson J. A prospective study of the effects of radioiodine therapy for hyperthyroidism in patients with minimally active Graves' ophthalmopathy. *J Clin Endocrinol Metab* 2005; 90: 5321–5323
- Bartalena L, Marcocci C, Bogazzi F, Panicucci M, Lepri A, Pinchera A. Use of corticosteroids to prevent progression of Graves' ophthalmopathy after radioiodine therapy for hyperthyroidism. *N Engl J Med* 1989; 321: 1349–1352
- Smith TJ, Wang HS, Evans CH. Leukoregulin is a potent inducer of hyaluronan synthesis in cultured human orbital fibroblasts. *Am J Physiol* 1995; 268: C382–C388
- Bahn RS, Burch HB, Cooper DS, Garber JR, Greenlee MC, Klein I, Laurberg P, McDougall IR, Montori VM, Rivkees SA, Ross DS, Sosa JA, Stan MN. Hyperthyroidism and other causes of thyrotoxicosis: management guidelines of the American Thyroid Association and American Association of Clinical Endocrinologists. *Thyroid* 2011; 21: 593–646
- Pappa A, Calder V, Ajjan R, Fells P, Ludgate M, Weetman AP, Lightman S. Analysis of extraocular muscle-infiltrating T cells in thyroid-associated ophthalmopathy (TAO). *Clin Exp Immunol* 1997; 109: 362–369
- Eckstein AK, Quadbeck B, Tews S, Mann K, Kruger C, Mohr CH, Steuhl KP, Esser J, Gieseler RK. Thyroid associated ophthalmopathy: evidence for CD4(+) gammadelta T cells; de novo differentiation of RFD7(+) macrophages, but not of RFD1(+) dendritic cells; and loss of gammadelta and alpha beta T cell receptor expression. *Br J Ophthalmol* 2004; 88: 803–808
- Aniszewski JP, Valyasevi RW, Bahn RS. Relationship between disease duration and predominant orbital T cell subset in Graves' ophthalmopathy. *J Clin Endocrinol Metab* 2000; 85: 776–780
- Wang Y, Smith TJ. Current concepts in the molecular pathogenesis of thyroid-associated ophthalmopathy. *Invest Ophthalmol Vis Sci* 2014; 55: 1735–1748
- Feldon SE, Park DJ, O'Loughlin CW, Nguyen VT, Landskroner-Eiger S, Chang D, Thatcher TH, Phipps RP. Autologous T-lymphocytes stimulate proliferation of orbital fibroblasts derived from patients with Graves' ophthalmopathy. *Invest Ophthalmol Vis Sci* 2005; 46: 3913–3921
- Grubeck-Loebenstein B, Trieb K, Sztankay A, Holter W, Anderl H, Wick G. Retrobulbar T cells from patients with Graves' ophthalmopathy are CD8+ and specifically recognize autologous fibroblasts. *J Clin Invest* 1994; 93: 2738–2743
- Otto E, Forster G, Kuhlemann K, Hansen C, Kahaly GJ. TSH receptor in endocrine autoimmunity. *Clin Exp Rheumatol* 1996; 14 (Suppl 15): S77–S84
- Prabhakar BS, Bahn RS, Smith TJ. Current perspective on the pathogenesis of Graves'disease and ophthalmopathy. *Endo Rev* 2003; 24: 802–835
- Smith TJ, Koumas L, Gagnon A, Bell A, Sempowski GD, Phipps RP, Sorisky A. Orbital fibroblast heterogeneity may determine the clinical presentation of thyroid-associated ophthalmopathy. *J Clin Endocrinol Metab* 2002; 87: 385–392
- Peng H, Herzog EL. Fibrocytes: emerging effector cells in chronic inflammation. *Curr Opin Pharmacol* 2012; 12: 491–496
- Smith TJ. TSH-receptor-expressing fibrocytes and thyroid-associated ophthalmopathy. *Nat Rev Endocrinol* 2015; 11: 171–181
- Douglas RS, Afifyan NF, Hwang CJ, Chong K, Haider U, Richards P, Gianoukakis AG, Smith TJ. Increased generation of fibrocytes in thyroid-associated ophthalmopathy. *J Clin Endocrinol Metab* 2010; 95: 430–438
- Wiersinga WM, Smit T, van der Gaag R, Koornneef L. Temporal relationship between onset of Graves' ophthalmopathy and onset of thyroidal Graves' disease. *J Endocrinol Invest* 1988; 11: 615–619
- Khoo DH, Eng PH, Ho SC, Tai ES, Morgenthaler NG, Seah LL, Fong KS, Chee SP, Choo CT, Aw SE. Graves' ophthalmopathy in the absence of elevated free thyroxine and triiodothyronine levels: prevalence, natural history, and thyrotropin receptor antibody levels. *Thyroid* 2000; 10: 1093–1100
- Gerding MN, van der Meer JW, Broenink M, Bakker O, Wiersinga WM, Prummel MF. Association of thyrotropin receptor antibodies with the clinical features of Graves' ophthalmopathy. *Clin Endocrinol* 2000; 52: 267–271

- 38 Lytton SD, Ponto KA, Kanitz M, Matheis N, Kohn LD, Kahaly GJ. A novel thyroid stimulating immunoglobulin bioassay is a functional indicator of activity and severity of Graves' orbitopathy. *J Clin Endocrinol Metab* 2010; 95: 2123–2131
- 39 Eckstein AK, Plicht M, Lax H, Neuhauser M, Mann K, Lederbogen S, Heckmann C, Esser J, Morgenthaler NG. Thyrotropin receptor autoantibodies are independent risk factors for Graves' ophthalmopathy and help to predict severity and outcome of the disease. *J Clin Endocrinol Metab* 2006; 91: 3464–3470
- 40 Heufelder AE, Bahn RS. Evidence for the presence of a functional TSH receptor in retroocular fibroblasts from patients with Graves' ophthalmopathy. *Exp Clin Endocrinol* 1992; 100: 62–67
- 41 Feliciello A, Porcellini A, Ciullo I, Bonavolonta G, Avvedimento EV, Fenzi G. Expression of thyrotropin-receptor mRNA in healthy and Graves' disease retro-orbital tissue. *Lancet* 1993; 342: 337–338
- 42 Bahn RS, Dutton CM, Natt N, Joba W, Spitzweg C, Heufelder AE. Thyrotropin receptor expression in Graves' orbital adipose/connective tissues: potential autoantigen in Graves' ophthalmopathy. *J Clin Endocrinol Metab* 1998; 83: 998–1002
- 43 Ludgate M, Crisp M, Lane C, Costagliola S, Vassart G, Weetman A, Daunerie C, Many MC. The thyrotropin receptor in thyroid eye disease. *Thyroid* 1998; 8: 411–413
- 44 Crisp MS, Lane C, Halliwell M, Wynford-Thomas D, Ludgate M. Thyrotropin receptor transcripts in human adipose tissue. *J Clin Endocrinol Metab* 1997; 82: 2003–2005
- 45 Wakelkamp IM, Bakker O, Baldeschi L, Wiersinga WM, Prummel MF. TSH-R expression and cytokine profile in orbital tissue of active vs. inactive Graves' ophthalmopathy patients. *Clin Endocrinol* 2003; 58: 280–287
- 46 Morshed SA, Latif R, Davies TF. Characterization of thyrotropin receptor antibody-induced signaling cascades. *Endocrinol* 2009; 150: 519–529
- 47 Turcu AF, Kumar S, Neumann S, Coenen M, Iyer S, Chiriboga P, Gershengorn MC, Bahn RS. A small molecule antagonist inhibits thyrotropin receptor antibody-induced orbital fibroblast functions involved in the pathogenesis of Graves ophthalmopathy. *J Clin Endocrinol Metab* 2013; 98: 2153–2159
- 48 Zhang L, Bowen T, Grennan-Jones F, Paddon C, Giles P, Webber J, Steadman R, Ludgate M. Thyrotropin receptor activation increases hyaluronan production in preadipocyte fibroblasts: contributory role in hyaluronan accumulation in thyroid dysfunction. *J Biol Chem* 2009; 284: 26447–26455
- 49 Kumar S, Nadeem S, Stan MS, Coenen MJ, Bahn RS. A stimulatory thyrotropin receptor antibody enhances adipogenesis via phosphoinositide 3-kinase activation in orbital preadipocytes from patients with Graves' ophthalmopathy. *J Mol Endocrinol* 2011; 46: 155–163
- 50 Kumar S, Iyer S, Bauer H, Coenen M, Bahn RS. A stimulatory thyrotropin receptor antibody enhances hyaluronic acid synthesis in Graves' orbital fibroblasts: Inhibition by an IGF-1 receptor blocking antibody. *J Clin Endocrinol Metab* 2012; 97: 1681–1687
- 51 Petersen JC, Kaiser S, Dean N, Simoncig A, Liu HY, Cavaliere AL, Cacho C, Turcu IC, Springate E, Frassetto F, Poletto L, Dhese SS, Berger H, Cavaliere A. Clocking the melting transition of charge and lattice order in 1T-TaS<sub>2</sub> with ultrafast extreme-ultraviolet angle-resolved photoemission spectroscopy. *Phys Rev Lett* 2011; 107: 177402
- 52 Moshkelgoshha S, So PW, Deasy N, Diaz-Cano S, Banga JP. Cutting edge: retrobulbar inflammation, adipogenesis, and acute orbital congestion in a preclinical female mouse model of Graves' orbitopathy induced by thyrotropin receptor plasmid-in vivo electroporation. *Endocrinol* 2013; 154: 3008–3015
- 53 Nagayama Y, Kita-Furuyama M, Ando T, Nakao K, Mizuguchi H, Hayakawa T, Eguchi K, Niwa M. A novel murine model of Graves' hyperthyroidism by intramuscular injection of adenovirus expressing the thyrotropin receptor. *J Immunol* 2002; 168: 2789–2794
- 54 Wiersinga WM. Autoimmunity in Graves' ophthalmopathy: the result of an unfortunate marriage between TSH receptors and IGF-1 receptors? *J Clin Endocrinol Metab* 2011; 96: 2386–2394
- 55 Pyne NJ, Pyne S. Receptor tyrosine kinase-G-protein-coupled receptor signalling platforms: out of the shadow? *Trend Pharmacol Sci* 2011; 32: 443–450
- 56 Smith TJ. Insulin-like growth factor-I regulation of immune function: a potential therapeutic target in autoimmune diseases? *Pharmacol Rev* 2010; 62: 199–236
- 57 LeRoith D, Werner H, Beitner-Johnson D, Roberts CT Jr. Molecular and cellular aspects of the insulin-like growth factor I receptor. *Endocr Rev* 1995; 16: 143–163
- 58 Riedemann J, Macaulay VM. IGF1R signaling and its inhibition. *Endocr Relat Cancer* 2006; 13 (Suppl 1): S33–S43
- 59 Aubin D, Gagnon A, Sorisky A. Phosphoinositide 3-kinase is required for human adipocyte differentiation in culture. *Int J Obes (Lond)* 2005; 29: 1006–1009
- 60 Tsui S, Naik V, Hoa N, Hwang CJ, Affifyan NF, Sinha Hikim A, Gianoukakis AG, Douglas RS, Smith TJ. Evidence for an association between thyroid-stimulating hormone and insulin-like growth factor 1 receptors: a tale of two antigens implicated in Graves' disease. *J Immunol* 2008; 181: 4397–4405
- 61 Weightman DR, Perros P, Sherif IH, Kendall-Taylor P. Autoantibodies to IGF-1 binding sites in thyroid associated ophthalmopathy. *Autoimmunity* 1993; 16: 251–257
- 62 Pritchard J, Han R, Horst N, Cruikshank WW, Smith TJ. Immunoglobulin activation of T cell chemoattractant expression in fibroblasts from patients with Graves' disease is mediated through the insulin-like growth factor I receptor pathway. *J Immunol* 2003; 170: 6348–6354
- 63 Smith TJ, Hoa N. Immunoglobulins from patients with Graves' disease induce hyaluronan synthesis in their orbital fibroblasts through the self-antigen, insulin-like growth factor-I receptor. *J Clin Endocrinol Metab* 2004; 89: 5076–5080
- 64 Pritchard J, Han R, Horst N, Cruikshank WW, Smith TJ. Immunoglobulin activation of T cell chemoattractant expression in fibroblasts from patients with Graves' disease is mediated through the insulin-like growth factor I receptor pathway. *J Immunol* 2003; 170: 6348–6354
- 65 Krieger CC, Neumann S, Place RF, Marcus-Samuels B, Gershengorn MC. Bidirectional TSH and IGF-1 receptor cross-talk mediates stimulation of hyaluronan secretion by Graves' disease immunoglobulins. *J Clin Endocrinol Metab* 2015; 100: 1071–1077
- 66 Minich WB, Dehina N, Welsink T, Schwiebert C, Morgenthaler NG, Kohrle J, Eckstein A, Schomburg L. Autoantibodies to the IGF1 receptor in Graves' orbitopathy. *J Clin Endocrinol Metab* 2013; 98: 752–760
- 67 Neumann S, Kleinau G, Costanzi S, Moore S, Jiang JK, Raaka BM, Thomas CJ, Krause G, Gershengorn MC. A low-molecular-weight antagonist for the human thyrotropin receptor with therapeutic potential for hyperthyroidism. *Endocrinol* 2008; 149: 5945–5950
- 68 Neumann S, Nir EA, Eliseeva E, Huang W, Marugan J, Xiao J, Dulcey AE, Gershengorn MC. A selective TSH receptor antagonist inhibits stimulation of thyroid function in female mice. *Endocrinol* 2014; 155: 310–314
- 69 Stan MN, Garrity JA, Carranza Leon BG, Prabin T, Bradley EA, Bahn RS. Randomized controlled trial of rituximab in patients with Graves' orbitopathy. *J Clin Endocrinol Metab* 2015; 100: 432–441
- 70 Salvi M, Vannucchi G, Curro N, Campi I, Covelli D, Dazzi D, Simonetta S, Guastella C, Pignataro L, Avignone S, Beck-Peccoz P. Efficacy of B-cell targeted therapy with rituximab in patients with active moderate-severe Graves' orbitopathy: a randomized controlled study. *J Clin Endocrinol Metab* 2015; 100: 422–431