

Assessment of Ultrasound as a Diagnostic Modality for Detecting Cervical Spine Fractures in Head-Injured Patients

Deepak Agrawal¹ Tej Prakash Sinha² Sanjeev Bhoi²

¹Department of Neurosurgery, Jai Prakash Narayan Apex Trauma Centre, All India Institute of Medical Sciences, New Delhi, India

²Department of Emergency Medicine, Jai Prakash Narayan Apex Trauma Centre, All India Institute of Medical Sciences, New Delhi, India

Address for correspondence Deepak Agrawal, MCh, Department of Neurosurgery, Jai Prakash Narayan Apex Trauma Centre, All India Institute of Medical Sciences, New Delhi-110029, India (e-mail: drdeepak@gmail.com).

Indian J Neurotrauma 2015;12:49–52.

Abstract

Background Early cervical spine clearance is extremely important in patients with head injuries and may be difficult to achieve in emergency setting. This is especially true in hemodynamically unstable unconscious patients and in low-resource settings. This study aimed to assess the feasibility of standard portable ultrasound in detecting cervical spine injuries in severe head-injured patients.

Materials and Methods This retro-prospective pilot study performed over 1-month period (June–July 2013) after approval from the institutional ethics committee. During the study period the technique of cervical ultrasound was standardized by the authors and tested on 10 admitted patients of cervical spine injury. To assess feasibility in the emergency setting, hemodynamically stable patients with *isolated* severe head injury (GCS ≤ 8) coming to emergency department underwent ultrasound examination on a portable ultrasound machine (MicroMaxx, Sonosite Inc., Bothell, Washington, United States).

Observations and Results Ultrasound examination of the cervical spine was possible in the emergency setting, even in unstable patients and could be done without moving the neck. The best window for the cervical spine was through the anterior triangle using the linear array probe (6–13 MHz). In the 10 patients with documented cervical spine injury, bilateral facet dislocation at C5–6 was seen in four patients and at C6–7 was seen in three patients. C5 burst fracture was present in one and C2 anterolisthesis was seen in one patient. Cervical ultrasound could easily detect fracture lines, canal compromise, and ligament injury in all cases.

Conclusion Cervical ultrasound may be a useful tool for detecting cervical spine injury in unconscious patients, especially those who are hemodynamically unstable. It may be particularly useful in the resource-constrained setting of developing countries

Keywords

- ▶ ultrasound
- ▶ cervical injury
- ▶ head injury
- ▶ cervical spine clearance

Introduction

Patients with acute trauma and especially with head injury have their cervical spine immobilized in cervical collar till

the cervical spine is cleared by radiographs or computed tomography (CT) of the spine. Unfortunately, there is delay in getting radiology done and various procedures such as examination of back, intubation, and patient shifting

received

August 5, 2014

accepted after revision

April 14, 2015

published online

June 17, 2015

© 2015 Neurotrauma Society of India

DOI <http://dx.doi.org/>

10.1055/s-0035-1554944.

ISSN 0973-0508.

become very difficult if the cervical spine injury is suspected, especially in hemodynamically unstable patients. Importantly also, radiographs do not pick up lower cervical and upper thoracic fractures.

As per ATLS (Advanced Trauma Life Support) protocol, in patients who are hemodynamically unstable/not maintaining saturation, ABCs have to be managed prior going to "D" (head injury assessment). In this scenario, it may be difficult, if not impossible, to rule out cervical spine injury prior to endotracheal intubation. This is especially true in unconscious patients of head injury. If it can be shown that ultrasound can reliably pick up cervical spine fractures, it will cause a paradigm shift in the management of these patients with the potential to revolutionize emergency health care for severe head-injured patients in most parts of the world where CT may not be available/accessible.

Our study attempts to assess the feasibility of using portable ultrasound in the cervical spine of unconscious patients with severe head injury especially in low-resource and emergency settings.

Materials and Methods

This retro-prospective pilot study performed over 1-month period (June–July 2013) after approval from the institutional ethics committee. During the study period the technique of cervical ultrasound was standardized by the authors and tested on 10 admitted patients of cervical spine injury. To assess feasibility in the emergency setting, hemodynamically stable patients with *isolated* severe head injury (Glasgow Coma Scale [GCS] ≤ 8) coming to emergency department underwent ultrasound examination. All these patients continued to receive standard management and underwent a head CT with CT cervical spine up to T1. All cervical ultrasound examinations were done by a neurosurgeon (without any formal training on ultrasound) or emergency physicians on a portable ultrasound machine (MicroMaxx, Sonosite Inc., Bothell, Washington, United States).

Ultrasound Technique

Posterior window: The authors initially performed a sonographic evaluation of the affected region using a high-frequency (6–13 MHz) linear array probe placed on the back of the neck of volunteers (\rightarrow Fig. 1). The image quality was excellent with the additional advantage of cervical canal being nicely visible. However, this method is impractical in patients with suspected cervical spine injury as the posterior window is not available to the examiner, except during log rolling.

Anterior window: Keeping the same linear probe in the anterior triangle of the neck provides satisfactory image quality and allows one to assess the cervical spine from C2 to D1 and see for canal compromise, ligament injury, and major fractures (\rightarrow Figs. 2 and 3).

This window was subsequently used for assessing the cervical spines in admitted patients with known cervical spine injuries.

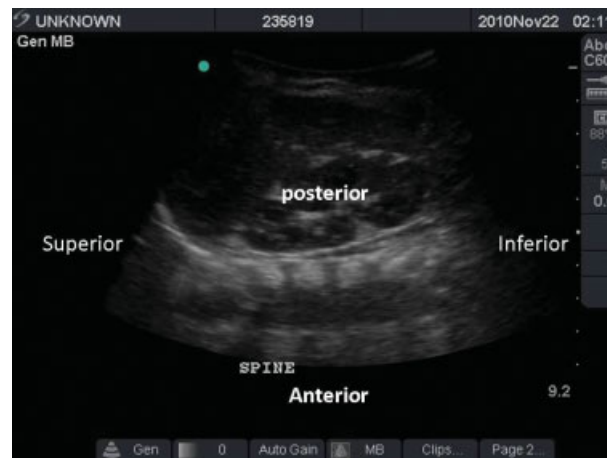

Fig. 1 Ultrasound of the cervical spine using the posterior window. The spine is seen best with this window. However, the practical utility is limited in acutely injured patients.

Observations

After standardizing the ultrasound technique, 10 *admitted* patients with *documented* cervical spine injury (on CT cervical spine) were evaluated with the same portable cervical ultrasound. Bilateral facet dislocation at C5–6 was seen in four patients and at C6–7 was seen in three patients. C5 burst fracture was present in one patient and C2 anterolisthesis was seen in one patient. Cervical ultrasound could easily detect fracture lines, canal compromise, and ligament injury in all cases (\rightarrow Fig. 4). Three patients with severe head injury underwent ultrasound in the emergency setting and the ultrasound examination could be done easily without obstructing the ongoing management of the patient(s) (\rightarrow Fig. 2). Cervical spine could be visualized well in all three patients and was normal in all. This was confirmed on subsequent CT of the cervical spine in all cases.

Discussion

Patient with acute trauma and especially with head injury have their cervical spine immobilized in cervical collar till

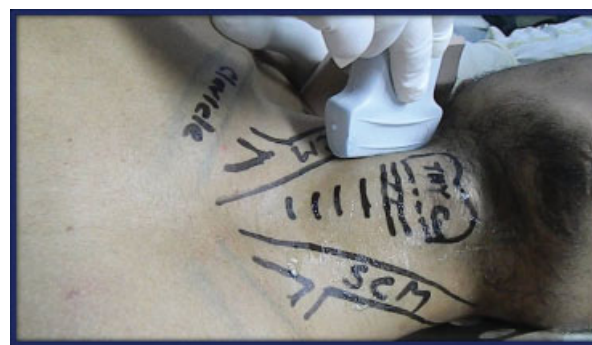


Fig. 2 The anatomical landmarks for the anterior window to the cervical spine in the neck. The probe should be kept in the anterior triangle of the neck for optimum resolution.

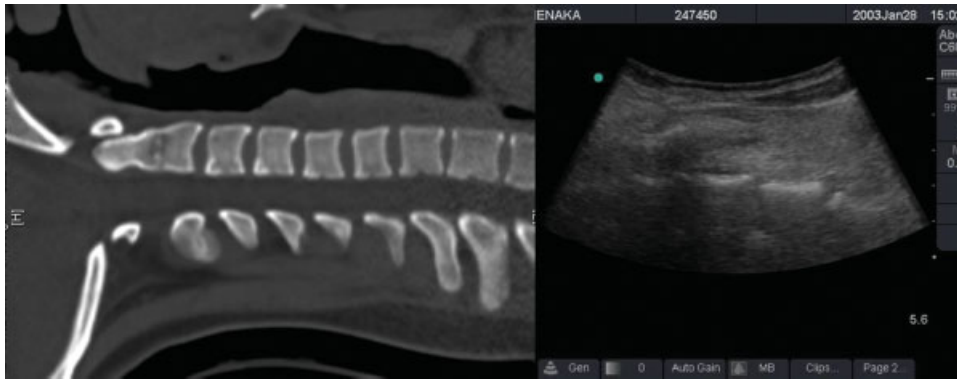


Fig. 3 CT cervical spine (sagittal section) and ultrasound image of the cervical spine of the same patient shown together for orientation. This figure shows that the cervical spine is very well seen on ultrasound imaging.

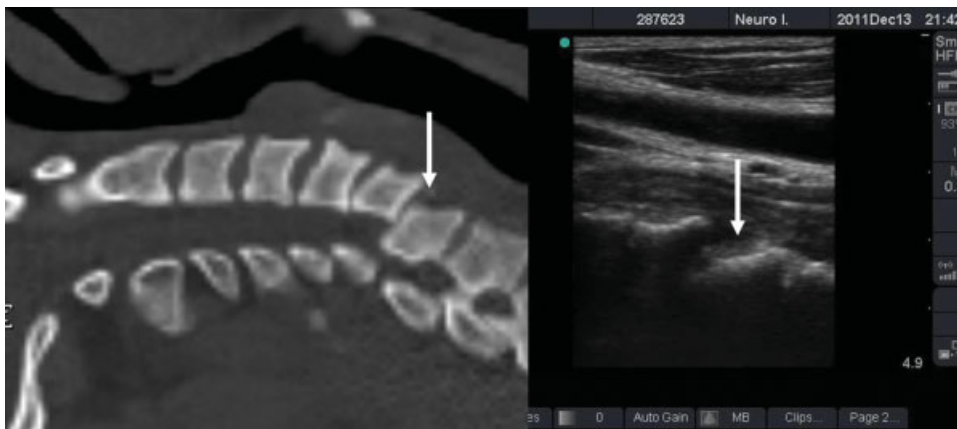


Fig. 4 CT cervical spine (sagittal section) and ultrasound image of the cervical spine of a patient with bilateral facet dislocation at C5–6. The dislocation and disruption of the anterior longitudinal ligament in the cervical spine is very well seen on ultrasound imaging (arrow).

the cervical spine is cleared by radiographs or CT spine. Unfortunately, there is delay in getting radiology done and various procedures such as intubation, examination of back, and patient shifting become very difficult without cervical spine clearance. Importantly also, radiographs do not pick up lower cervical and upper thoracic fractures.

Ultrasound machines are portable, commonly used by emergency physicians, and are therefore perfectly suited for mass casualty, low resource settings, and military applications. However, till date, there have been no studies on the utility of ultrasound in cervical spine clearance in acutely injured patients. If it can be shown that ultrasound can reliably pick up cervical spine fractures, it will cause a paradigm shift in the management of these patients. Our study attempts to assess the role and utility of portable ultrasound in assessing the cervical spine of acutely injured patients and correlate with CT of the cervical spine of these patients.

Although intuitively it appears that ultrasound may not be suited to evaluate the spine, a previous study on horses has described the normal ultrasonographic appearance of the cervical anatomy.¹ In this study, transverse scans were

obtained from second cervical vertebra (C2) to first thoracic vertebra (T1). Postmortem photographs of frozen cross-sections were obtained as anatomical reference. The authors found that the structures were clearly visualized by ultrasonography and consistency was found between ultrasonographic images and corresponding cross-sectional anatomy. Other studies have attempted to use ultrasound for pedicle screw insertion,² and facet injections^{3,4} with excellent results.

Our pilot study shows that ultrasound can be used to cervical spine and detect abnormalities such as fracture dislocations. Another important finding of our study was that cervical ultrasound is feasible in the emergency setting and has very high concordance with CT findings. A very pertinent fact was that all ultrasound examinations were done by a neurosurgeon or emergency physician(s) and minimal training was required for this level of concordance.

Limitations

Ultrasound being operator dependent, the results can vary depending on the person doing the scan. However, this

holds true for FAST (focused abdominal sonography in trauma) that has now become the de facto standard for abdominal trauma.

Also, as the consequences for missing a cervical injury can be disastrous, we recommend that ultrasound be used only as an adjunct to cervical radiographs/CT cervical spine. However, in low-resource settings or in life-threatening situations ultrasound of the cervical spine has the potential to radically improve patient care and allow for early interventions such as intubation and transfer of acutely injured patients. As this is a pilot study, the modality in its current form cannot be valid in the court of law.

Future Directions

Studies on a larger scale are required to validate our findings so as to allow cervical ultrasound for routine clinical use.

Conclusion

Cervical ultrasound is feasible using portable ultrasound machine and by neurosurgeons/emergency physicians with basics training. It holds great potential in resource-starved settings and in unstable patients for cervical spine clearance.

Conflict of Interest

There are no conflicts of interests.

Funding

No funding was required for this study.

References

- 1 Berg LC, Nielsen JV, Thoenner MB, Thomsen PD. Ultrasonography of the equine cervical region: a descriptive study in eight horses. *Equine Vet J* 2003;35(7):647-655
- 2 Kantelhardt SR, Bock HC, Siam L, et al. Intra-osseous ultrasound for pedicle screw positioning in the subaxial cervical spine: an experimental study. *Acta Neurochir (Wien)* 2010;152(4): 655-661
- 3 Galiano K, Obwegeser AA, Bodner G, et al. Ultrasound-guided facet joint injections in the middle to lower cervical spine: a CT-controlled sonoanatomic study. *Clin J Pain* 2006;22(6): 538-543
- 4 Narouze SN. Ultrasound-guided cervical periradicular injection: cautious optimism. *Reg Anesth Pain Med* 2006;31(1):87, author reply 87-88