

Transient Elastography to Assess the Cervical Ripening during Pregnancy: A Preliminary Study

Transiente Elastografie zur Bestimmung der Zervixreife in der Schwangerschaft: eine Vorstudie

Authors

Laura Peralta¹, Francisca Sonia Molina³, Juan Melchor¹, Luisa Fernanda Gómez³, Paloma Massó², Jesús Florido², Guillermo Rus¹

Affiliations

- 1 Department of Structural Mechanics, University of Granada, Spain
- 2 Department of Obstetrics and Gynecology, University of Granada, Spain
- 3 Obstetrics and Gynecology, Maternal-Fetal Medicine Unit, San Cecilio University Hospital, HUSC, Granada, Spain

Key words

shear wave elastography, cervix, pregnancy, cervical stiffness

received 03.12.2014

accepted 28.04.2015

Bibliography

DOI <https://doi.org/10.1055/s-0035-1553325>

Published online: August 07, 2015 | *Ultraschall in Med* 2017; 38: 395–402 © Georg Thieme Verlag KG, Stuttgart · New York, ISSN 0172-4614

Correspondence

Laura Peralta

Department of Structural Mechanics, University of Granada, Politecnico de Fuentenueva, 18071 Granada, Spain

Tel.: ++34/958/24 00 37

lperalta@ugr.es

ABSTRACT

Purpose To explore the feasibility of transient elastography (TE) to quantify cervical stiffness changes during normal pregnancy and its spatial variability.

Materials and Methods TE was used to quantify the cervical stiffness in four anatomical regions. 42 women between 17 and 43 years of age and at 6–41 weeks of gestation were studied. The stiffness was related to gestational age at the time of examination, interval from ultrasound examination to delivery and cervical length to evaluate the potential of TE to assess cervical ripening. In addition, a sensitivity analysis based on Cronbach's alpha coefficient was carried out to assess the concordance between inter/intra-operator measurements.

Results There were significant correlations between cervical stiffness measured in the four regions with gestational age and the remaining time for delivery. Results confirm stiffness

variability within the cervix. No significant association was found between cervical length and stiffness in the four ROIs. Associations between gestational age and remaining time for delivery with cervical length present weaker correlations than with cervical stiffness. The external part of the cervix was significantly softer than the internal one, and these stiffness values vary significantly in the anterior compared to the posterior cervix. The measurements taken by the same and by two different observers for different regions in the cervix were reliable and reproducible.

Conclusion It is feasible to objectively quantify the decrease of cervical stiffness correlated to gestational age. Transient elastography is a valuable promising tool to provide additional information on the process of cervical effacement to that obtained from digital examination and conventional ultrasound. Further studies are needed to assess the feasibility of the technique in obstetric clinical applications, such as prediction of preterm birth or success in labor induction.

ZUSAMMENFASSUNG

Ziel Machbarkeitsprüfung der transienten Elastografie (TE), um räumliche Veränderungen der Zervixsteifigkeit (CS) zum Laufe einer Normalschwangerschaft zu erfassen

Material und Methoden Die CS wurde mittels TE in 4 Regionen bei 40 Frauen im Alter von 17 bis 43 Jahren in der 6.–41. Schwangerschaftswoche bestimmt. Die CS wurde mit dem Gestationsalter zum Untersuchungszeitpunkt, dem Intervall zwischen US-Untersuchung und Entbindung und die Zervixlänge korreliert, um das Potenzial der TE hinsichtlich der Zervixreife zu beurteilen. Danach wurde eine Sensitivitätsanalyse (α -Koeffizienten nach Cronbach) durchgeführt, um die Übereinstimmung der Inter-/Intra-Operator-Messungen zu bestimmen.

Ergebnisse Die CS korrelierte in 4 Regionen mit dem Gestationsalter und der Zeit bis zur Entbindung signifikant. Die Ergebnisse bestätigen die Variabilität der Steifigkeit innerhalb der Zervix. Kein signifikanter Zusammenhang zwischen Zervixlänge und CS in den 4 ROIs. Gestationsalter und Zeit bis zur Entbindung zeigten eine schwächere Korrelation der Zervixlänge als mit der CS. Der äußere Bereich der Zervix war signifikant weicher als der innere Bereich, und diese CS-Werte variierten signifikant in der vorderen Zervix im Vergleich

zur hinteren Zervix. Die Intra und Inter-Observervarianz der Messwerte in den 4 Regionen waren zuverlässig und reproduzierbar.

Schlussfolgerung Man kann die sinkende Zervixsteifigkeit im Laufe des Gesationsalters bestimmen. Die TE ist wertvoll und vielversprechend. Sie liefert Zusatzinformationen zur

Muttermundöffnung, die über die manuelle Untersuchung und den herkömmlichen US hinaus gehen. Weitere Untersuchungen sind nötig um den Einsatz der TE bei geburtshilflichen Anwendungen, wie Vorhersage von Frühgeburten und erfolgreicher Geburtseinleitung, zu bewerten.

Introduction

In the last years, elastography has been proposed by many authors to evaluate cervical stiffness/softness [1–5]. Quasi-static elastography techniques have been applied to assess the stiffness of cervical tissue during pregnancy. Nevertheless, all of them showed inconsistent results in terms of reproducibility and correlation between softness and gestational age [6–9]. The resulting color map represents a qualitative description of the relative strain distribution, which is not a quantitative description of the real stiffness of the tissue. In addition, measurements are dependent on transducer pressure applied by the operator. Hence, absolute values of cervical stiffness are necessary for an objective assessment of the cervical ripening [10].

Dynamic elastography techniques, which rely on shear wave propagation, have the potential to provide quantitative and higher resolution maps of cervical stiffness compared to quasi-static methods [11]. A shear wave is generated and propagated through the tissue, and measuring its speed allows characterization of stiffness. As the ultrasound beam generates the displacements, this technique is less user-dependent than quasi-static techniques. Its better resolution has been shown on phantom tests [11, 12]. Shear waves have already been applied to assess differences in ripened vs. unripened cervical tissue, first in an *ex-vivo* study [13], and most recently *in-vivo* [14] pre- and post-labor induction. They concluded that shear wave velocities are significantly different in ripened vs. unripened cervical tissue. However, one more step is needed to calculate the cervical stiffness, usually defined as Young's modulus (relation between stress and strain) [15]. In a recent study, Peralta et al. [16] applied dynamic elastography to assess cervical stiffness evolution during induced labor in ewes, concluding that stiffness of the uterine cervix decreases throughout the artificially induced maturation process.

This study is aimed at evaluating the feasibility of providing quantitative information on the evolution of the cervical stiffness of shear wave elastography through the course of pregnancy. A preliminary study was performed on 42 healthy pregnant women using the TE technique to test the following hypothesis: (1) shear wave elastography can objectively quantify cervical stiffness defined by Young's modulus; (2) stiffness progressively decreases during pregnancy and (3) not in the same way throughout the cervix, which may present softer areas during gestation and thus be more sensitive in assessing the cervical mechanical state.

Materials and Methods

Subjects

The study was designed according to the Declaration of Helsinki. The local ethical committee in human investigation (Comité de ética en investigación humana de la Universidad de Granada and Comisión de ética e investigación sanitaria del hospital universitario San Cecilio de Granada) approved it. The experimental study was carried out at San Cecilio University Hospital in Granada, and included 42 women with uncomplicated singleton pregnancies at a median value of 27.5 (from 6 to 41) weeks of gestation. The population size was estimated a priori by a statistical power analysis. A regression analysis with desired power of 80 %, significance criterion as two-sided $\alpha = 0.05$, and supposing the recommended medium effect size $ES = 0.30$ [17], leads to a sample size of $N = 29$. Non-inclusion criteria were communication problems, multiple gestation, prior surgery on the cervix (e. g. conisation or cerclage), and untreated premalignant or malignant changes on the cervix. All the subjects included in the study had agreed by signing the informed written consent and the patient information. Gestational age at delivery and neonatal outcome data were acquired by verbal telephone report from the patient that delivered at a different hospital ($n = 3$).

Shear wave elastography

Elastography was performed using a commercial supersonic shear imaging device (SSI). This technique [18, 19] consists of generating shear waves inside the tissue by acoustic radiation force using a focused ultrasound beam. The ultrasound radiation force generates a broadband low frequency shear wave (300–800 Hz), which propagates perpendicularly to the ultrasonic beam axis. Right after shear wave generation, the system is then switched into an ultrafast ultrasound plane wave imaging mode (up to 20 000 frames/s) to capture the wave propagation and measure the shear wave velocity c_s . From this shear wave velocity, it is possible to compute a shear elasticity map under the assumption of a purely elastic and incompressible medium, for which the shear modulus μ can be written as,

$$\mu = \rho c_s^2$$

where ρ is the density of the medium. In order to describe soft tissue elasticity, the usual parameter is the Young's modulus, $E = \mu(3\lambda + 2\mu)/(\lambda + \mu)$. In large homogeneous media λ is 10^6 times bigger than μ , thus a good and an usual approximation of E is: $E = 3\mu$. Finally, the Young's modulus is then deduced from the shear wave velocity as,

$$E = 3\rho c_s^2$$

In this study, cervical stiffness was quantified by two operators using a 7-MHz conventional endocavitary ultrasonic probe (SE 12–3, Supersonic Imagine, Aix-en-Provence, France). Both operators performed the examination in a standardized pattern. The women were asked to empty their bladder and were placed in the dorsal lithotomy position. The vaginal probe was placed in the anterior fornix of the vagina and a sagittal view of the cervix, with the echogenic endocervical mucosa along the length of the canal, was obtained. Elastographic images of the cervix were generated after taking care to avoid any movements in the ultrasound probe. A paired image with a conventional B-mode image from the cervix side by side with an elastographic color map was acquired in all patients (► Fig. 1). Furthermore, cervical length was quantitatively assessed based on the conventional B-mode images and following the Fetal Medicine Foundation criteria (www.fetalmedicine.com).

Stiffness quantification

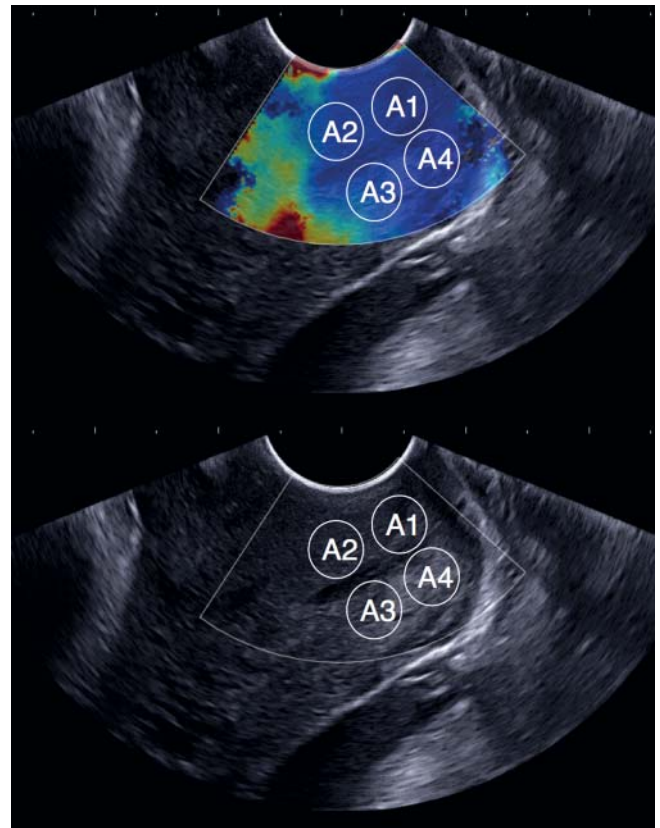
Cervical tissue is anisotropic, heterogeneous and its mechanical behavior is conditioned by its multiscale architecture. The microstructure of the cervical stroma is composed of a dense, hydrated and highly cross-linked collagen network embedded in a viscous proteoglycan ground substance [20]. These biochemical components exist on varying length scales from the nanometer to the millimeter and act together in a cooperative nature to give the cervix its tensile and compressive strength. During cervical ripening several changes progressively occur in that structure [21]. Unfortunately, these cervical changes are difficult to investigate and quantify, indeed their distribution over the cervical structure is still not well understood. Based on previous studies that suggest stiffness distribution in the cervix is heterogeneous [7, 13], we propose to quantify the elasticity in four different areas of the cervix.

Four regions of interest (ROI) in the cervix were selected to assess the stiffness: external and superior lip (region A1), internal and superior lip (region A2), internal and inferior lip (Region A3) and external and inferior lip (region A4), as shown in ► Fig. 1. A circle, 6 mm in diameter, was then placed in each of the four regions and the machine automatically displayed a stiffness value for each circle (mean value and standard deviation), quantifying the elasticity (Young's modulus) in pressure units (kPa).

Cervical elastographic measurements were carried out twice by a single operator in all the women, and these data were used for intraobserver analysis. A second operator also performed a single measurement of cervical elastography and this was compared to the first measurement made by the previous operator to determine the interobserver reproducibility. All measurements were performed offline on stored images, with the operator blinded to previous measurements, and the placement of the ROI within the elastographic image for the stiffness measurement was determined by following only anatomical criteria on the conventional B-mode image.

Statistics

Changes of stiffness values throughout gestation were evaluated. Regression analysis was used to determine the relationship



► Fig. 1 Elastographic and B-mode images of the cervix. The circles indicate the ROI selected to assess the stiffness. Region A1: external and superior cervical lip. Region A2: internal and superior cervical lip. Region A3: internal and inferior cervical lip. Region A4: external and inferior cervical lip.

between gestational age, interval time from elastography examination to delivery and cervical length with cervical stiffness in the four selected regions.

The ANOVA test with Bonferroni correction was performed to compare differences between the mean of the stiffness values in the four different regions selected.

Inter- and intraoperator agreement for stiffness values was assessed using the Cronbach's Alpha statistic. A priori interpretation of the alpha statistic was based on the following distribution: excellent, 0.91–1.0; good, 0.81–0.90; acceptable, 0.71–0.8; questionable, 0.61–0.70; poor, 0.51–0.60; and unacceptable < 0.50 [22].

Data were analyzed using the statistical software SPSS 22.0 (SPSS Inc., Chicago, IL, USA). All results are expressed as median [quartile 1–quartile 3]. Data were considered statistically significant for $p < 0.05$. P-values below 0.0005 are indicated as $p < 0.000$.

Results

Maternal and pregnancy characteristics of the population are summarized in ► Table 1. The preterm rate in our population was 2.38% ($n = 1$). The median at delivery was 40.1 (30.3–41.9) weeks. Cervical length measurement was successfully obtained

► **Table 1** Characteristics of the study population. Data are given as median (range) or n (%).

characteristics	value
total population (number)	42
maternal age (years)	32.5 (17.0 – 43.0)
body mass index (Kg/m ²)	25.2 (19.1 – 31.5)
gestational age at elastography (weeks)	27.5 (6.0 – 41.0)
gestational age at delivery (weeks)	40.1 (30.3 – 41.9)
nulliparous (number)	28 (66.7%)
cervical length (mm)	30.5 (6.0 – 50.0)

from all examined patients. One measurement of cervical stiffness in region A2 (internal and superior lip) and two in region A3 (internal and inferior lip) were impossible to assess.

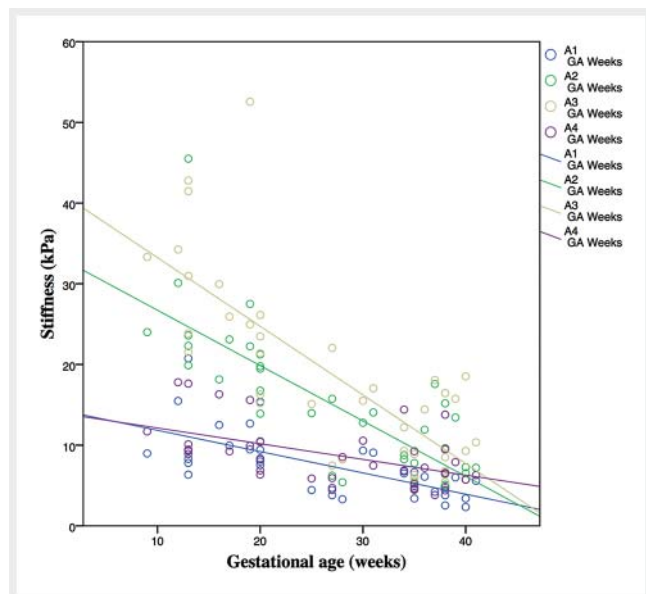
Regression analysis revealed that cervical stiffness, in the four regions of interest, was: (1) a significant predictor of gestational age at the time of examination; (2) a significant predictor of the interval from elastography examination to delivery; and (3) not a predictor of cervical length. In the total population, there were significant associations between cervical stiffness in the four cervical regions and gestational age and interval time from elastography examination to delivery (► **Table 2**, ► **Fig. 2**). Scatterplots of the relationship between cervical stiffness assessed in region A3 (internal and inferior cervical lip) and the interval time from ultrasound examination to delivery, gestational age at the time of examination and cervical length for all women included in the study showing linear regression lines and 95% confidence intervals are depicted in ► **Fig. 3 – 5**, respectively. Similar results were obtained for the other regions of interest A1, A2 and A4 (graphic data not shown, see correlation coefficients in ► **Table 2**). No high associations ($r < 0.5$ for all cases) and no significance ($p > 0.05$ in external part, regions A1 and A4) were found between cervical length and stiffness. Associations between gestational age and remaining time to delivery with cervical length ($r = -0.434$, $p = 0.004$ and $r = 0.455$, $p = 0.002$, respectively) present appreciable weaker correlations than with cervical stiffness.

Stiffness values were significantly different in the four studied regions of the cervix. The distribution of the measured cervical stiffness values demonstrated spatial variability both along the length of the cervix (external to internal part) and within its anterior vs. posterior part. The external part of the cervix was significantly softer than the internal one, and these stiffness values vary significantly in the anterior compared to the posterior cervix (► **Table 3**, ► **Fig. 2**).

The Cronbach's alpha coefficients were higher than 0.86 and above 0.9 in most cases (► **Table 4**). Therefore, both measurements, intraoperator and interoperator, were considered at least good (0.81 – 0.90) and in some areas excellent (> 0.90).

► **Table 2** Pearson correlation coefficient between cervical stiffness, cervical length, gestational age and interval time from elastography examination to delivery.

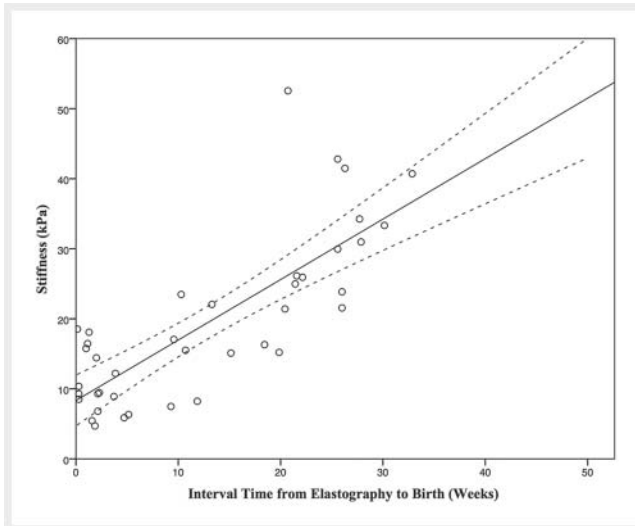
	cervical length	gestational age	time to delivery
stiffness A1	$r = 0.259$, $p = 0.098$	$r = -0.672$, $p = 0.000$	$r = 0.670$, $p = 0.000$
stiffness A2	$r = 0.413$, $p = 0.007$	$r = -0.796$, $p = 0.000$	$r = 0.803$, $p = 0.000$
stiffness A3	$r = 0.331$, $p = 0.037$	$r = -0.786$, $p = 0.000$	$r = 0.790$, $p = 0.000$
stiffness A4	$r = 0.057$, $p = 0.720$	$r = -0.567$, $p = 0.000$	$r = 0.573$, $p = 0.000$



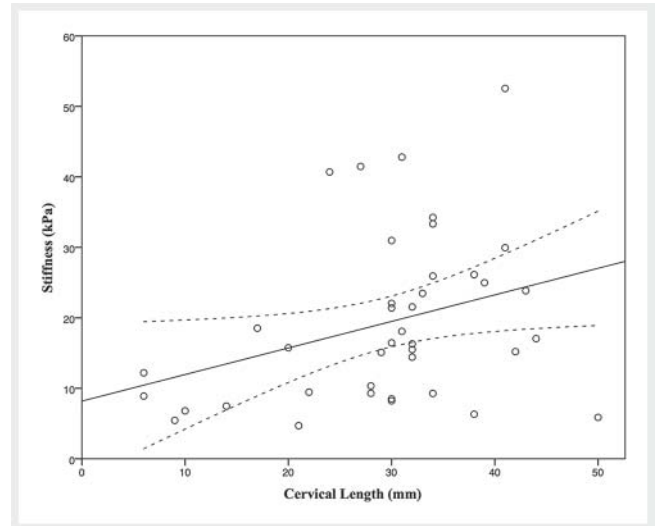
► **Fig. 2** Correlations between gestational age (weeks) and cervical stiffness in the four regions A1 (external and superior cervical lip), A2 (internal and superior cervical lip), A3 (internal and inferior cervical lip), A4 (external and inferior cervical lip).

Discussion

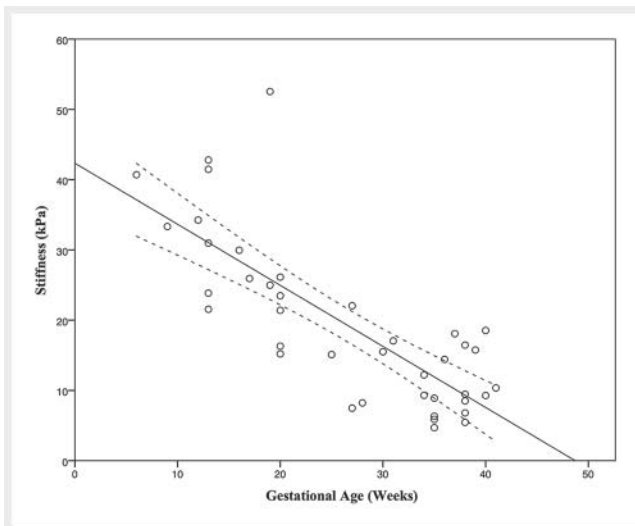
The main goal of this study is to assess the potential of TE to objectively quantify cervical stiffness during pregnancy, defined by Young's modulus. The TE technique has already been successfully used to characterize the structure and health of different biological tissues [16, 23 – 25]. In a recent study, Gennisson et al. [26] assessed the elasticity changes in the myometrium during labor using the same technique. The sensitivity of the technique in cervical tissue was already reported in a previous study performed in animals [16]. In the present study, results show the viability of shear wave elastography to objectively quantify cervical elasticity during normal pregnancy, providing absolute stiffness values in human cervical tissue for the first time to our knowledge. Therefore, data confirm hypothesis 1 and TE can objectively quantify



► **Fig. 3** Relationships between cervical stiffness assessed at region A3 (internal and inferior cervical lip) and interval time from ultrasound examination to delivery (weeks). Linear regression (solid line) and 95% CIs (dashed lines) lines are plotted.



► **Fig. 5** Relationships between cervical stiffness assessed at region A3 (internal and inferior cervical lip) and cervical length (mm). Linear regression (solid line) and 95% CIs (dashed lines) lines are plotted.



► **Fig. 4** Relationships between cervical stiffness assessed at region A3 (internal and inferior cervical lip) and gestational age at the time of examination (weeks). Linear regression (solid line) and 95% CIs (dashed lines) lines are plotted.

cervical stiffness defined by Young's modulus. Inter- and intra-operator repeatability has been demonstrated.

Our findings support hypothesis 2, i. e., stiffness decreases during pregnancy (► **Fig. 2**). We found that cervical stiffness significantly decreased with gestational age ($p=0.000$), and this relationship is higher in the internal part (regions A2 and A3, $r=-0.796$ and -0.786 , respectively) than in the external part (regions A1 and A4, $r=-0.672$ and -0.567 , respectively). These results agree with previous studies that evaluated cervical softening during pregnancy employing different techniques [2, 27, 28]. All of them found cervical softening during pregnancy. Or in other

words, cervical softening is directly related to the remaining time to delivery, depicted as significant correlations between cervical stiffness and interval time from elastography examination to delivery (► **Fig. 3**).

Our results show a weaker correlation of cervical stiffness with cervical length than with gestational age. Moreover, correlation between stiffness and cervical length was only significant in the internal part of the cervix (regions A2 and A3). In a recent study, Wozniak et al. [5] found similar correlations between internal os stiffness, assessed by quasi-static elastography, and cervical length. However, the high correlation between stiffness and gestational age is contrary to a previous result reported by Hernandez-Andrade et al. [9], which suggested that cervical tissue strain (an indirect measurement of stiffness) was more strongly associated with cervical length than with gestational age. This contradiction could be a consequence of the inherent limitations of the elastography technique that they used. The limitations of quasi-static elastography in cervical tissue have already been addressed by several authors [7, 8, 10]. It is not possible to quantify stiffness in absolute values with this technique since the elastographic image is only a qualitative description of the tissue strain. Displacements are generated by a hand-induced displacement of the tissue using the probe, which in addition may not reach deep areas of the cervix [9]. In the work of Hernandez-Andrade et al. [9], the strain was assessed in two ROIs: the endocervical canal and the entire cervix. The large dimension of those ROIs compared to the one used in this study might affect the strain rate value.

It has been reported that the areas located directly under the probe have a high strain rate [7–9]. Many studies showed that the displacements are affected by the intensity and the direction of the pressure exerted [11, 29, 30]. The standardization of the applied pressure to induce the displacements of the tissue is the

► **Table 3** Mean differences in cervical stiffness measurements between different regions of interest.

cervical regions	mean difference	standard error	95% CI	significance
A3 – A1	11.345	1.567	8.176 – 14.514	0.000
A3 – A2	3.711	1.004	1.676 – 5.745	0.001
A3 – A4	9.983	1.623	6.700 – 13.267	0.000

Region A1: external and superior cervical lip. Region A2: internal and superior cervical lip. Region A3: internal and inferior cervical lip. Region A4: external and inferior cervical lip.

► **Table 4** Cronbach's alpha. Concordance analysis intra- and inter-operator measurements.

cervical region	intraoperator	interoperator
A1	0.931	0.870
A2	0.941	0.936
A3	0.937	0.889
A4	0.897	0.861

main limitation of the technique [3, 6, 7, 9]. Therefore, the strain depends on both the tissue's elasticity and the force applied.

As opposed to quasi-static elastography, TE is based on the propagation of shear waves within the tissue. Although the pressure applied by the practitioner influences the TE [31], it can be easier to control [12]. First, as the ultrasound beam creates the displacements, they are less user-dependent (i. e., more uniaxial) than those in hand-induced strain imaging [11]. Second, TE has a greater ability to target the area of evaluation. Ultrasound beams are successively focused at different depths to generate a quasi-plane shear wave that propagates through the tissue. Consequently, it can reach deeper areas of the cervix.

Regarding to hypothesis 3, significant variability within and between cervical regions was found. Our results show a longitudinal stiffness increment within the cervix, from external to internal parts (► **Fig. 2**, ► **Table 3**). The anterior part compared to the posterior part exhibits spatial variability too, but in a smaller degree. The largest differences in mean values appear in the internal part (regions A2 and A3), which presents a higher gradient, while the external part presents the least. This spatial variability is not surprising, and has already been reported by Carlson et al. [13]. In fact, the microstructure of the cervical extracellular matrix is composed of a dense, hydrated and highly cross-linked collagen network embedded in a viscous proteoglycan ground substance [32], far from a homogeneous material, and therefore variability within and between cervical regions is expected. During normal pregnancy the cervical extracellular matrix remodels in preparation for labor, and several changes occur progressively in its structure, in particular in the collagen network [21, 33]. The four cervical regions display different gradients, concretely the external part (regions A1 and A4) shows a lower stiffness gradient than

the internal part. This different sensitivity may be related to the micro-architecture of the cervix, suggesting that cervical ripening is heterogeneous in time within the tissue.

In our opinion, the anterior internal cervical lip (region A2) might be best for cervical stiffness assessment. This region showed stronger association with gestational age than the external part, and less internal variability than the internal posterior lip. The anterior cervical lip [2, 8] and internal os [4, 5] have been chosen by many authors to assess cervical stiffness. Furthermore, the anterior internal cervical lip (region A2) is close enough to the probe to guarantee shear wave propagation, and at the same time far from it to minimize the possible effects introduced by the pressure applied by the practitioner, which is impossible to avoid. Cervical tissue is a viscoelastic material, in which the elastic modulus is dependent on the frequency [34, 35]. In such a complex material, estimate the unavoidable strain contrast imposed by the practitioner is an important requirement in the development of cervical elastography [35, 36]. Thus, in order to obtain reproducible measurements, the pressure applied on the cervix by the sonographer with the probe has to be minimal.

Three cervical stiffness values could not be reliably quantified (1.79%) and these measurements had to be rejected from the study. The reasons were the reflections or perturbations of the shear waves in a particular imaging configuration, which made it impossible to measure velocity, and consequently no stiffness values were assessed.

The main limitations of this study are related to shear wave propagation and to the complex structure of cervical tissue. Transient elastography relies on the propagation of shear waves to estimate stiffness. Although it has demonstrated its successful application to diagnose diseases in many kinds of soft tissues [37, 38], its potential application to cervical tissue still remains unclear. Some assumptions, inappropriate for the cervix, are made to estimate the elasticity (Young's modulus), i. e., tissue is homogeneous, isotropic and semi-infinite [15]. Notwithstanding, cervical tissue is anisotropic and heterogeneous and its architecture is small relative to the shear wavelengths that are characteristic in dynamic elastography [13, 33, 34, 39]. Even though the election of a small ROI was based on that, to allow the assumption of homogeneous medium inside that ROI, future studies are necessary to understand shear wave tissue interactions within this complex medium.

On the other hand, as the main aim of this study was to explore the feasibility of TE to assess cervical ripening, a small sample size was employed. Thus, in order to generalize/extrapolate our findings to a general population, further studies with a larger sample size would be required. We are confident of our preliminary findings, and shear wave elastography has high potential to objectively detect early cervical ripening in human pregnancy that leads to delivery. In the future, complete studies in a larger population must be performed to determine if cervical stiffness quantified by shear wave elastography is a reliable tool to predict vaginal delivery and eventually preterm birth.

Conclusion

The results of this study demonstrate that cervical stiffness was more strongly associated with gestational age at examination and with interval time from elastography examination to delivery than with cervical length. Secondly, it is possible to objectively quantify cervical stiffness during pregnancy by shear wave elastography. We have shown that the measurements taken by the same and by two different observers for different regions in the cervix are reliable and reproducible. Finally, stiffness anatomically varies in the cervix. There is a positive stiffness gradient from external to internal and from posterior to anterior parts.

Elastography might provide additional information on the process of cervical effacement to that obtained from digital examination and conventional ultrasound. Further studies are needed to assess the feasibility of the technique in obstetric clinical applications, such as prediction of preterm birth or success in labor induction.

Conflict of Interest

The authors declare that they have no conflict of interest.

Danksagung

Spanish Ministerio de Economía for project DPI2010 – 17 065, Spanish Junta de Andalucía for projects P11-CTS-8089 and GGI3000IDIB, and the European Union for program “Programa Operativo FEDER de Andalucía 2007 – 2013”.

References

- [1] Khalil MR, Thorsen P, Ulbjerg N. Cervical ultrasound elastography may hold potential to predict risk of preterm birth. *Ultrasound in Obstetrics & Gynecology* 2013; 60: A4570
- [2] Köbbing K, Fruscalzo A, Hammer K et al. Quantitative elastography of the uterine cervix as a predictor of preterm delivery. *Journal of Perinatology* 2014; 1 – 7
- [3] Swiatkowska-Freund M, Preis K. Elastography of the uterine cervix: implications for success of induction of labor. *Ultrasound in Obstetrics & Gynecology* 2011; 38: 52 – 56
- [4] Pereira S, Frick AP, Poon LC et al. Successful induction of labor: prediction by pre-induction cervical length, angle of progression and cervical elastography. *Ultrasound in Obstetrics & Gynecology* 2014; 44: 468 – 475
- [5] Wozniak S, Czuczwar P, Szkodziak P et al. Elastography in predicting preterm delivery in asymptomatic, low-risk women: a prospective observational study. *BMC pregnancy and childbirth* 2014; 14: 238
- [6] Thomas A, Kmmel S, Gemeinhardt O et al. Real-time sonoelastography of the cervix: tissue elasticity of the normal and abnormal cervix. *Academic radiology* 2007; 14: 193 – 200
- [7] Molina FS, Gómez LF, Florido J et al. Quantification of cervical elastography: a reproducibility study. *Ultrasound in Obstetrics & Gynecology* 2012; 39: 685 – 689
- [8] Fruscalzo A, Schmitz R, Klockenbusch W et al. Reliability of cervix elastography in the late first and second trimester of pregnancy. *Ultraschall in der Medizin-European Journal of Ultrasound* 2012; 33: E101 – E107
- [9] Hernandez-Andrade E, Hassan SS, Ahn H et al. Evaluation of cervical stiffness during pregnancy using semiquantitative ultrasound elastography. *Ultrasound in Obstetrics & Gynecology* 2013; 41: 152 – 161
- [10] Feltovich H, Hall TJ. Quantitative imaging of the cervix: setting the bar. *Ultrasound in Obstetrics & Gynecology* 2013; 41: 121 – 128
- [11] Bamber J, Cosgrove D, Dietrich CF et al. EFSUMB guidelines and recommendations on the clinical use of ultrasound elastography. Part 1: Basic principles and technology. *Ultraschall in Med* 2013; 34: 169 – 184
- [12] Melodelima D, Bamber JC, Duck FA et al. Transient elastography using impulsive ultrasound radiation force: a preliminary comparison with surface palpation elastography. *Ultrasound in medicine & biology* 2007; 33: 959 – 969
- [13] Carlson LC, Feltovich H, Palmeri ML et al. Estimation of shear wave speed in the human uterine cervix. *Ultrasound in Obstetrics & Gynecology* 2014; 43: 452 – 458
- [14] Carlson LC, Romero ST, Palmeri ML et al. Changes in shear wave speed pre and post induction of labor: a feasibility study. *Ultrasound in Obstetrics & Gynecology Online-Publication*: 2014. DOI: 10.1002/uog.14663
- [15] Gennisson JL, Deffieux T, Fink M et al. Ultrasound elastography: Principles and techniques. *Diagnostic and interventional imaging* 2013; 94: 487 – 495
- [16] Peralta L, Mourier E, Richard C et al. 117 in vivo evaluation of the cervical stiffness evolution during induced labor in ewes using elastohraphy. *Reproduction, Fertility and Development* 2015; 27: 150 – 151
- [17] Cohen J. Statistical power analysis. *Current directions in psychological science* 1992: 98 – 101
- [18] Bercoff J, Tanter M, Fink M. Supersonic shear imaging: A new technique for soft tissue elasticity mapping. *IEEE Transactions On Ultrasonics Ferroelectrics and Frequency Control* 2004; 51: 396 – 409
- [19] Bercoff J, Tanter M, Fink M. Sonic boom in soft materials: The elastic cerenkov effect. *Applied Physics Letters* 2004; 84: 2202 – 2204
- [20] House M, Kaplan DL, Socrate S. Relationships between mechanical properties and extracellular matrix constituents of the cervical stroma during pregnancy. *Seminars in perinatology* 2009; 33: 300 – 307
- [21] Timmons B, Akins M, Mahendroo M. Cervical remodeling during pregnancy and parturition. *Trends in Endocrinology & Metabolism* 2010; 21: 353 – 361
- [22] George D, Mallery P. *SPSS for Windows step by step: A simple guide and reference*. 4th edition Allyn & Bacon; 2003
- [23] Tanter M, Bercoff J, Athanasiou J et al. Quantitative assessment of breast lesion viscoelasticity: initial clinical results using supersonic shear imaging. *Ultrasound in medicine & biology* 2008; 34: 1373 – 1386
- [24] Muller M, Gennisson JL, Deffieux T et al. Quantitative viscoelasticity mapping of human liver using supersonic shear imaging: Preliminary in vivo feasibility study. *Ultrasound In Medicine and Biology* 2009; 35: 219 – 229
- [25] Brum J, Bernal M, Gennisson JL et al. In vivo evaluation of the elastic anisotropy of the human achilles tendon using shear wave dispersion analysis. *Physics in medicine and biology* 2014; 59: 505 – 523

- [26] Gennisson JL, Muller M, Gabor P et al. Quantification of elasticity changes in the myometrium during labor using supersonic shear imaging: A feasibility study. *Ultrasonics Online-Publication* 2014. DOI: 10.1016/j.ultras.2014.07.013
- [27] Badir S, Mazza E, Zimmermann R et al. Cervical softening occurs early in pregnancy: characterization of cervical stiffness in 100 healthy women using the aspiration technique. *Prenatal diagnosis* 2013; 33: 737–741
- [28] Parra-Saavedra M, Gomez L, Barrero A et al. Prediction of preterm birth using the cervical consistency index. *Ultrasound in Obstetrics & Gynecology* 2011; 38: 44–51
- [29] Shamdasani V, Kim Y. Two-dimensional autocorrelation method for ultrasound-based strain estimation. In *Engineering in Medicine and Biology Society 2004. IEMBS'04. 26th Annual International Conference of the IEEE* 1: 1380–1383
- [30] Kim S, Aglyamov SR, Park S et al. An autocorrelation-based method for improvement of sub-pixel displacement estimation in ultrasound strain imaging. *Ultrasonics, Ferroelectrics, and Frequency Control, IEEE Transactions* 2011; 58: 838–843
- [31] Wojcinski S, Brandhorst K, Sadigh G et al. Acoustic radiation force impulse imaging with virtual touch tissue quantification: measurements of normal breast tissue and dependence on the degree of pre-compression. *Ultrasound in medicine & biology* 2013; 39: 2226–2232
- [32] Myers K, Socrate S, Tzeranis D et al. Changes in the biochemical constituents and morphologic appearance of the human cervical stroma during pregnancy. *European Journal of Obstetrics & Gynecology and Reproductive Biology* 2009; 144: S82–S89
- [33] Peralta L, Rus G, Bochud N et al. Mechanical assessment of cervical remodelling in pregnancy: insight from a synthetic model. *Journal of Biomechanics* 2015; 48: 1557–1565
- [34] Peralta L, Rus G, Bochud N et al. Assessing viscoelasticity of shear wave propagation in cervical tissue by multiscale computational simulation. *Journal of Biomechanics* 2015; 48: 1549–1556
- [35] Kiss MZ, Hobson MA, Varghese T et al. Frequency-dependent complex modulus of the uterus: preliminary results. *Physics in medicine and biology* 2006; 51: 3683–3695
- [36] DeWall RJ, Varghese T, Kliewer MA et al. Compression-dependent viscoelastic behavior of human cervix tissue. *Ultrasonic imaging* 2010; 32: 214–228
- [37] Wang Y, Insana MF. Viscoelastic properties of rodent mammary tumors using ultrasonic shear-wave imaging. *Ultrasonic imaging* 2013; 35: 126–145
- [38] Berg WA, Cosgrove DO, Doré CJ et al. Shear-wave elastography improves the specificity of breast us: the be1 multinational study of 939 masses. *Radiology* 2012; 262: 345–449
- [39] Yasar TK, Royston TJ, Magin RL. Wideband mr elastography for viscoelasticity model identification. *Magnetic Resonance in Medicine* 2013; 70: 479–489