Combined Surgical Treatment in Breast Cancer-Related Lymphedema

Jaume Masia, MD, PhD[1] Gemma Pons, MD[1] Maria Luisa Nardulli, MD[1]

[1] Department of Plastic Surgery, Hospital de la Santa Creu i Sant Pau (Universitat Autonoma de Barcelona), Barcelona, Spain

J Reconstr Microsurg 2016;32:16–27.

Address for correspondence Maria Luisa Nardulli, MD, Department of Plastic Surgery, Hospital de la Santa Creu i Sant Pau (Universitat Autonoma de Barcelona), Carrer de Sant Quintí, 89, 08026 Barcelona, Spain (e-mail: marialuisanardulli@gmail.com).

Abstract

Background Lymphedema is a well-known sequela of breast but no consensus has been reached about the ideal treatment. Surgical approaches, however, are receiving increased attention. Various microsurgical reconstructive techniques aim to restore anatomy and function of the lymphatic system in upper limb breast cancer-related lymphedema (BCRL). We combined two techniques, lymphaticovenous anastomosis (LVA) and autologous lymph node transplantation (ALNT) after carefully selecting those who may benefit from the surgery. We called this the "combined surgical treatment (CST)" approach.

Methods From June 2007 to December 2011, we performed CST in 106 patients with upper limb BCRL. Clinical evaluation and diagnostic imaging studies were performed preoperatively in all the patients. CST was offered to patients with stage I/II lymphedema, according to the criteria of the International Society of Lymphology (ISL).

Results Overall 59 of the 106 patients underwent LVA, 7 underwent ALNT, and 40 underwent both the techniques. All 47 lymph node (LN)-flaps survived but 11 (22%) required surgical revision within 3 days. A total of 21 LN-flaps (45%) showed no radiotracer uptake at 1 year. Around 1 to 7 LVAs for each patient (average 3.4) were performed. Preoperative versus postoperative excess circumference decreased between 12 and 86.7% (average 39.72%). Arm circumference decreased between 0.9 and 6.1 cm (average 2.75 cm). The number of episodes of lymphangitis per year decreased from 1.8 to 0.2.

Conclusion Preoperative assessment is essential to select patients who can benefit from surgery for lymphedema and to choose the best surgical approach in each case. Our satisfactory results in well-selected cases encourage further research into surgical treatment for BCRL.

Keywords
- lymphedema
- lymphaticovenous anastomosis
- autologous lymph node transplantation
- supermicrosurgery
- breast cancer-related lymphedema

Lymphedema is one of the most serious and disabling sequela secondary to breast cancer and its complementary treatments.[1,2] Several studies on quality of life[3,4] confirm that lymphedema is even more disabling than amastia or breast asymmetry because of its functional limitations, esthetic implications and higher risk of erysipelas or recurrent lymphangitis. Breast cancer-related lymphedema (BCRL) affects approximately 19 to 33% of breast cancer survivors who undergo axillary lymph node dissection (ALND) and radiation therapy (RT) and approximately 3.5 to 22% of breast cancer survivors who undergo sentinel node biopsy and RT.[5,6] Despite the recent trend to treat BCLR in early stages of the disease, a standard therapy has not yet been established. For many years, conservative medical and physical treatments

received
October 27, 2014
accepted after revision
December 3, 2014
published online
April 13, 2015

DOI http://dx.doi.org/10.1055/s-0035-1544182.
ISSN 0743-684X.

have been the primary choice for BCLR,[7] mainly because many centers have limited resources and because many physicians are skeptical about the effectiveness of surgical treatments.[8] Nevertheless, interest in surgical treatment for lymphedema has increased in many groups around the world in the last 10 years, and considerable advances have been achieved. Although no consensus has been reached about the most effective surgical procedure for BCLR, more and more experts now agree that surgery can be offered to patients with lymphedema as an effective alternative or complementary treatment to conservative therapy.[7]

Surgical techniques for BCRL can involve either excisional or reductive approaches, or reconstructive or physiological approaches. Excisional or reductive techniques consist of reducing subcutaneous tissue to limit excess bulk and weight of the affected limb. The most well-known of these techniques, the Charles[9] intervention (brachial dermolipectomy followed by skin grafting above muscular fascia), is rarely used today as its esthetic and functional results are poor. A more recently described reductive technique, which consists of vibroliposuction based on the Brorson[10,11] technique, has proven useful to reduce hypertrophic adipose tissue in organized nonpitting lymphedema. Regarding reconstructive or physiological techniques, the aim is to restore the affected lymphatic system, either through some form of lymph-venous[13–15] or lymph-lymphatic[16] anastomosis or through microsurgical lymph-node transfer techniques.[17]

We first undertook surgery for lymphedema in our breast unit in 2005 when we began to treat patients with BCRL with lymphaticovenous anastomosis (LVA).[13,14] In 2007, we started to perform autologous lymph node transplantation (ALNT)[17] to treat these patients. LVA and ALNT are both reconstructive techniques as they aim to restore a condition as similar as possible to the normal anatomy and function of the lymphatic system. We chose these techniques for their high reproducibility and low donor site morbidity. We made some changes in the original techniques described and, based on the results of the preoperative study, we use either one of the techniques alone, or a combination of the two. We always perform a preoperative study to select those patients who can truly benefit from surgical treatment and to choose the most appropriate surgical option in each case. We call this assessment and therapeutic approach "combined surgical treatment (CST)."

The aim of this article is to describe this CST for BCRL, its indications and results, and our decisional therapeutic algorithm (►**Fig. 1**).

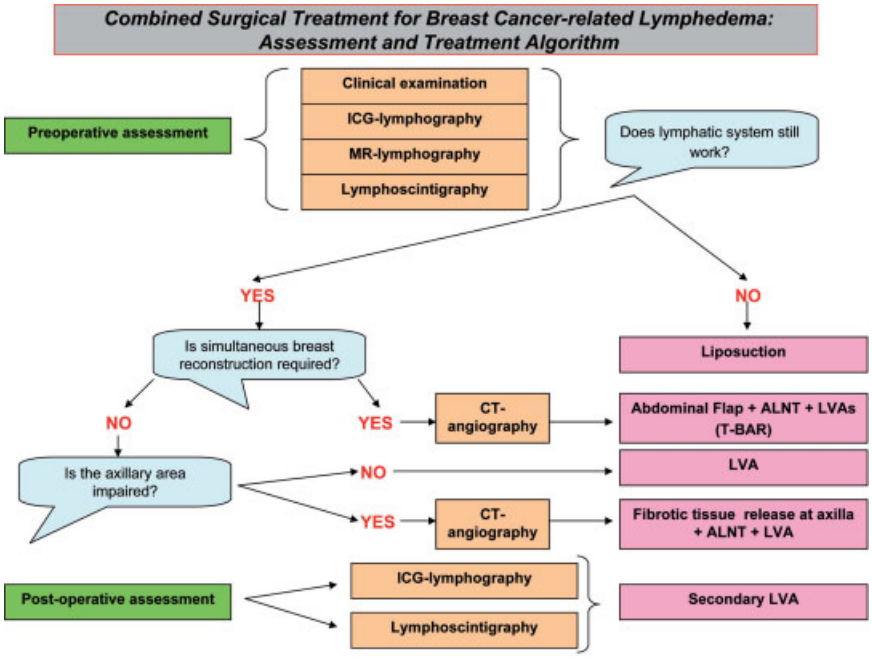

Fig. 1 Assessment and treatment algorithm that we follow to individualize treatment for each patient: To assess patients with lymphedema, we perform a clinical examination complemented by three imaging exams: ICG-lymphography, lymphoscintigraphy, and MR-lymphography. If there is no evidence of a functioning lymphatic system, we opt for a volume reduction technique (liposuction). If there is evidence of a functioning lymphatic system (i.e., contractile lymphatics) but with signs of impairment in the axillary area (i.e., radiodermitic tissue), we perform ALNT in the armpit after fibrotic tissue release, complemented by LVA in the affected limb. If there is evidence of a functioning lymphatic system without signs of an impairment in the axillary area, we opt for LVA; if there is evidence of a functioning lymphatic system and a patient with postsurgical amastia requests breast reconstruction, we opt for ALNT with nodes integrated into the abdominal flap (DIAEP or SIEA) and LVAs performed distally in the affected limb. After a 12 to 18 month follow-up, we check the feasibility of the reconstructive techniques applied. An ICG lymphography repeated 18 months after the LVA surgery can confirm or not the patency of an LVA. In case of ALNT, the lymphoscintigraphy indicates the degree of tracer uptake in the transplanted nodes, confirming or not their viability. Depending on the results obtained, we can propose a second LVA surgery. ALNT, autologous lymph node transplantation; DIAEP, deep inferior epigastric artery perforator flap; ICG, indocyanine green; LVA, lymphaticovenous anastomosis; MR, magnetic resonance; SIEA, superficial inferior epigastric artery flap.

Materials and Methods

From June 2007 to December 2011, we performed our CST in 106 patients with breast cancer-related upper limb lymphedema. CST was offered, as early as possible, to patients with stage I/II lymphedema, according to the criteria of the International Society of Lymphology (ISL) (►**Table 1**).[18] All patients underwent 3-monthly follow-up until 18 months postsurgery. Liposuction was reserved for later stages of lymphedema that were unlikely to improve by means of microlymphatic surgery (ISL stage III).

Description of the Preoperative Assessment

In our clinical practice, preoperative assessment consists of clinical evaluation and diagnostic imaging studies (►**Fig. 1**). In the clinical evaluation, we first measure the limb circumferences at predetermined anatomical levels. These measurements are taken preoperatively and postoperatively to verify the clinical postsurgical improvement (►**Fig. 2**). The differential diagnosis between pitting and nonpitting edema, together with the anamnestic data, allow us to define the lymphedema stage and choose the best therapeutic option for each patient. Nonpitting edema indicates a more advanced stage of the disorder, characterized by severe hypertrophy of adipose tissue. In such cases, a reductive technique is the most effective surgical approach.[10,11]

As the lymphatic system is a complex vascular system, we study its anatomy and functionality in each individual patient using diagnostic imaging techniques: lymphoscintigraphy, computed tomography angiography (CTA), indocyanine green (ICG) indirect lymphography, and magnetic resonance (MR)-lymphography (►**Fig. 1**).

A preoperative limb lymphoscintigraphy is performed for each patient to assess lymphatic function of the limb. It is repeated 12 months after the surgery to assess the

Table 1 Synthesis of the staging method we currently apply for lymphedema, drawn up by the International Society of Lymphedema (ISL)

Staging of Lymphedema[a]
Stage 0 (or Ia): latent or subclinical condition where swelling is not evident despite impaired lymph transport. It may exist months or years before overt edema occurs (Stages I–III)
Stage I: represents an early accumulation of fluid relatively high in protein content which subsides with limb elevation. Pitting may occur. An increase in proliferating cells may also be seen.
Stage II: limb elevation alone rarely reduces tissue swelling and pitting is manifest. Late in Stage II, the limb may or may not pit as tissue fibrosis supervenes.
Stage III: it encompasses lymphostatic elephantiasis where pitting is absent and trophic skin changes such as acanthosis, fat deposits, and warty overgrowths develop.

[a]Adapted from International Society of Lymphedema staging.[18]

Fig. 2 Limb circumferences are measured bilaterally at four predetermined anatomical levels: at the elbow (point zero), at 10 and at 20 cm below the elbow, and at 10 cm above the elbow. When the hand is affected, circumferences are also taken, distally to the thumb. (A) Figure shows the preoperative upper limb circumferences in a patient with right arm lymphedema. (B) Figure shows the postoperative improvement, which is more evident at the elbow and the proximal forearm.

improvement and the viability of lymphatic drainage in the transplanted LNs (►**Fig. 3**).

CTA is essential to plan surgery of ALNT. We assess the superficial circumflex iliac system and superficial inferior epigastric system, and locate the superficial inguinal LNs (►**Fig. 4**).[19]

In all patients, a preoperative ICG indirect lymphography by Photodynamic Eye (PDE, Hamamatsu Co., Japan) device is performed. This technique enables real-time enhancement of superficial and functional lymphatics, helping to identify the patent and functionally active lymphatic channels suitable for LVA surgery (►**Fig. 5**).

In 2010, we began to integrate ICG indirect lymphography and MR-lymphography[20–25] to optimize results. High-resolution T1-weighted MR-lymphography, by 3T magnetic resonance, (MAGNETOM Verio, Siemens, Erlangen, Germany) provides further detailed morphological, topographic and functional information about the lymphatics (►**Fig. 6**). Using this additional examination, we can visualize deep and superficial lymphatic channels after the intradermic injection of a contrast medium containing gadobenate dimeglumine (MultiHance, Bracco Imaging, Italy). Besides studying morphological and topographic data—such as lymphatic vessel size, appearance, location, and depth in subcutaneous tissue—we also investigate functional information. We inject a contrast medium to identify working lymphatic channels. Like ICG-lymphography, lymphatics enhanced by MR-lymphography are considered potentially suitable for LVA and the integration of data obtained by both MR-lymphography and ICG-lymphography allows us to reduce the false positives.

Surgical Techniques

Autologous Lymph Node Transfer

This concept is based on replacing the LNs in the axilla—surgically resected or damaged by adjuvant radiotherapy—for three to six nodes supplied by the superficial inferior epigastric or superficial circumflex iliac vessels (►**Fig. 7**).

Preoperatively, we study the donor area by multidetector CTA to assess the number of superficial LNs available and their relationship with the deep LNs. This imaging technique provides essential preoperative information about the localization of the LNs to be harvested. These LNs must be located superficially and laterally with the respect to common femoral vessels, so as to minimize donor site morbidity. Harvesting LNs located medial to femoral vessels would significantly increase the risk to induce an iatrogenic inferior limb lymphedema, as they are needed to drain the lymph from the inferior limb. Using a system of Cartesian axis, the LNs to be harvested are located almost exactly at the lower abdominal wall according to a combination of coordinates, as described previously for abdominal perforator flaps.[19] Therefore, CT is useful to define the size and course of the vessels that will vascularize the LNs to be harvested (►**Fig. 4**).

During surgery and before raising the flap, we also perform PDE lymphography after ICG injection into the foot web

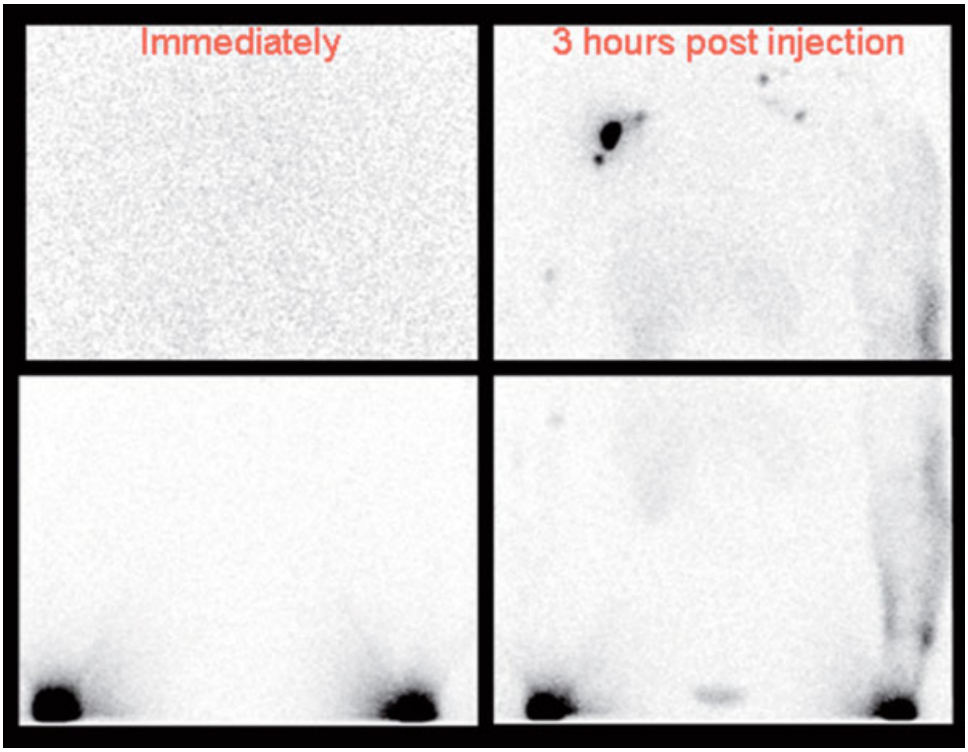

Fig. 3 Preoperative lymphoscintigraphy in a patient with left upper limb lymphedema following breast cancer treatment. Immediately acquired images show absence of transport of the radiotracer in both limbs (figures on the left). Images acquired 3 hours after administration of the radiotracer show uptake at right axillary and epitrochlear nodes and at supraclavicular left nodes, and absence of uptake in the left axilla. Dermal backflow, a sign of lymphatic drainage impairment, is evident in the left forearm.

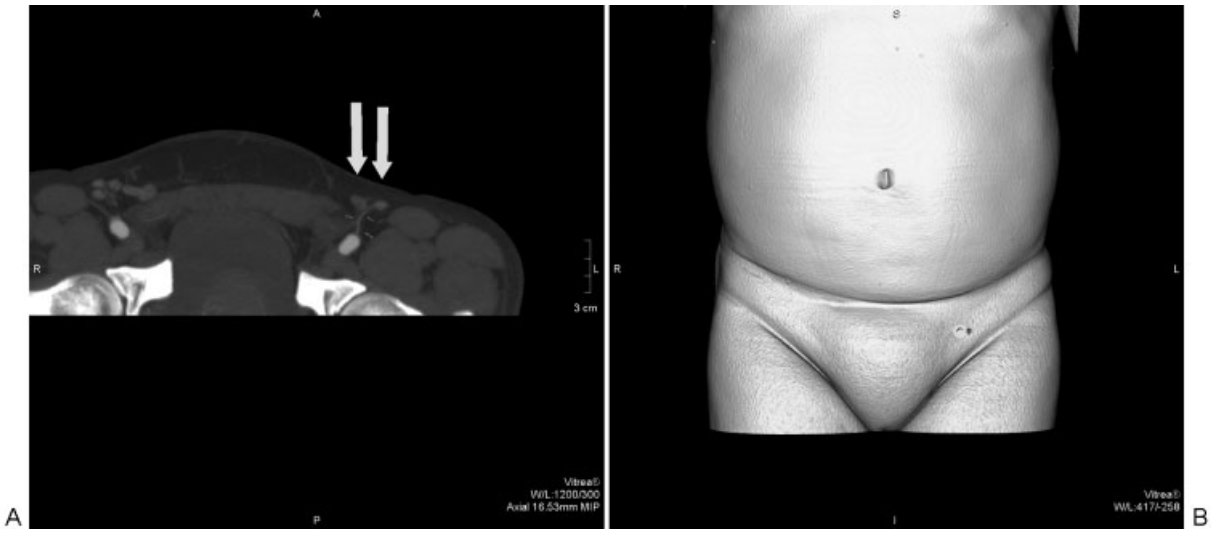

Fig. 4 (A) Axial view of CT-angiograms showing left superficial inguinal lymph nodes (two big arrows) and superficial circumflex iliac vessels (three little arrows). (B) 3D reconstruction of CT-angiography provides the exact location of nodes (big dot) and supplying vessels (little dot) at the cutaneous surface. 3D, three-dimensional; CT, computed tomography.

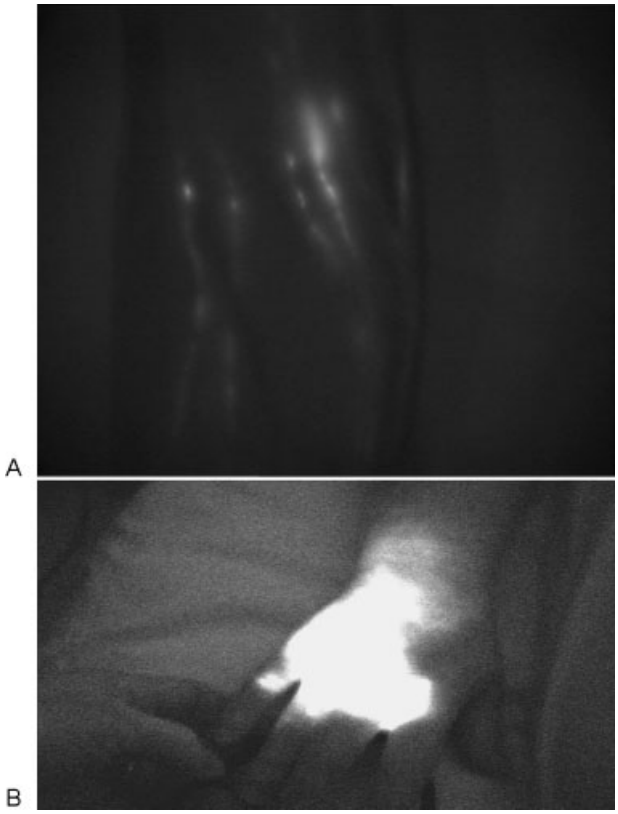

Fig. 5 (A) PDE image of ICG indirect lymphography showing several contractile lymphatic vessels with contractile units (lymphangions) that have captured and are transporting the dye. (B) Images showing accumulation of ICG dye on the dorsum of the left hand, after interdigital injection. In this case the dye is not transported by the lymphatic vessels, which may be absent, severely hypoplastic or lacking contractile capacity. ICG, indocyanine green; PDE, photodynamic eye.

spaces, to localize LNs that drain the lower limb. This is of crucial importance to avoid harvesting a flap containing these LNs, which could induce iatrogenic lower limb lymphedema.

Once the exact location of the donor LNs to be harvested is known, a skin island is designed above the inguinal ligament to provide skin tissue in the axillary region and for flap monitoring (►**Fig. 8A**).

Moreover, some minutes before starting the surgery, 0.2 to 0.4 mL of 2.5% patent blue dye V (Guerbet, Roissy-Charles-de-Gaulle, France) is injected intradermally, immediately above and below the anterior superior iliac spine to visualize intraoperatively the lymphatic vessels and nodes. The lymphatic channels afferent to donor LNs and stained by the dye can be more easily identified and linked so as to reduce the risk of recurrent seroma or lymphorrhoea. Furthermore, this approach identifies the nodes draining lymph from the lower abdominal area, so its combination with intraoperative ICG-lymphography is a useful double check to avoid harvesting LNs draining the inferior limb and reducing the possibility of iatrogenic lymphedema.

A small flap of approximately 8 × 4 cm is designed above the inguinal region. The lower marking is placed in the natural suprapubic crease, as for a standard abdominoplasty (►**Fig. 8A**). An exploratory incision is made along the lower marking of the flap to locate the nourishing LN-flap vessels. Careful dissection is needed to preserve the lateral femoral cutaneous nerve located in this area. The vascular pedicle is dissected gently up to the femoral vessels to obtain vessels of adequate caliber and a pedicle of adequate length. A skin adipose–LN flap containing three to six superficial inguinal LNs nourished by superficial epigastric vessels or superficial circumflex iliac vessels is raised (►**Fig. 8B**). The adipose tissue and the skin island included in the flap are useful to replace the fibrotic tissue in the axillary region. In some cases, the skin island is de-epithelized and buried in a second operative time, when monitoring of the flap is no longer necessary and skin elasticity at the recipient site allows.

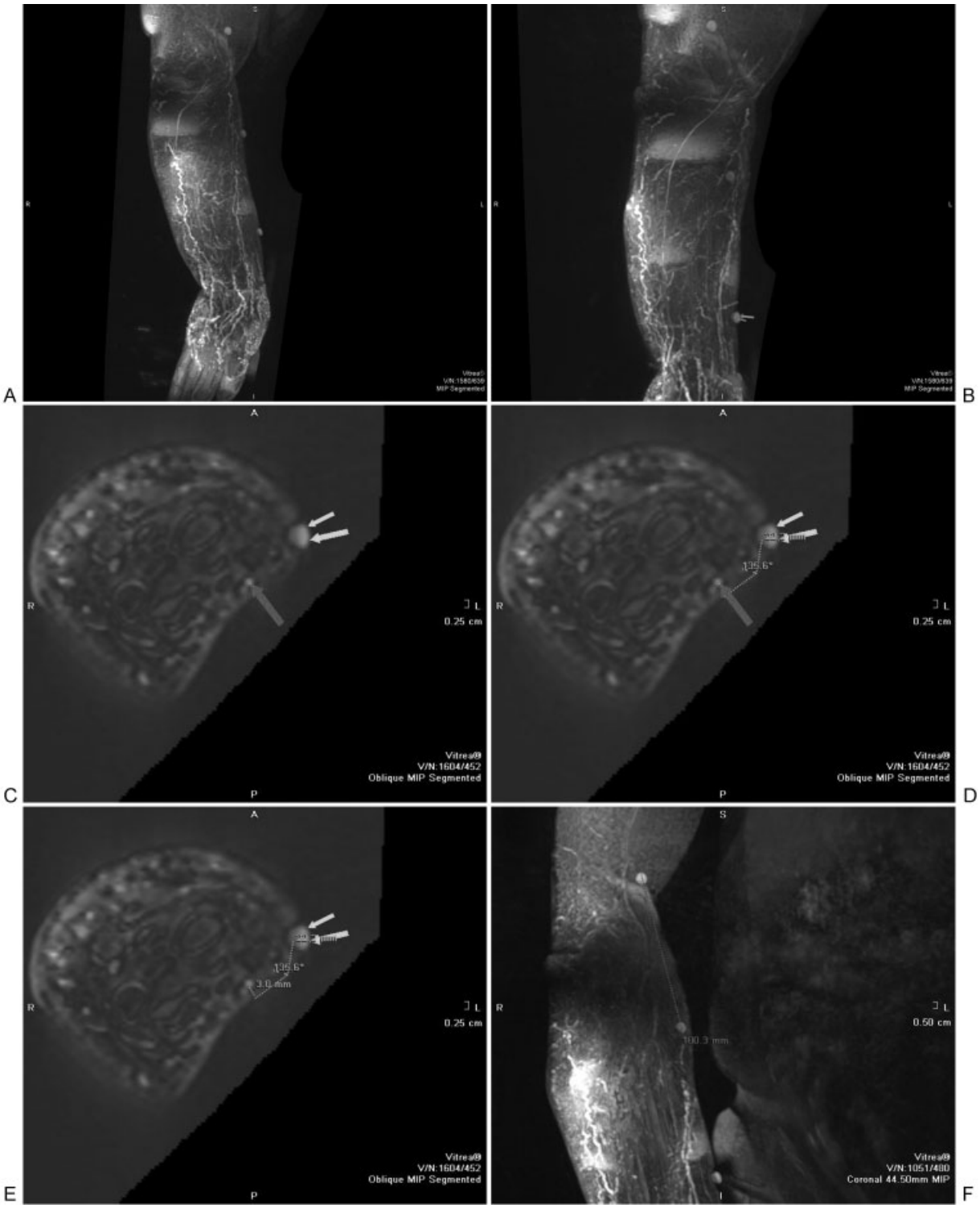

Fig. 6 MR-lymphography of a right arm with lymphedema. The 3D image shows several tortuous lymphatics (A). In a coronal (B) and axial (C) view, the bigger arrow shows a lymphatic vessel considered suitable for LVA, while the two smaller arrows indicate a hyperintense skin marker. The hyperintense skin marker is essential to localize the lymphatic vessel (D) and to know its depth in the subcutaneous tissue (E). Skin markers are located on the limb to be examined along a reference line, at points 10 cm apart, as shown in (F). Skin markers allow localizing the lymphatics according to a system of Cartesian axes, so as to know where to find them during LVA surgery. 3D, three-dimensional; LVA, lymphaticovenous anastomosis.

The donor site is closed primarily by a continuous spiral suture, using a monofilament strand with self-anchored spicules. This technique consists of a suture anchored in the deepest part of the LN donor site using an upward spiraling course. This is used to close donor site and avoid dead spaces which could favor seromas. Before closing the suture, a tissue sealant is used to close the small lymph channels sectioned. A suction drain is left in the donor area until the drainage is less than 15 mL/d.

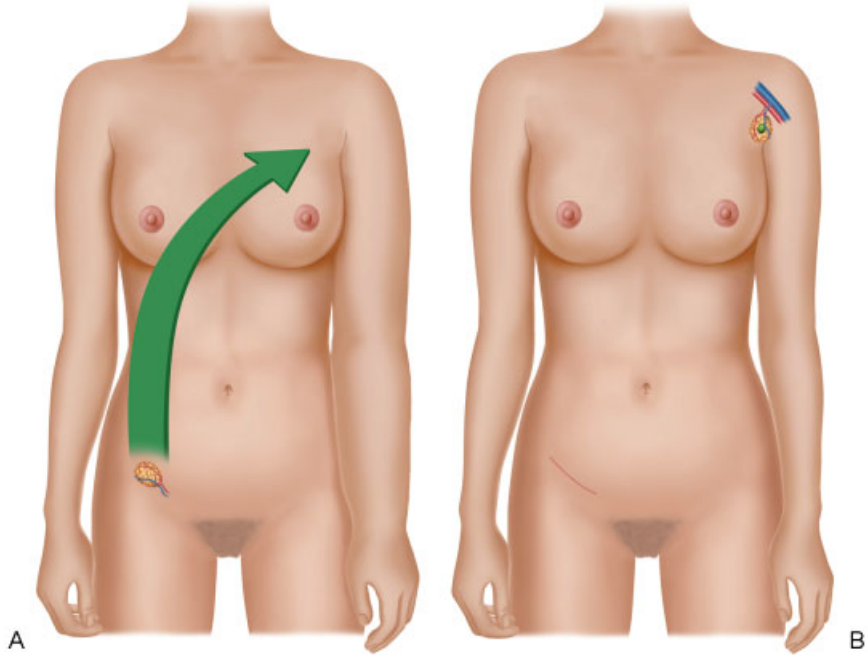

Fig. 7 (A and B) Diagrams showing the lymph node transfer surgical technique.

In relation to the recipient area, the axilla is the most commonly used site for LN transfer, and anastomosis is performed between donor vessels and vessels of the thoracodorsal system. Nevertheless, in selected cases and depending on the localization and distribution of lymphedema, the cubital fossa and midventral face of the wrist[26] are also used (►**Fig. 8C**).

In some cases, we approach lymphedema and autologous breast reconstruction simultaneously, using the deep inferior epigastric artery perforator (DIEAP) flap (LN–DIEAP flap). In these cases, we raise a compound flap with double vascularization. The LNs are vascularized by means of the superficial inferior epigastric vessels or superficial circumflex iliac vessels, and the DIEAP flap is vascularized by the deep inferior epigastric vessels. When an immediate breast reconstruction after mastectomy and nodal dissection is needed, we also perform lymph-lymphatic anastomosis between the upper limb lymphatic vessels and the afferent vessels from transplanted LNs with the purpose of preventive surgery for lymphedema. We named this new concept as "total breast anatomy restoration."

Lymphaticovenous Anastomosis

As previously described, a preoperative indirect lymphographic study using ICG is performed to assess the functionality of the lymphatic vessels (►**Fig. 5**). This technique allows us to visualize superficial lymphatic channels to a depth of 2 cm in the subcutaneous tissue.[12] We compare these superficial lymphatic channels with those of the contralateral healthy limb. Since 2010, we also perform a preoperative evaluation using MR-lymphography, as this technique reveals both superficial and deep lymphatic channels. It therefore increases the reliability of the preoperative localization of lymph channels tributary of LVA, reducing the number of false positives respect to PDE-lymphography alone.

On the day before surgery, we repeat the ICG-lymphography to mark the course of the lymphatic channels on the skin of the patient. The map obtained from the MR-lymphography is also transferred to the patient's skin. Based on the information provided by the two techniques, the first lymphatic channels selected to be explored and to perform anastomosis will be those located most proximally. Thus, if the anastomosis is feasible, we will be able to collect the largest amount of lymph from the distal limb portion.

The LVA procedure (►**Fig. 9**) is generally performed under general anesthesia to avoid patient discomfort in maintaining the same position on the operating table for several hours. A high magnification microscope is needed. At the selected cutaneous points and after injecting a small quantity of local anesthetic with epinephrine to reduce bleeding, we perform a cutaneous incision of 2 to 4 cm. Before performing this incision, we inject 0.1 to 0.2 mL of patent V blue about 2 cm distally to this point. The dye is usually absorbed by the functional lymphatics, and the blue stain inside the lymphatic channels makes identification and dissection easier. The lymph channels are carefully dissected and anastomosed end-to-end or end-to-side to subdermal venules of similar caliber using 11–0 or 12–0 sutures (►**Fig. 10**).

Postoperative Treatment and Assessment Protocol

In the immediate postoperative period, the treated limb is kept slightly elevated and the patient remains on bed rest for the first 2 days. During this period, the LN-flap is regularly monitored by clinical assessment of the skin island and Doppler ultrasound. Analgesic and antithrombotic therapy is the same as for any other surgery lasting over 4 hours.

Fig. 8 (A) A 77-year-old female patient undergoing lymph node transfer for left upper limb lymphedema. Preoperative markings of the flap and its nourishing vessels. (B) The adipocutaneous flap containing the nodes is harvested and its superficial circumflex iliac pedicle dissected. (C) The flap is transferred to the armpit and its vascular pedicle anastomosed with the thoracodorsal vessels.

Between the 3rd and 5th postoperative day, minimal mobilization—a few steps per day—is allowed. As of the 4th day, a soft elastic bandage is applied to the limb to increase the pressure gradient and improve the flow through the LVAs. Every 2 to 3 hours during the first 6 days, nurses gently massage the region immediately distally and proximally to the LVA, to improve the flow through the anastomosis.

After the 1st week, the protocol must be individualized because patient response to treatment is highly variable. Our standard protocol consists of recovering normal physical activity slowly but progressively over the first 3 weeks, avoiding exercise and postures that increase the venous pressure gradient of the limb. As various studies have shown that physical activity is essential to promote contractility of lymphatic channels and maintain the transport capacity, we recommend swimming or aquatic exercise from the 3rd week (2–3 times a week). Both LVA and ALNT need a minimum of 12 to 16 months to consolidate the new lymph–venous bypass in the case of LVA and the lymphoneogenesis from the transplanted LNs in the case of ALNT. During this time, patients should continue rehabilitation and avoid weight gain. A progressive decrease in limb volume is expected during this period. Regarding the donor site for ALNT, for the first 3 weeks, the patient is advised to wear cycling pants to maintain compression at the flap donor site.

Clinical postoperatively assessment is performed by measuring limb circumferences, taken every 3 months in the 1st year and then twice per year. Limb lymphoscintigraphy is repeated 12 months after surgery to verify lymph drainage improvement and to assess the transplanted LN viability. Limb lymphoscintigraphy can demonstrate the effectiveness of vascularized LN transplantation because transplanted nodes can be visualized and new lymph drainage pathways can appear.

Eighteen months after LVA surgery, we repeat the ICG lymphography if clinical improvement is poor. We evaluate the viability of other lymphatic channels and plan a second surgery to perform extra LVAs whenever possible.

Results

Of the 106 patients treated in the study period, 59 underwent LVA, 7 ALNT, and 40 both techniques.

All 47 LN-flaps survived, but 11 (22%) required a surgical revision in the first 3 days after the operation. Despite this, 21 LN-flaps (45%) did not show radiotracer uptake at 1 year postoperative LS. We performed 1 to 7 LVAs for each patient (average 3.4). The rate of preoperative versus postoperative excess circumference decreased in the range 12 to 86.7% (average 39.72%).

The circumference of the superior limb decreased 0.9 to 6.1 cm (average 2.75 cm).

The decrease was not constant. During the first 6 months, we observed that the volume reduction was more pronounced where LVAs were located. In the case of ALNT alone, volume reduction was more widespread.

The number of episodes of lymphangitis/year decreased from 1.8 to 0.2. Subjective benefits, such as improved limb softness, were confirmed by all patients.

The clinical improvement was most pronounced in the first 6-months postsurgery. No further clinical improvement was noted after 18 months and we therefore consider the results as stable after this period.

No donor site iatrogenic lymphedema was observed, except for one case in which the 18-month follow-up revealed a 2 cm enlargement of the thigh circumferences ipsilateral to the LN-donor site (left) compared with the contralateral

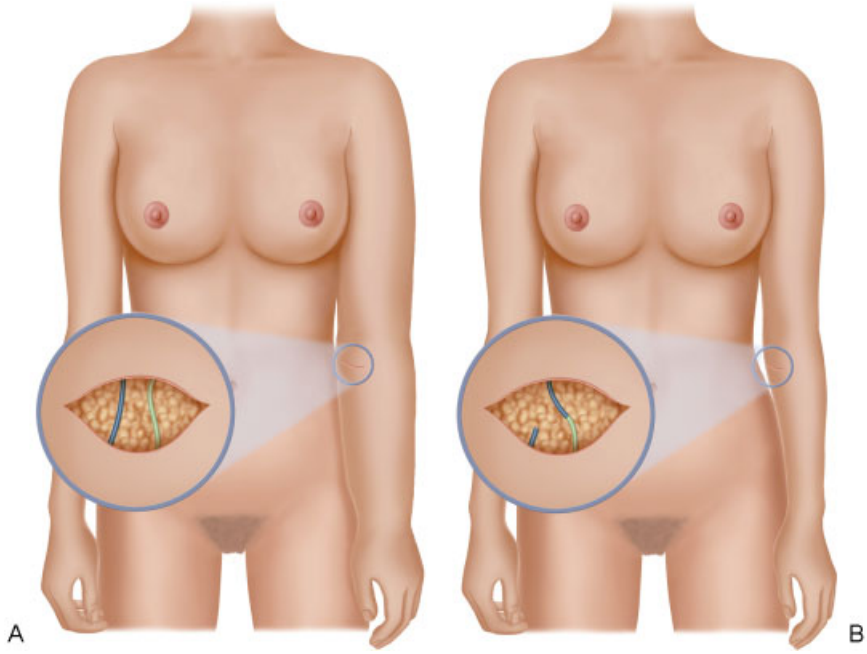

Fig. 9 (A and B) Diagrams showing lymphaticovenous anastomosis technique.

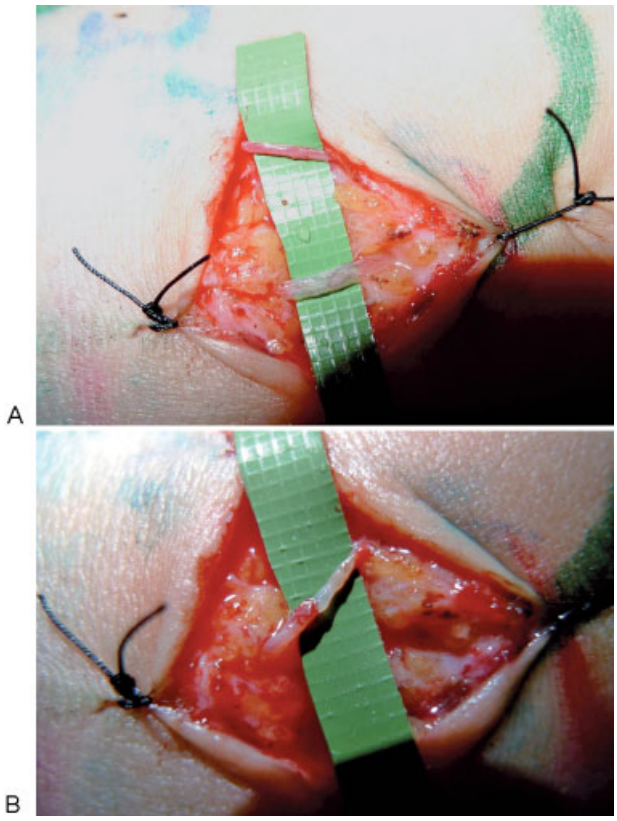

Fig. 10 (A) Intraoperative view of a subdermal lymphatic vessel (translucid) and a subdermal venule located at the point marked preoperatively with both ICG-lymphography and MR-lymphography. (B) Intraoperative view of the termino–terminal anastomosis between the distal stump of the lymphatic vessel and the proximal stump of the venule. Lymph can be seen flowing through the anastomosis along the vein. ICG, indocyanine green; MR, magnetic resonance.

thigh. Furthermore, in this patient the immediate lymphoscintigraphic images showed tracer migration only in the right inferior limb, with no significant drainage in the left limb. Images acquired 180 minutes after the injection showed correct lymphatic flow in the right limb and significant drainage in the left limb, with no dermal backflow.[41] Findings were judged compatible with left superficial inguinal LN harvesting and compatible with the results of Viitanen et al,[28] assessed by experienced nuclear medicine physicians. Follow-up at 30 months in this patient showed no worsening of subclinical lymphedema.

Discussion

Interest in understanding the physiopathology of the lymphatic system is increasing as part of the drive to find a curative treatment for lymphedema. Although conservative medical and physical approaches have been the primary choice for lymphedema treatment for many years, surgery is gaining relevance as an effective alternative or a complementary treatment to conservative therapy.[7] Nevertheless, the overall efficacy[8] of lymphatic surgery is still surrounded by certain skepticism, and a consensus on the ideal surgical procedure is lacking.[7]

Our interest in lymphatic surgery started in 2005 when several breast cancer patients who had undergone reconstruction with abdominal perforator flaps sought a solution for superior limb lymphedema. After investigating the different surgical procedures performed in other centers at that time for lymphedema, we realized that the surgical procedure used was the same, independently of the grade and etiology of lymphedema. Furthermore, the highly variable results prompted us to consider that a first step in lymphedema surgery should be to individualize treatment on the basis of a

preoperative assessment. On these grounds, we began to perform a preoperative study with lymphoscintigraphy, ICG-indirect lymphography and, somewhat later, also with MR-lymphography, to determine which patients would be candidates for surgical treatment and what technique would be the best option for each patient.

Imaging assessment of the lymphatic system allows a personalized surgical treatment depending on the etiology and grade of lymphedema and the functional status of the lymphatic system. As explained above, we named our assessment and therapeutic approach the "combined surgical treatment" or "Barcelona cocktail" (►**Fig. 1**).

Based on the results of preoperative assessment, we consider that patients who have no functional lymphatic channels cannot benefit from reconstructive procedures, and that reductive surgery is the most suitable option in such cases[10,11] to improve their cosmesis and quality of life. We consider that those patients who may benefit from LVA[13,14] or ALNT[17] or the combination of both techniques are those in whom preoperative studies show a minimally functional lymphatic system and the clinical evaluation assesses the lymphedema as stage I or II, according to ISL staging. Our interest in the combination of the two procedures arose from the fact that they are complementary techniques with reliable reproducibility and controlled donor site morbidity.

As early as the 1930s, Sir Harold Gillis[32] described the first attempt to anastomose lymphatic channels of a lymphedematosous leg with those of a healthy arm in a 28-year-old female patient, by "juxta position". Lymphovenous bypass operation for treatment of lymphedema was first reported by Yamada[27] in the 1960s and popularized by O'Brien and colleagues in 1970.[29,31] Following the report by O'Brien, several plastic surgeons attempted LVA. These attempts failed and the technique was abandoned for many years. It was not until the early 21st century that the technique was reintroduced. This time, however, there were several differences as a consequence of developments in supermicrosurgery. This concept of supermicrosurgery[13,33] was introduced by Koshima et al. It consists of managing very fine structures (lymphatic channels and venules) with a diameter of less than 0.8 mm and performing microsurgical anastomosis between them.[13] LVA is a low-invasive technique and end-to-end or end-to-side anastomosis can be performed between subdermic venules and functional lymphatic channels. Based on these shunts, this supermicrosurgical technique aims to redirect excess lymph fluid accumulated in the limb to the venous system, directly bypassing the impaired lymphatic system.[30,34] This procedure is now possible due to the recent appearance of high magnification microscopes, extremely fine supermicrosurgical instruments, and 11–0, 12–0 sutures. Another major advance is that the specific diagnostic imaging techniques available today show the exact location of the functional lymphatic vessels suitable for anastomosis, while the technique was approached blindly in the past.

LVA can be combined with ALNT. As breast cancer patients with lymphedema have undergone ALND, complemented in some cases with radiotherapy, surgical scarring at the axilla, and block of this area is expected. As a consequence, the axillary lymphatic system is seriously impaired, causing the lymphedema. Our aim is to mimic, as far as possible, normal anatomy and function of the lymphatic system by means of ALNT. Since Becker first described an inguinal fatty flap containing LNs for arm lymphedema treatment,[17] other LN donor sites have been described.[35] We consider superficial inferior epigastric nodes are the best option for harvest because the scar is inconspicuous, and till date, morbidity at the donor site has been found to be low. In the literature, Vignes et al[36] recently reported six cases of chronic LN-donor site lymphedema in a series of 34 ALNT performed in 26 patients, and Viitanen et al.[28] described unexpected changes in lymphatic transport in the leg after ALNT, despite absence of clinical lymphedema. Together with our experience of a case of lymphedema in the lower limb due to ALNT,[41] these data indicate that ALNT is not a complication-free procedure and donor site sequela should be prevented by performing meticulous dissection and avoiding unnecessary scarring. Moreover, great care is needed to harvest only those LNs responsible for drainage of the lower abdomen wall so as to avoid lower limb lymphedema. Recently, the anatomic relationship between such LNs and the superficial inferior epigastric vein, the superficial circumflex iliac vessels, the inguinal ligament, and the groin crease has been clarified.[38]

In our experience, an effective double-check method to prevent harvesting LNs that drain the lower limb is to inject patent V blue at the iliac crest and perform an intraoperative ICG lymphography. Preoperative multidetector CTA are also particularly useful to define the size and course of the vessels that vascularize the LNs to be harvested, to assess the highly variable number and distribution of these LNs, and to locate these superficially at the lower abdominal wall, above and lateral to femoral vessels, according to a combination of coordinates in a system of Cartesian axis.[19] Harvesting LNs located medial to femoral vessels significantly increases the risk of iatrogenic inferior limb lymphedema, as these LNs should drain the lymph from the inferior limb.

The intraoperative procedures described, together with the preoperative assessment performed for each patient and the harvesting of a LN-flap containing both fat and skin island, are the main differences in respect to the original technique described by Becker.

ALNT combines microsurgical expertise with current advances in lymphangiogenesis research. As LNs produce vascular endothelial growth factor-C—considered the main promotor of lymphangiogenesis—lymphatic connections are expected to form spontaneously within 6 months.[39] In our experience, however, 45% of LN-flaps did not show radiotracer uptake in the 1-year postsurgery lymphoscintigraphy, even though the skin island showed good flap perfusion. One possible explanation for this failure is that the expected lymphangiogenesis did not occur spontaneously after ALNT and the transplanted LNs did not establish connections with the existing lymphatic network, as suggested in recent clinical and experimental data.[37,39] We hypothesize that this lack of connection may be related to LN compression

in the armpit or impairment of the axillary tissue resulting from previous radiotherapy and surgery.

Conclusion

"CST" for BCRL offers the patient treatment that includes both LVA and ALNT. The essential concept for improving the disorder is that the impaired lymphatic system retains at least a minimal functionality. Residual functionality should be assessed preoperatively using ICG-indirect lymphography and MR-lymphography. Patients with no functional lymphatic system can undergo either an excisional procedure or vibroliposuction to improve their cosmesis and quality of life.

Although none of the techniques described to date for lymphedema treatment are ideal, we have achieved satisfactory results performing our "CST" in well-selected cases. Our results have improved over the years, not only as a result of the learning curve but also in view of our previously described approach to selecting candidates to surgery.

In conclusion, despite promising results, surgical treatment for lymphedema is still in its early days. In the future we need to standardize protocols for preoperative studies and surgical treatment. Comparative prospective studies with uniform patient selection will be required, to clarify the real contribution of microlymphatic surgery for the treatment of BCRL.[40] Moreover, we need to further our understanding of the anatomy and physiology of the lymphatic system and of the pathophysiology of lymphedema, especially through studies in vivo. To reach these targets we will require further development of highly specific imaging techniques to gain additional functional information.

Funding
None.

Disclosure
None.

References

1 Recent advances in breast cancer-related lymphedema detection and treatment. Avon Foundation for Women, 2011. Available at: http://www.avonfoundation.org/assets/le-meeting/le-white-paper.pdf. Accessed on 19 April 2011
2 Bernas M, et al. Lymphedema: how do we diagnose and reduce the risk of this dreaded complication of breast cancer treatment? Current Breast Cancer Reports 2010;2(1):53–58
3 Crosby MA, Card A, Liu J, Lindstrom WA, Chang DW. Immediate breast reconstruction and lymphedema incidence. Plast Reconstr Surg 2012;129(5):789e–795e
4 Chachaj A, Małyszczak K, Pyszel K, et al. Physical and psychological impairments of women with upper limb lymphedema following breast cancer treatment. Psychooncology 2010;19(3):299–305
5 Armer J, Fu MR, Wainstock JM, Zagar E, Jacobs LK. Lymphedema following breast cancer treatment, including sentinel lymph node biopsy. Lymphology 2004;37(2):73–91
6 Ashikaga T, Krag DN, Land SR, et al; National Surgical Adjuvant Breast, Bowel Project. Morbidity results from the NSABP B-32 trial comparing sentinel lymph node dissection versus axillary dissection. J Surg Oncol 2010;102(2):111–118
7 Rausky J, Robert N, Binder JP, Revol M. In search of the ideal surgical treatment for lymphedema. Report of 2nd European Conference on supermicrosurgery (Barcelona - March 2012) [in French]. Ann Chir Plast Esthet 2012;57(6):594–599
8 Földi M. Treatment of lymphedema. Lymphology 1994;27(1):1–5
9 Charles RH. Elephantiasis Scroti. In: Latham A, English TC, eds. A System of Treatment. Vol. 3. London: Churchill; 1912
10 Brorson H, Svensson H. Liposuction combined with controlled compression therapy reduces arm lymphedema more effectively than controlled compression therapy alone. Plast Reconstr Surg 1998;102(4):1058–1067, discussion 1068
11 Brorson H. Liposuction gives complete reduction of chronic large arm lymphedema after breast cancer. Acta Oncol 2000;39(3):407–420
12 Mihara M, Hara H, Araki J, et al. Indocyanine green (ICG) lymphography is superior to lymphoscintigraphy for diagnostic imaging of early lymphedema of the upper limbs. PLoS ONE 2012;7(6):e38182
13 Koshima I, Inagawa K, Urushibara K, Moriguchi T. Supermicrosurgical lymphaticovenular anastomosis for the treatment of lymphedema in the upper extremities. J Reconstr Microsurg 2000;16(6): 437–442
14 Koshima I, Nanba Y, Tsutsui T, Takahashi Y, Itoh S, Fujitsu M. Minimal invasive lymphaticovenular anastomosis under local anesthesia for leg lymphedema: is it effective for stage III and IV? Ann Plast Surg 2004;53(3):261–266
15 Campisi C, Boccardo F. Lymphedema and microsurgery. Microsurgery 2002;22(2):74–80
16 Baumeister RG, Siuda S. Treatment of lymphedemas by microsurgical lymphatic grafting: what is proved? Plast Reconstr Surg 1990;85(1):64–74, discussion 75–76
17 Becker C, Assouad J, Riquet M, Hidden G. Postmastectomy lymphedema: long-term results following microsurgical lymph node transplantation. Ann Surg 2006;243(3):313–315
18 International Society of Lymphology. The diagnosis and treatment of peripheral lymphedema. 2009 Concensus Document of the International Society of Lymphology. Lymphology 2009;42(2):51–60
19 Masia J, Clavero JA, Larrañaga JR, Alomar X, Pons G, Serret P. Multidetector-row computed tomography in the planning of abdominal perforator flaps. J Plast Reconstr Aesthet Surg 2006; 59(6):594–599
20 Notohamiprodjo M, Baumeister RG, Jakobs TF, et al. MR-lymphangiography at 3.0 T—a feasibility study. Eur Radiol 2009;19(11): 2771–2778
21 Lohrmann C, Felmerer G, Foeldi E, Bartholomä JP, Langer M. MR lymphangiography for the assessment of the lymphatic system in patients undergoing microsurgical reconstructions of lymphatic vessels. Microvasc Res 2008;76(1):42–45
22 Lohrmann C, Foeldi E, Langer M. MR imaging of the lymphatic system in patients with lipedema and lipo-lymphedema. Microvasc Res 2009;77(3):335–339
23 Liu NF, Lu Q, Jiang ZH, Wang CG, Zhou JG. Anatomic and functional evaluation of the lymphatics and lymph nodes in diagnosis of lymphatic circulation disorders with contrast magnetic resonance lymphangiography. J Vasc Surg 2009;49(4):980–987
24 Arrivé L, Azizi L, Lewin M, et al. MR lymphography of abdominal and retroperitoneal lymphatic vessels. AJR Am J Roentgenol 2007; 189(5):1051–1058
25 Liu N, Zhang Y. Magnetic Resonance Lymphangiography for the Study of Lymphatic System in Lymphedema. J Reconstr Microsurg 2014 (epub ahead of print) DOI: 10.1055/s-0034-1384213
26 Patel KM, Lin CY, Cheng MH. From Theory to Evidence: Long-Term Evaluation of the Mechanism of Action and Flap Integration of Distal Vascularized Lymph Node Transfers. J Reconstr Microsurg 2014
27 Yamada Y. The studies on lymphatic venous anastomosis. Nagoya J Med Sci 1969;32:1–21

28 Viitanen TP, Mäki MT, Seppänen MP, Suominen EA, Saaristo AM. Donor-site lymphatic function after microvascular lymph node transfer. Plast Reconstr Surg 2012;130(6):1246–1253
29 O'Brien BM, Shafiroff BB. Microlymphaticovenous and resectional surgery in obstructive lymphedema. World J Surg 1979;3(1):3–15, 121–123
30 Mihara M, Hara H, Hayashi Y, et al. Upper-limb lymphedema treated aesthetically with lymphaticovenous anastomosis using indocyanine green lymphography and noncontact vein visualization. J Reconstr Microsurg 2012;28(5):327–332
31 O'Brien BM, Mellow CG, Khazanchi RK, Dvir E, Kumar V, Pederson WC. Long-term results after microlymphaticovenous anastomoses for the treatment of obstructive lymphedema. Plast Reconstr Surg 1990;85(4):562–572
32 Gillies H, Fraser FR. Treatment of Lymphedema by plastic operation (A preliminary report). BMJ 1935;1(3863):96–98
33 Masià J, Olivares L, Koshima I, et al. Barcelona consensus on supermicrosurgery. J Reconstr Microsurg 2014;30(1):53–58
34 Mihara M, Hara H, Iida T, et al. Antegrade and retrograde lymphatico-venous anastomosis for cancer-related lymphedema with lymphatic valve dysfuction and lymphatic varix. Microsurgery 2012;32(7):580–584
35 Becker C, Vasile JV, Levine JL, et al. Microlymphatic surgery for the treatment of iatrogenic lymphedema. Clin Plast Surg 2012;39(4): 385–398
36 Vignes S, Blanchard M, Yannoutsos A, Arrault M. Complications of autologous lymph-node transplantation for limb lymphoedema. Eur J Vasc Endovasc Surg 2013;45(5):516–520
37 Lähteenvuo M, Honkonen K, Tervala T, et al. Growth factor therapy and autologous lymph node transfer in lymphedema. Circulation 2011;123(6):613–620
38 Dayan JH, Dayan E, Kagen A, et al. The use of magnetic resonance angiography in vascularized groin lymph node transfer: an anatomic study. J Reconstr Microsurg 2014;30(1):41–45
39 Tammela T, Saaristo A, Holopainen T, et al. Therapeutic differentiation and maturation of lymphatic vessels after lymph node dissection and transplantation. Nat Med 2007;13(12):1458–1466
40 Penha TR, Ijsbrandy C, Hendrix NA, et al. Microsurgical techniques for the treatment of breast cancer-related lymphedema: a systematic review. J Reconstr Microsurg 2013;29(2):99–106
41 Masia J, Pons G, Loschi P, Nardulli ML, Duch J. A case of donor site lymphedema after lymph node-superficial circumflex iliac artery perforator flap transfer. J Plast Reconstr Aesthet Surg 2014;67(1): 119–123