Grading Facial Nerve Function Following Combined Static and Mimetic Surgical Techniques

John P. Leonetti[1] Sam J. Marzo[1] Douglas A. Anderson[2] Joshua M. Sappington[1]

[1] Department of Otolaryngology-Head and Neck Surgery, Loyola University Medical Center, Maywood, Illinois, United States
[2] Department of Neurological Surgery, Loyola University Medical Center, Maywood, Illinois, United States

Address for correspondence John P. Leonetti, MD, Department of Otolaryngology-Head and Neck surgery, Loyola University Medical Center, 2160 1st Avenue, Maywood, IL 60153, United States (e-mail: jleonet@lumc.edu).

J Neurol Surg B 2015;76:416–420.

Abstract

Objective To present a grading scale to assess the functional recovery of the facial nerve in patients who have undergone mimetic and static surgical techniques for facial reanimation.

Study design This is a proposed new facial nerve grading system that will be demonstrated with specific case presentations. All patients underwent a variety of neural grafting, microvascular free-flap reconstruction, or surgical static procedures.

Results The proposed facial nerve grading scale is one that has not been described previously in the literature and is applicable to a unique patient population. Its ease of use in this patient population will allow otolaryngologists to assess facial recovery accurately and quickly in cases where the facial nerve is not anatomically intact.

Conclusion The proposed facial recovery grading scale provides an efficient means of grading facial recovery for a unique group of patients who previously could not be followed. The proposed scale is practical and easy to use in a clinical setting.

Keywords
- facial nerve paralysis
- facial recovery
- grading scale

Introduction

Facial paralysis has a profound functional, cosmetic, and psychological impact on affected patients. A variety of facial nerve grading systems have been described in the literature. The most commonly used grading method is the House-Brackmann grading scale that was adopted by the American Academy of Otolaryngology-Head and Neck Surgery in 1985.[1] Other notable facial grading scales include the Sunnybrook, Yanagihara, Nottingham, and Sydney.[2–5] The most commonly used facial nerve grading systems were designed to assess progressive neural recovery with an anatomically intact facial nerve.[6] In their initial paper, House and Brackmann state that their facial nerve grading scale was intended to assess facial nerve recovery of an intact nerve.[7] Patients who undergo surgical procedures for advanced lateral skull base tumors that require facial nerve and adjacent musculature resection and cases of long-standing facial nerve paralysis often require multiple static and mimetic procedures to optimize cosmetic result and return of long-term function.[8,9] These can include the use of free muscle transfer, in conjunction with neural grafting, oculoplastic techniques, and static soft tissue tightening procedures.

Existing facial recovery grading scales do not accurately assess this patient population. Individuals in this population are often automatically assigned a House-Brackmann score of 3 or 4.[6] This void prevents clinicians from properly describing and communicating facial reanimation in this unique patient population.

Methods

The proposed facial recovery grading scale demonstrated in ►**Table 1** divides facial recovery assessment into three areas: the periorbital, midface, and synkinesis. All three of these areas play a prominent role in determining functional recovery and cosmetic results following facial reanimation.

received
February 18, 2013
accepted after revision
May 27, 2014
published online
May 22, 2015

DOI http://dx.doi.org/10.1055/s-0034-1386652.
ISSN 2193-6331.

Table 1 Proposed facial recovery grading scale

Category	Score	Objective assessment		
Periorbital	0	Corneal show		
	1	Scleral show	**Point total**	**Grade**
	2	Complete closure	5–6	A
Midface	0	No movement	4	B
	1	Minimal movement	3	C
	2	Nasolabial pulling	2	D
Synkinesis	0	Severe	0–1	F
	1	Minimal		
	2	No movement		

The scoring for each region is based on a 0 to 2 point scale with 2 points indicating the best level of function and zero indicating the worst level of function. For example, with regard to eye closure, patients with corneal show are awarded 0 points and patients with complete eye closure are awarded 2 points. The cumulative point total from the three areas of assessment determine the patients' overall function and their letter grade. Grading patient overall function ranges from A to F with A the best function and F the worst level of functioning and cosmesis. Letter grades were chosen because they are an efficient means of communicating patients' function because the vast majority of clinicians are familiar with the ABC grading scale.

Results

The three patients in this study underwent surgical resections that sacrificed the facial nerve and adjacent musculature or developed long-standing paralysis of the facial nerve. Each patient's facial recovery was graded utilizing the proposed facial recovery grading system. Each patient has three pictures seen in ►**Figs. 1–9**, one demonstrating resting tone, and two showing function in the periorbital and midface regions.

Case 1: A 53-year-old man underwent a right parotidectomy and radiation therapy outside of the LUMC health care system for adenoid cystic carcinoma. He subsequently developed a recurrence. When he presented to LUMC, his facial nerve was intact and symmetric. This man underwent a right preauricular-infratemporal fossa approach for right radical parotidectomy with ipsilateral selective neck dissection. He was reconstructed with an anterolateral thigh free flap and medial antebrachial nerve graft. The only additional surgical procedure he underwent was debulking of his free flap 3 months postoperatively. The photographs here are ~ 26 months following his initial surgery. Additionally he did not require any botulinum toxin injections or physical therapy. He would be awarded a total of 5 points: 2 points for complete eye closure, 2 points for nasolabial pull, and 1 point for minimal synkinesis.

Fig. 1 Patient 1 demonstrating resting tone.

Case 2: A 64-year-old man underwent a right parotidectomy with facial nerve preservation outside the LUMC health care system for adenoid cystic carcinoma with disease at the stylomastoid foramen and around the facial nerve. When he presented at Loyola he had complete right facial paralysis. He underwent a preauricular-infratemporal fossa approach for radical parotidectomy and selective neck dissection. This defect was reconstructed with a right serratus free flap, right sural nerve graft, and had a 1.4-g platinum weight placed. Additionally this patient underwent postoperative radiation therapy at LUMC. The images are ~ 18 months from his initial surgery. He did not undergo any botulinum toxin injections or physical therapy. This patient would be awarded a total of 4



Fig. 2 Patient 1 demonstrating complete eye closure. He would be awarded 2 points for this level of function.

Fig. 3 Patient 1 demonstrating midface movement. He would be awarded 2 points for midface movement and 1 point for mild of synkinesis. This man would be awarded a total of 5 points for grade A function.



Fig. 5 Patient 2 demonstrating complete eye closure. He would be awarded 2 points for this level of function.

points for grade B function: 2 points for complete eye closure, 1 point for mild midface movement, and 1 point for minimal synkinesis.

Case 3: A 74-year-old woman underwent right translabyrinthine craniotomy in 2006 for an 2.2-cm acoustic neuroma that was noted intraoperatively to be adherent to the facial nerve. This patient had slight right-sided synkinesis with intact facial function following this initial surgery. She developed a recurrent 2.5-cm acoustic neuroma and underwent right transcochlear craniotomy in 2010. She underwent



Fig. 4 Patient 2 demonstrating resting tone.



Fig. 6 Patient 2 demonstrating some midface movement with minimal synkinesis. One point would be awarded for each area of assessment. He would be awarded a total of 4 points.



Fig. 7 Patient 3 demonstrating resting facial tone.



Fig. 9 Patient 3 demonstrating no detectable midface movement earning no points and minimal synkinesis earning 1 point. She would be awarded a total of 3 points for grade C function.

canthoplasty with right gold weight placement shortly after surgery for right-sided facial paralysis House-Brackmann VI/VI. After she failed to demonstrate gains in facial function 9 months following surgery, she underwent right parotidectomy with facial nerve exposure, facial nerve decompression lateral to the geniculate, and a split hypoglossal to facial nerve anastomosis. At the time of the pictures she was ~ 16 months out from her 12–7 anastomosis and had not undergone any additional surgeries, physical therapy, or botulinum toxin injection. She would be awarded a total of 3 points corresponding to grade C function: 2 points for complete eye closure, 0 points for midface movement, and 1 point for minimal synkinesis.

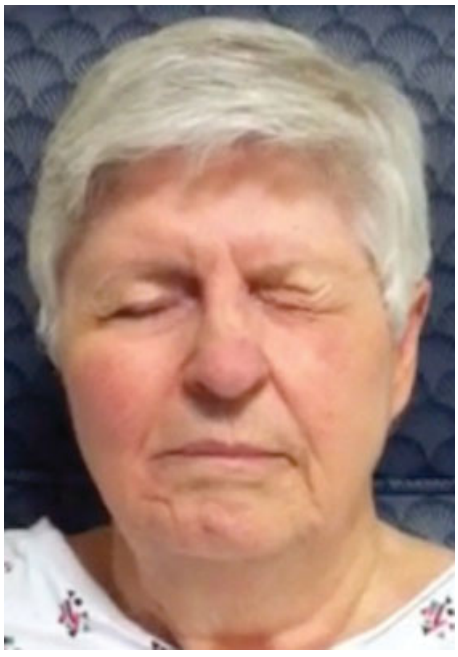

Fig. 8 Patient 3 demonstrating complete eye closure. She would be awarded 2 points.

Discussion

All three patients in this study underwent operative procedures that required resection of the facial nerve and adjacent musculature or developed long-standing facial nerve paralysis following a surgical procedure. Each patient underwent facial reanimation techniques and could not have had their facial recovery assessed with the grading scales currently available in the literature. Each was graded based on three aspects: the periorbital region, midface region, and the presence of synkinesis. Each aspect has a point range with 0 indicating the worst level of functioning and 2 demonstrating the best level of functioning. Summing the point values from each area of evaluation yields a point total that corresponded to a letter grade of functioning. The usefulness of the presented grading scales was demonstrated in evaluating three patients who underwent various static and mimetic facial reanimation procedures. The ideal facial recovery grading scale for patients who have undergone static and mimetic facial reanimation should have several characteristics. It should be applicable to this unique patient population, easy to use in a busy clinical setting, accurately describe a patient's facial recovery, and demonstrate interobserver reliability. The proposed facial recovery grading scale is applicable to this population, easy to use, and allows clinicians to accurately describe facial recovery. A future area of investigation would be a study to determine interobserver reliability utilizing this

grading scale. Patients who lack an intact facial nerve should not have their facial function described in relation to the House-Brackmann scale because it was not designed for use in this patient population.

Conclusion

The proposed facial nerve grading scale provides a means of grading facial recovery for a unique population of patients. The facial nerve grading scales most frequently cited in the literature rely on an intact facial nerve. The grading scale proposed in this article allows for a concise method for regional evaluation of patient facial recovery in patients who have undergone both static and mimetic facial reanimation.

References

1 Kanerva M, Poussa T, Pitkäranta A. Sunnybrook and House-Brackmann Facial Grading Systems: intrarater repeatability and interrater agreement. Otolaryngol Head Neck Surg 2006;135(6):865–871
2 Ross BG, Fradet G, Nedzelski JM. Development of a sensitive clinical facial grading system. Otolaryngol Head Neck Surg 1996;114(3):380–386
3 Yanagihara N. Grading of facial palsy. In Fisch U, ed. Facial Nerve Surgery. Amstelveen. The Netherlands: Kugler Medical Publications; 1977:533–535
4 Murty GE, Diver JP, Kelly PJ, O'Donoghue GM, Bradley PJ. The Nottingham system: objective assessment of facial nerve function in the clinic. Otolaryngol Head Neck Surg 1994;110(2):156–161
5 Coulson SE, Crozson GR. Assessing physiotherapy rehabilitation outcomes following facial nerve paralysis. Aust J Otolaryngol 1995;2(1):20–24
6 Vrabec JT, Backous DD, Djalilian HR, et al; Facial Nerve Disorders Committee. Facial Nerve Grading System 2.0. Otolaryngol Head Neck Surg 2009;140(4):445–450
7 House JW, Brackmann DE. Facial nerve grading system. Otolaryngol Head Neck Surg 1985;93(2):146–147
8 Sardesai MG, Moe K. Recent progress in facial paralysis: advances and obstacles. Curr Opin Otolaryngol Head Neck Surg 2010;18(4):266–271
9 Hadlock T. Facial paralysis: research and future directions. Facial Plast Surg 2008;24(2):260–267