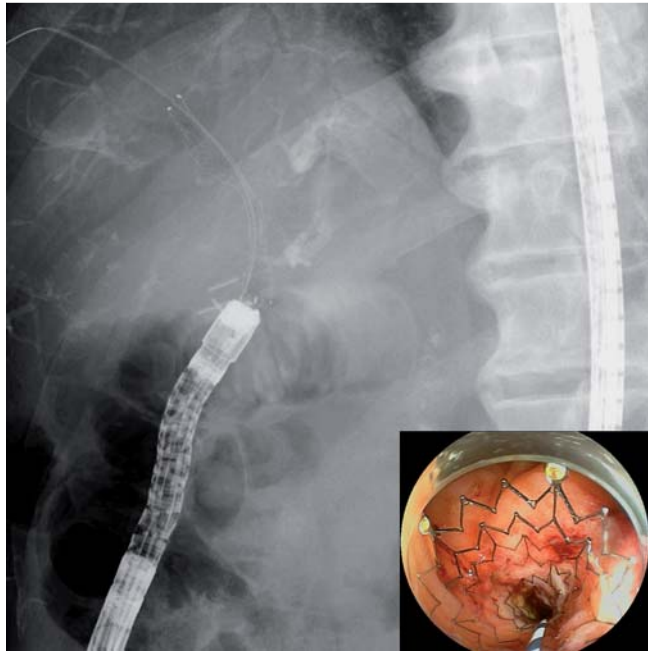
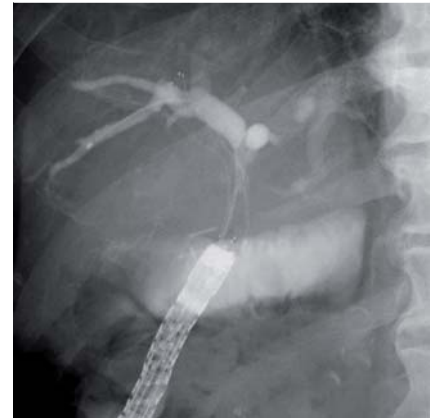


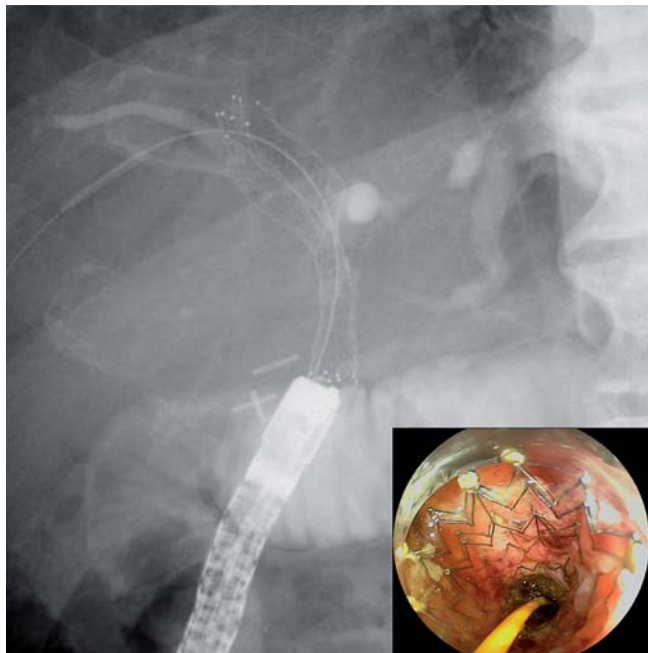
## Multiple metal stenting using a double-balloon endoscope for malignant biliary obstruction in a patient with hepaticojejunostomy



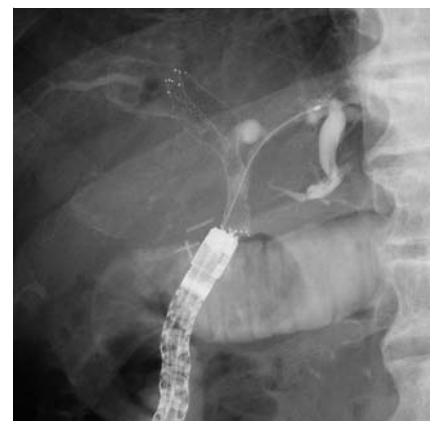**Fig. 1** The first uncovered metal stent was deployed into the anterior branch of the right hepatic duct.



**Fig. 2** The catheter was advanced into the posterior branch of the right hepatic duct through the first stent mesh.



**Fig. 3** The second uncovered metal stent (UMS) was deployed through the mesh of the initial UMS.



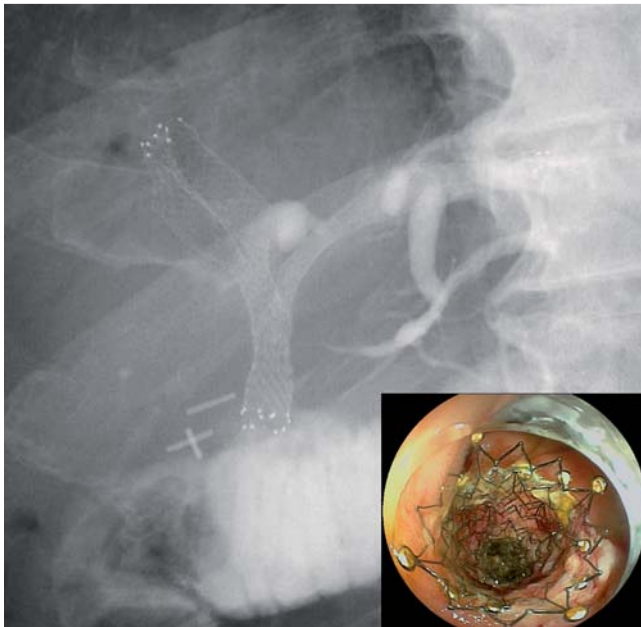
**Fig. 4** The catheter was passed into the lateral branch of the left hepatic duct through the overlapping stent mesh.

Endoscopic management of malignant biliary obstruction following hepaticojejunostomy can be challenging. With the advent of the short double-balloon endoscope (DBE), therapeutic biliary interventions are possible in surgically altered anatomy [1,2]. Additionally, a novel uncovered metal stent (UMS) has been devel-

oped with a 200-cm-long, 6-Fr delivery system (Zilver 635; Cook Medical, Winston-Salem, North Carolina, United States) to enable metal stent placement using a short DBE [3]. We present a successful case of multiple metal stenting using a short DBE and UMS for malignant biliary obstruction after hepaticojejunostomy.

A 75-year-old man with extrahepatic bile duct cancer underwent pancreaticoduodenectomy with Roux-en-Y reconstruction. He developed cholangitis 11 months postoperatively as a result of liver metastasis in the medial left lobe segment. Endoscopic retrograde cholangiopancreatography (ERCP) was performed to place two plastic stents using a short DBE (EI-530B; Fujifilm Corp., Tokyo, Japan). However, rapid tumor growth resulted in recurrent episodes of cholangitis. Therefore, the decision was made to insert multiple metal stents via another ERCP using the short DBE.

The plastic stents were removed, and the hepaticojejunostomy anastomosis was



**Fig. 5** The third uncovered metal stent (UMS) was deployed through the mesh of the initial and second UMSs.

cannulated. A 0.025-inch stiff guidewire (Revowave; Piolax Medical Devices, Yokohama, Japan) was placed into the anterior right hepatic duct branch, and the UMS was inserted using the 6-Fr delivery system (Fig. 1). A seeking guidewire (Radifocus; Terumo, Tokyo, Japan) sought the posterior right hepatic duct branch through the stent mesh, and the catheter was advanced through the stent mesh (Fig. 2). The guidewire was exchanged for a stiff guidewire. The second UMS was deployed (Fig. 3). Subsequently, a seeking guidewire sought the lateral left hepatic duct branch through the overlapping stent mesh. The catheter could then be passed through the overlapping stent mesh (Fig. 4). The guidewire was exchanged. Finally, the third UMS was

smoothly deployed into the lateral left hepatic duct using a stent-in-stent method (Fig. 5).

Endoscopy\_UCTN\_Code\_TTT\_1AR\_2AZ

**Competing interests:** None

**Hirofumi Kogure, Atsuo Yamada, Hiroyuki Isayama, Tomotaka Saito, Tsuyoshi Hamada, Takashi Sasaki, Natsuyo Yamamoto, Yousuke Nakai, Kenji Hirano, Minoru Tada, Kazuhiko Koike**

Department of Gastroenterology, Graduate School of Medicine, University of Tokyo, Tokyo, Japan

## References

- 1 Shimatani M, Matsushita M, Takaoka M et al. Effective "short" double-balloon enteroscopy for diagnostic and therapeutic ERCP in patients with altered gastrointestinal anatomy: a large case series. *Endoscopy* 2009; 41: 849–854
- 2 Tsujino T, Yamada A, Isayama H et al. Experiences of biliary interventions using short double-balloon enteroscopy in patients with Roux-en-Y anastomosis or hepaticojejunostomy. *Dig Endosc* 2010; 22: 211–216
- 3 Chennat J, Waxman I. Initial performance profile of a new 6F self-expanding metal stent for palliation of malignant hilar biliary obstruction. *Gastrointest Endosc* 2010; 72: 632–636

## Bibliography

**DOI** <http://dx.doi.org/10.1055/s-0034-1377541>  
*Endoscopy* 2014; 46: E472–E473  
 © Georg Thieme Verlag KG  
 Stuttgart · New York  
 ISSN 0013-726X

## Corresponding author

**Hirofumi Kogure, MD**  
 Department of Gastroenterology  
 Graduate School of Medicine  
 University of Tokyo  
 7-3-1 Hongo, Bunkyo-ku  
 Tokyo 113-8655  
 Japan  
 Fax: +81-3-38140021  
[kogureh-tky@umin.ac.jp](mailto:kogureh-tky@umin.ac.jp)