Endoscopic creation of an omental patch with an over-the-scope clip system after endoscopic excavation and resection of a large gastrointestinal stromal tumor of the stomach

A 75-year-old woman with a history of complex aortic aneurysm repair, rheumatoid arthritis, hypertension, atherosclerosis, and atrial fibrillation was found to have a 35-mm gastrointestinal stromal tumor (GIST) of the gastric fundus (**Fig. 1 a**). Endoscopic ultrasound revealed the GIST to be originating from the muscularis propria.

The patient preferred an endoscopic excision. The endoluminal resection was carried out with an endoscopic submucosal dissection (ESD) technique. A mixture of indigo carmine and saline was injected into the base of the lesion. After an incision had been created with the tip of a snare, an insulation-tipped knife (Olympus America, Melville, New York, USA) was used to cut the mucosa and submucosa circumferentially around the tumor (**Fig. 1 b**). With careful dissection, the entire round, muscular tumor was exposed, completely excavated from its base, and enucleated (**Fig. 1 c**). However, during the final steps of the procedure, a perforation was noticed at the side of the tumor base. An 11/6 t over-the-scope clip (OTSC) system (Ovesco Endoscopy, Tübingen, Germany) was loaded onto the scope and directed toward the perforation site, which was about 4 to 5 mm in diameter. Despite the difficult retroflexed position, we were able to direct the OTSC system toward the defect, fully visualize the perforation, carefully suction an omental patch into the cap of the OTSC system, and include all the edges of the perforation site within the cap before successfully deploying the clip (**Fig. 1 d**). A second clip was deployed next to the first one to completely close the muscular defect. Water-soluble contrast was then administered through the scope to confirm complete closure of the perforation (**Fig. 1 e, f**). The patient was kept in the hospital, and antibiotics were administered. A radiographic examination 24 hours later did not reveal any leak, and the patient's diet was gradually advanced over the next 2 days.

ESD and excavation techniques have now become accepted therapies for the removal or palliation of early cancers and submucosal tumors. However, they occasionally result in perforation [1]. Although in

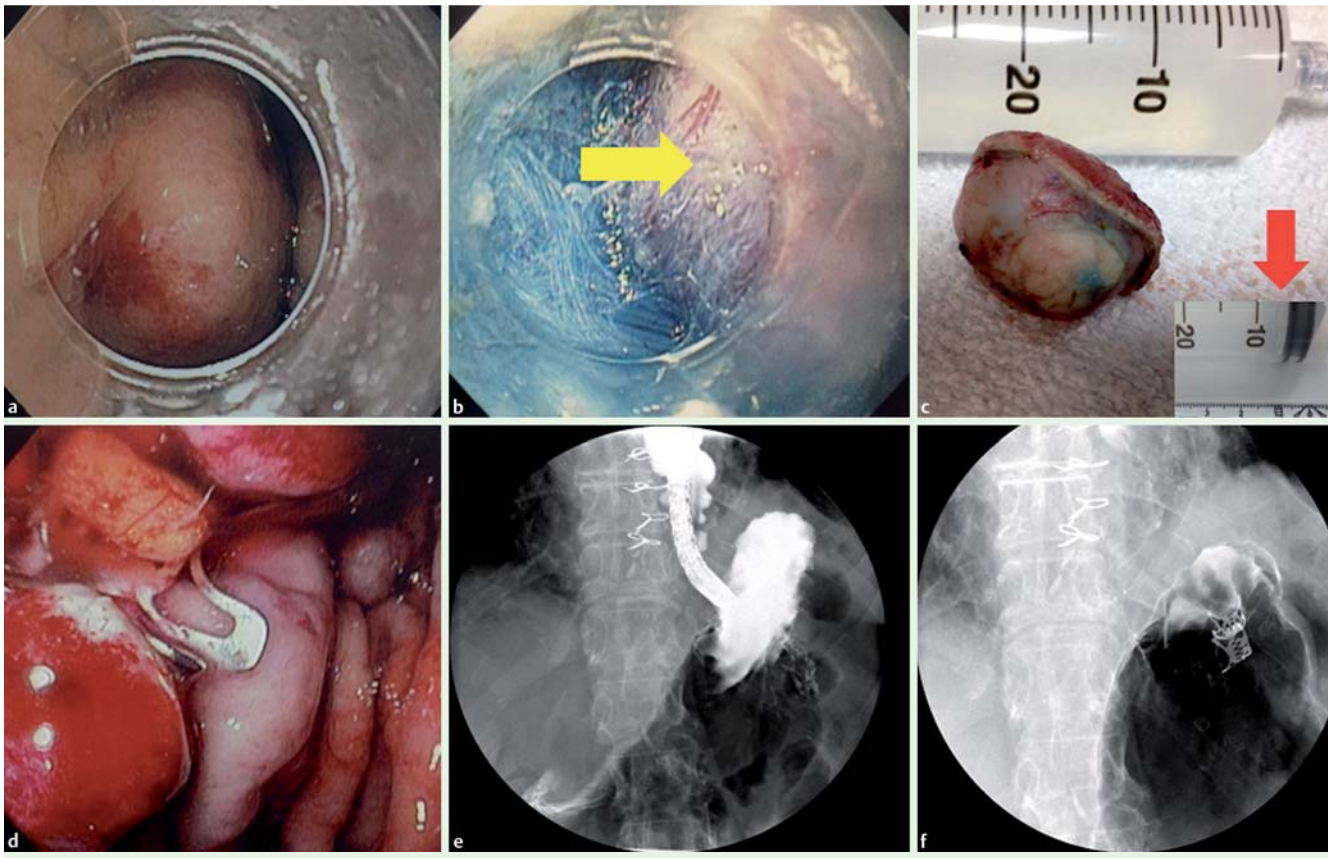

Fig. 1 Creating an endoscopic omental patch with an over-the-scope clip (OTSC) system. **a** A large gastrointestinal stromal tumor was located in the gastric fundus. **b** Endoscopic dissection with an insulation-tipped knife was used to free the tumor (yellow arrow). **c** The specimen was resected in toto. The red arrow points to a ruler indicating the size of the lesion (35 mm). Each interval of 10 marked on the 60-mL syringe is equivalent to 18 mm (photo inset, red arrow). **d** The OTSC system was used to close a perforation with omentum ("endoscopic omental patch"). **e** Water-soluble contrast was administered to confirm closure of the full-thickness wall defect. **f** The two clips are clearly visible in this aircontrast radiographic study.

the past perforation was always considered a catastrophe, full-thickness wall defects can nowadays be completely closed with the use of endoscopic devices such as clips, Endoloops, suturing devices, and OTSC systems [2,3]. Whereas closure of a defect used to focus mainly on apposition of the perforation edges, we believe that the creation of an endoscopic omental patch may add strength and improve sealing of the perforation site. Indeed, surgical omental patches are a classic approach to improving the sealing and healing of perforated gastroduodenal ulcers.

Endoscopy_UCTN_Code_TTT_1AO_2AI

Competing interests: None

Klaus Mönkemüller, Shabnam Sarker, K. R. Kyanam Kabir Baig

Basil I. Hirschowitz Endoscopic Center of Excellence, Division of Gastroenterology and Hepatology, University of Alabama at Birmingham, Alabama, USA

References

1 *Zhang S, Chao GQ, Li M* et al. Endoscopic submucosal dissection for treatment of gastric submucosal tumors originating from the muscularis propria layer. Dig Dis Sci 2013; 58: 1710 – 1716

2 *Kantsevoy SV, Bitner M, Mitrakov AA* et al. Endoscopic suturing closure of large mucosal defects after endoscopic submucosal dissection is technically feasible, fast, and eliminates the need for hospitalization (with videos). Gastrointest Endosc 2014; 79: 503 – 507

3 *Mönkemüller K, Peter S, Toshniwal J* et al. Multipurpose use of the 'bear claw' (over-the-scope-clip system) to treat endoluminal gastrointestinal disorders. Dig Endosc 2014; 26: 350 – 357

Bibliography

DOI http://dx.doi.org/10.1055/s-0034-1377495
Endoscopy 2014; 46: E451–E452

ISSN 0013-726X

Corresponding author

Klaus Mönkemüller, MD, PhD
Basil I. Hirschowitz Endoscopic Center of Excellence
University of Alabama at Birmingham
Endoscopy Unit, JT 664
619 19th Street South
Birmingham, AL 35249
USA
Fax: +1-205-934-1537
moenkemueller@yahoo.com