Idiopathic esophageal ulceration is nearly forgotten in an era of controlled human immunodeficiency virus

Obstruction due to esophageal ulceration is usually caused by gastroesophageal reflux disease, malignancy, or eosinophilic esophagitis. In patients infected with the human immunodeficiency virus (HIV), another specific cause of obstruction should not to be forgotten.

A 43-year-old HIV-infected man with low CD4 cell count and high viral load was admitted with odynophagia and dysphagia. Esophagogastroduodenoscopy showed severe esophagitis with strictures (**Fig. 1** and **Fig. 2**), and normal histology on repeat endoscopy. Multiple dilations and subsequent high-dose proton pump inhibitors and ganciclovir did not improve the symptoms. Serology for herpes simplex virus and cytomegalovirus was negative. Meanwhile, viral loads and CD4 cell count improved, as a result of adjustment to antiretroviral therapy.

Finally, a gastroenterologist who was experienced in HIV problems suggested the diagnosis of HIV-associated idiopathic esophageal ulceration (IEU). The patient was treated with liquid steroids (beclomethasone), which resulted in clinical and endoscopic improvement (**Fig. 3**).

In the early days of the acquired immunodeficiency syndrome epidemic, gastroenterologists frequently encountered complications. IEU was typically seen in patients with uncontrolled HIV, as in the current patient. With increasingly well-monitored HIV treatment, IEU has become rare. Current gastroenterologists and internists are less familiar with diagnosing IEU, which should also be considered in other immunocompromised patients (e.g. stem cell or renal transplantation) [1, 2]. In addition, fragmentation of care may further delay proper treatment.

In the 1990s, one group reported an IEU prevalence of 15% in HIV patients [3]. Typical symptoms were chest pain and odynophagia; dysphagia was less common. Histology is mandatory to exclude malignancy and infection.

The treatment of choice is steroids, with response in 90% of patients [4–6]. With thalidomide, a success rate of 71% was reported [7]. The current patient was successfully treated with orally administered enema steroids (beclomethasone). The influence of better viral control with interventions other than steroids is unknown. No data exist comparing the latter. Budesonide inhalers, prescribed for eosinophilic esophagitis, might be new additions to the armamentarium. In summary, early recognition of IEU is warranted in order to start treatment.

Endoscopy_UCTN_Code_CCL_1AB_2AC_3AH

Competing interests: None

Noor Bekkali[1,2], Guido E. L. van den Berk[3], Paul Drillenburg[4], Dirk J. van Leeuwen[1,5]

[1] Department of Gastroenterology, Onze Lieve Vrouwe Gasthuis, Amsterdam, The Netherlands
[2] Academic Medical Center of Amsterdam, Amsterdam, The Netherlands
[3] Department of Internal Medicine (Infectious Diseases), Onze Lieve Vrouwe Gasthuis, Amsterdam, The Netherlands
[4] Department of Pathology, Onze Lieve Vrouwe Gasthuis, Amsterdam, The Netherlands
[5] Dartmouth Medical School, Hanover, New Hampshire, United States

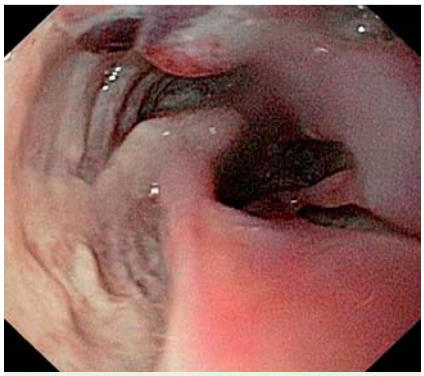

Fig. 1 Ulcerated esophagus prior to treatment.

Fig. 2 Proximal esophageal ulcer.

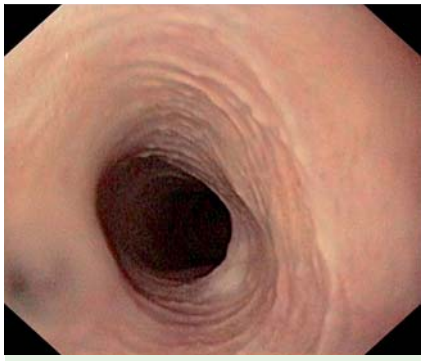

Fig. 3 Endoscopically normal esophagus after treatment.

This document was downloaded for personal use only. Unauthorized distribution is strictly prohibited.

References

1 *Farrell JJ*, *Cosimi AB*, *Chung RT*. Idiopathic giant esophageal ulcers in a renal transplant patient responsive to steroid therapy. Transplantation 2000; 70: 230–232
2 *Dang S*, *Atiq M*, *Krishna S* et al. Idiopathic esophageal ulcers after autologous hemopoetic stem cell transplant: possible role of IgA levels. Ann Hematol 2008; 87: 1031–1032
3 *Wilcox CM*, *Schwartz DA*. Endoscopic characterization of idiopathic esophageal ulceration associated with human immunodeficiency virus infection. J Clin Gastroenterol 1993; 16: 251–256
4 *Wilcox CM*, *Schwartz DA*. Comparison of two corticosteroid regimens for the treatment of HIV associated idiopathic oesophageal ulcer. Am J Gastroenterol 1994; 89: 2163–2167
5 *Wilcox CM*, *Schwartz DA*. Esophageal ulceration in human immunodeficiency virus infection. Causes, response to therapy, and long term outcome. Ann Intern Med 1995; 123: 143–149
6 *Kotler DP*, *Reka S*, *Orenstein JM* et al. Chronic idiopathic esophageal ulceration in the acquired immunodeficiency syndrome. Characterization and treatment with corticosteroids. J Clin Gastroenterol 1992; 15: 284–290
7 *Jacobsen JM*, *Spritzler J*, *Fox L* et al. Thalidomide for the treatment of esophageal aphthous ulcers in patients with human immunodeficiency virus infection. National Institute of Allergy and Infectious Disease AIDS Clinical Trials Group. J Infect Dis 1999; 180: 61–67

Bibliography

DOI http://dx.doi.org/10.1055/s-0034-1377432
Endoscopy 2014; 46: E429–E430

© Georg Thieme Verlag KG
Stuttgart · New York

ISSN 0013-726X

Corresponding author

Noor Bekkali, MD, PhD
Academic Medical Center of Amsterdam
Meibergdreef 9
1105 AZ Amsterdam
The Netherlands
Fax: +31-20-5993818
n.bekkali@amc.nl

Correction

Bekkali N, van den Berk GEL, Drillenburg P, van Leeuwen DJ. Idiopathic esophageal ulceration is nearly forgotten in an era of controlled human immunodeficiency virus. Endoscopy 2014; 46 CTL: E429–E430. DOI: 10.1055/s-0034-1377432. Epub 2014 Oct 14

The author's name Guido L. E. van den Berk was corrected to Guido E. L. van den Berk.

This document was downloaded for personal use only. Unauthorized distribution is strictly prohibited.