An unpredictable complication during percutaneous endoscopic tube placement: esophageal perforation

A percutaneous endoscopic gastrostomy (PEG) was performed to provide an enteral feeding route. Major and minor complications related to this procedure include, aspiration, wound infections, necrotizing fasciitis, peritonitis, abscess, peristomal leakage, pneumoperitoneum, ileus, portomesenteric venous gas, colon injury, gastrocolocutaneous fistulae, abdominal wall bleeding, intra-abdominal bleeding, gastric outlet obstruction, inadvertent gastrostomy tube removal, spleen trauma, clogged PEG tube, tumor implantation at PEG site, and buried bumper syndrome [1,2].

An 88-year-old woman with Alzheimer's disease required PEG tube placement as an alternative feeding route. The procedure was performed using the pull-through technique (Flexiflo kit; Abbott, Sligo, Ireland). On endoscopy, tertiary contractions occurred in the esophagus. The procedure was uneventful until moments before the insertion of the tube into the esophagus through the mouth. A moderate resistance was felt while pulling the tube wire. Inspection of the tube after removal revealed deformation of its tip (**Fig. 1**). A new tube was inserted and then the upper esophagus was checked endoscopically. Severe lacerations and minimal bleeding were observed in the upper part of the esophagus (**Fig. 2**).

Shortly thereafter, the patient presented dyspnea, followed by edema and crepitation in the neck. Thoracic computed tomography indicated the presence of air in the mediastinum (**Fig. 3**). The patient

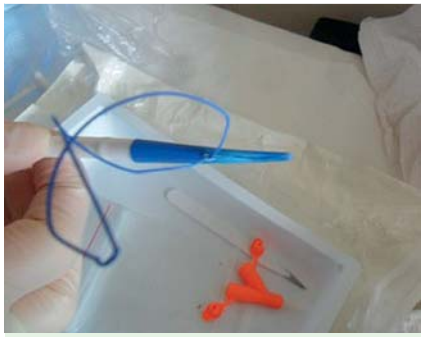

Fig. 1 The deformation of the tube tip.

Fig. 2 Minimal bleeding and laceration in the esophagus.

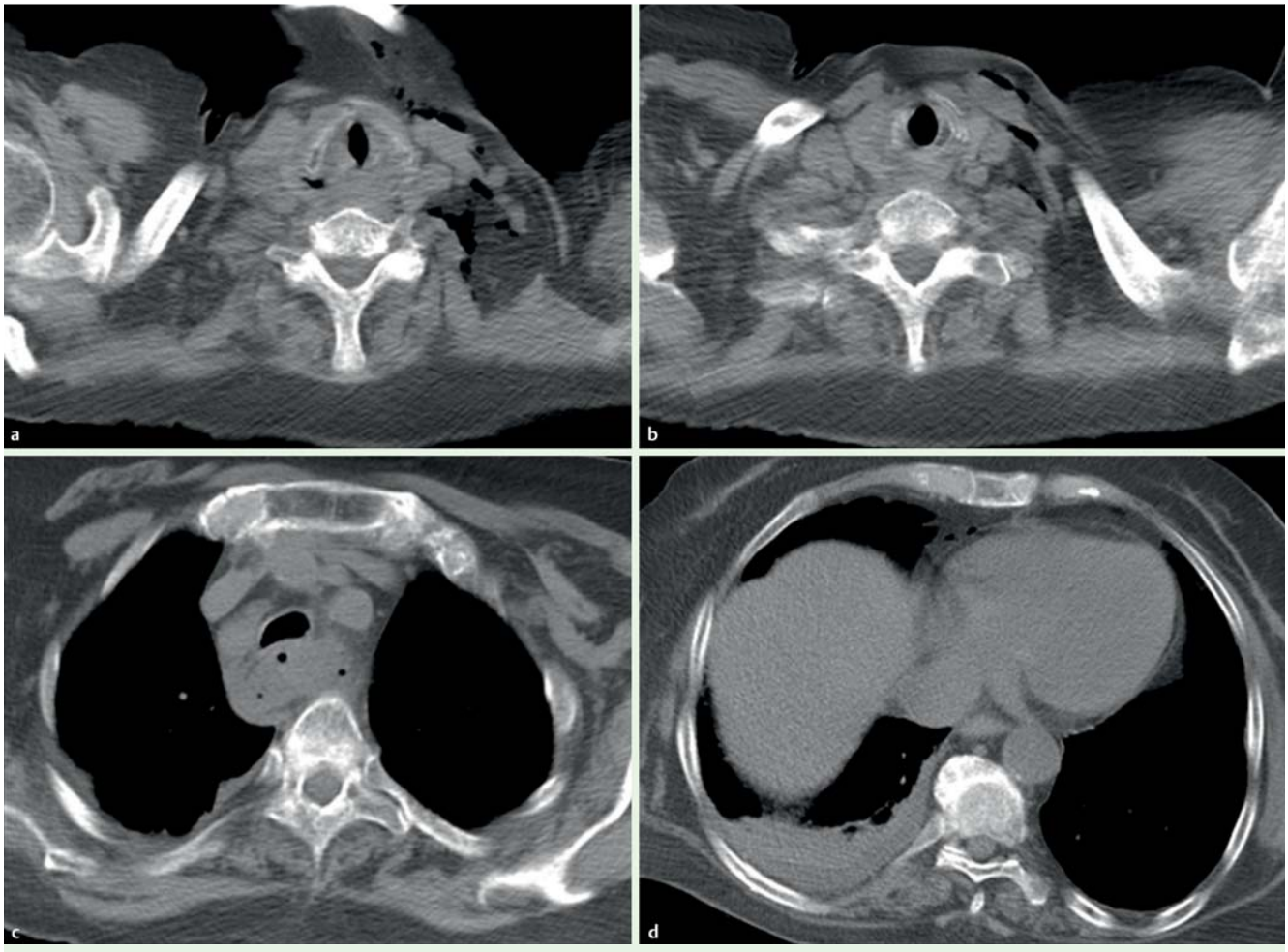

Fig. 3 Axial noncontrast-enhanced computed tomography images after the procedure showed free air bubbles in the left cervical region (**a, b**), and the periesophageal (**c**) and right paracardiac (**d**) spaces.

presented mild peripheral cyanosis, tachycardia, tachypnea, and a subfebrile rise in body temperature. She was cared for in the intensive care facility.

A few hours later, she reported feeling better. Vital signs returned to normal. Feeding via the PEG tube was initiated 2 days later, and the tube functioned properly. The patient was hospitalized for 32 days after the procedure.

This report describes the occurrence of an esophageal perforation during the insertion of a PEG tube. As this complication was detected early, conservative treatment was sufficient for its successful resolution, and the patient healed satisfactorily.

Endoscopy_UCTN_Code_CPL_1AH_2AI

Competing interests: None

Ahmet Faruk Agan

Department of Gastroenterology, Medical School, Medipol University, Istanbul, Turkey

References

1 *Jarnagin WR*, *Duh QY*, *Mulvihill SJ* et al. The efficacy and limitations of percutaneous endoscopic gastrostomy. Arch Surg 1992; 127: 261 – 264

2 *Rimon E*. The safety and feasibility of percutaneous endoscopic gastrostomy placement by a single physician. Endoscopy 2001; 33: 241 – 244

Bibliography

DOI http://dx.doi.org/10.1055/s-0034-1377403

Endoscopy 2014; 46: E413–E414

ISSN 0013-726X

Corresponding author

Ahmet Faruk Agan, MD

Department of Gastroenterology
Medical School
Medipol University
Haydrapasa-Harem Yolu
Kadikoy
34718 Istanbul
Turkey
Fax: +90-216-5454511
afagan@medipol.edu.tr