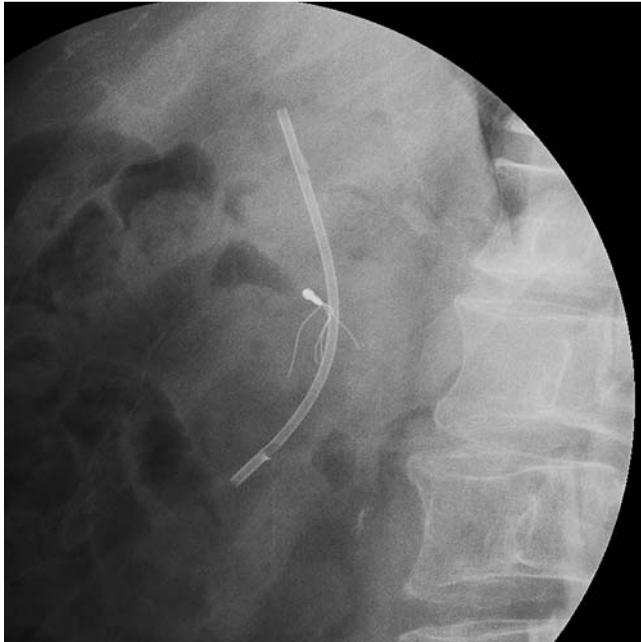
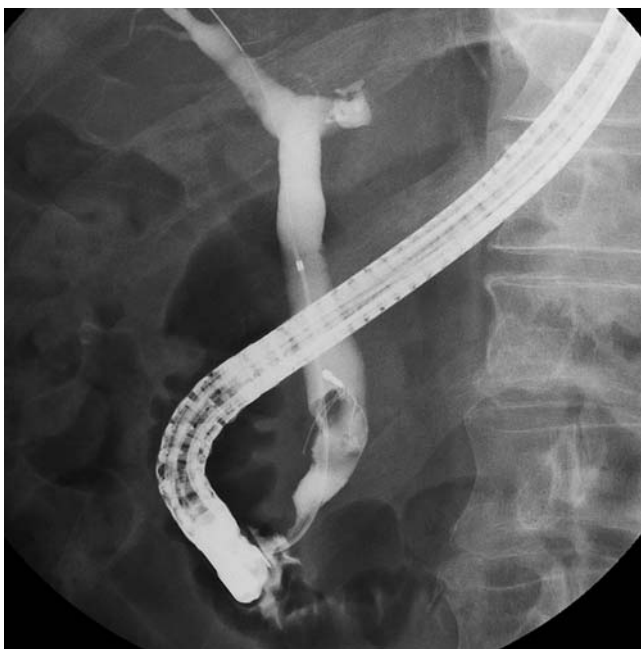
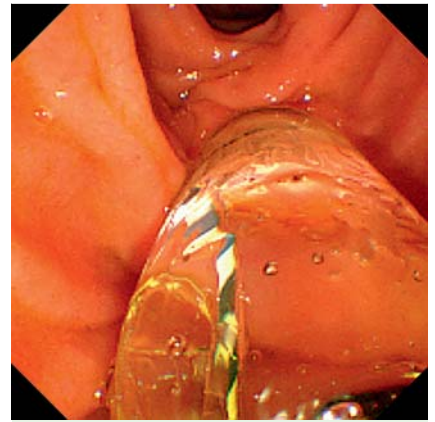
## Safe recovery of a fully fractured basket in the bile duct using endoscopic papillary large balloon dilation



**Fig. 1** Radiographic image showing the fractured basket beside a biliary duct endoprosthesis.



**Fig. 2** Image during endoscopic retrograde cholangiography showing bile duct stones within the fractured basket.



**Fig. 3** Duodenoscopy showing the dilation of the papilla by inflation of a large balloon.

Successful recovery from the bile duct of a fully fractured basket using endoscopic techniques.

A 74-year-old man underwent endoscopic mechanical lithotripsy for bile duct stones following endoscopic sphincterotomy at another hospital. The bile duct stones were partially crushed; however, all the wires of the basket section were fractured and the proximal part remained in the bile duct. He was referred to our hospital for recovery of the fractured basket after placement of a biliary duct endoprosthesis (▶ Fig. 1).

Endoscopic retrograde cholangiography was performed using a side-viewing video duodenoscope (TJF-260V; Olympus Medical Systems, Tokyo, Japan) and revealed stones within the fractured basket (▶ Fig. 2). Therefore, we performed endoscopic papillary large-balloon dilation (EPLBD) to prevent damage to the peri-papillary bile duct by the tips of the wires (▶ Fig. 3; ▶ Video 1). EPLBD was performed using a CRE wire-guided biliary balloon dilation catheter (Boston Scientific Japan, Tokyo, Japan) with a maximum diameter of 18 mm. Before proceeding, we confirmed that oozing of blood from the papilla due to the balloon dilation had stopped spontaneously.

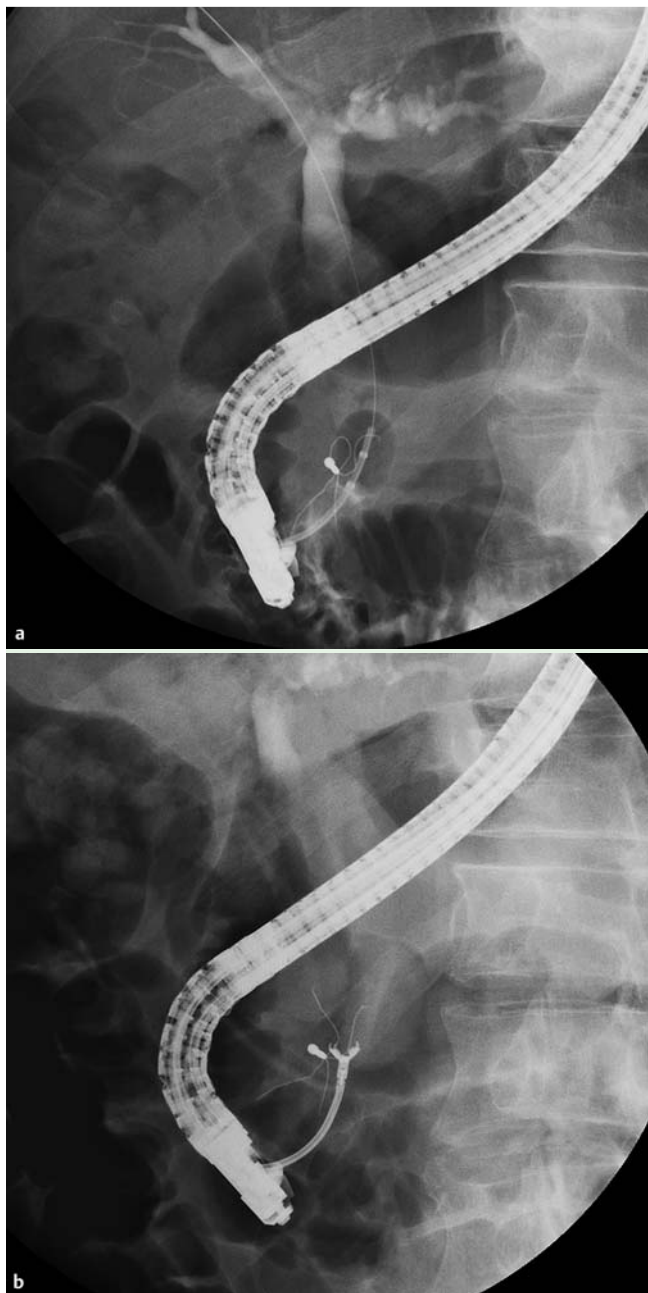
An extraction balloon catheter (EXP71820P; Zeon Medical, Tokyo, Japan) was used next to remove the bile duct stones. The fractured basket was then inverted and moved closer to the papilla

Traction wires are occasionally fractured while endoscopic mechanical lithotripsy is being performed for bile duct stones. Various methods have been used to crush the bile stones during the rescue of an impacted basket including a transoral endotripter [1], laser or electrohydraulic lithotripsy under cholangioscopy guidance [2,

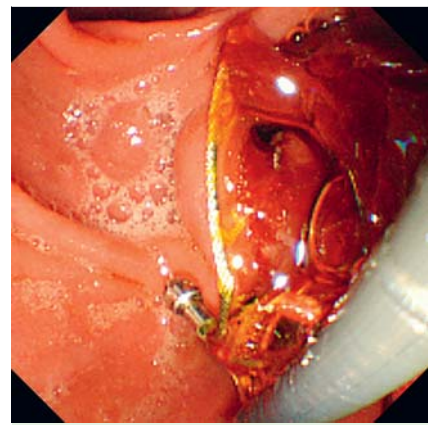
3], or extracorporeal shock wave lithotripsy [4]. In most cases, fractured wires are recovered by pulling their distal ends outside of the bile duct after the impacted basket has been released. However, if all the wires have fractured in the proximal portion of the bile duct, what then is a suitable method? We describe the suc-

### Video 1

Endoscopic papillary large-balloon dilation (EPLBD) being performed to safely recover the fractured basket.



**Fig. 4** Images during cholangiography showing: **a** the bile duct stone and the fractured basket being moved closer to the papilla with an extraction balloon catheter; **b** alligator forceps in the bile duct grasping the fractured basket.



**Fig. 5** Duodenoscopy showing the fractured basket after its recovery from the bile duct.

(▶ **Fig. 4a**). Finally, we used alligator forceps (FG-47L-1; Olympus Medical Systems) to recover the fractured basket (▶ **Fig. 4b** and ▶ **Fig. 5**; ▶ **Video 2**). No procedure-related complications were observed during endoscopy. Although reports have described the management of basket impaction via EPLBD [5], the recovery of a fully fractured basket is rare.

#### Video 2

The bile duct stones are removed by an extraction balloon catheter and the fractured basket is moved closer to the papilla. Finally, alligator forceps are used to recover the basket.

Endoscopy\_UCTN\_Code\_CPL\_1AK\_2AC

**Competing interests:** None

**Takao Nishikawa, Toshio Tsuyuguchi, Yuji Sakai, Osamu Yokosuka**

Department of Gastroenterology and Nephrology, Graduate School of Medicine, Chiba University, Chiba, Japan

#### References

- 1 Kim WH, Kwon CI, Han JH. Rescue lithotripsy to treat basket impaction. *Endoscopy* 2012; 44 (Suppl. 02): E209–E210
- 2 Neuhaus H, Hoffmann W, Classen M. Endoscopic laser lithotripsy with an automatic stone recognition system for basket impaction in the common bile duct. *Endoscopy* 1992; 24: 596–599
- 3 Tsuchiya T, Itoi T, Sofuni A et al. Rescue of basket-impacted stone by use of electrohydraulic lithotripsy under cholangioscopy. *Gastrointest Endosc* 2014; 79: 376
- 4 Sauter G, Sackmann M, Holl J et al. Dormia baskets impacted in the bile duct: release by extracorporeal shock-wave lithotripsy. *Endoscopy* 1995; 27: 384–387
- 5 Katsinelos P, Fasoulas K, Beltsis A et al. Large-balloon dilation of the biliary orifice for the management of basket impaction: a case series of 6 patients. *Gastrointest Endosc* 2011; 73: 1298–1301

#### Bibliography

**DOI** <http://dx.doi.org/10.1055/s-0034-1377355>  
*Endoscopy* 2014; 46: E365–E366  
 © Georg Thieme Verlag KG  
 Stuttgart · New York  
 ISSN 0013-726X

#### Corresponding author

**Toshio Tsuyuguchi, MD, PhD**  
 Department of Gastroenterology and Nephrology  
 Graduate School of Medicine, Chiba University  
 1-8-1 Inohana, Chuo-ku  
 Chiba 260-8670  
 Japan  
 Fax: +81-43-2262088  
 tsuyuguchi@faculty.chiba-u.jp