

# Spigelian Hernia in a 14-Year-Old Girl: A Case Report and Review of the Literature

Claudio Spinelli<sup>1</sup> Silvia Strambi<sup>1</sup> Valentina Pucci<sup>1</sup> Josephine Liserre<sup>1</sup> Giacomo Spinelli<sup>2</sup>  
Carlo Palombo<sup>2</sup>

<sup>1</sup>Department of Pathology Surgical, Clinical, Molecular and of Critical Area, Chair of Pediatric Surgery, University of Pisa, Pisa, Italy

<sup>2</sup>Department of Pathology Surgical, Clinical, Molecular and of Critical Area, Intensive Care Unit IV, University of Pisa, Pisa, Italy

**Address for correspondence** Prof. Claudio Spinelli, Department of Pathology Surgical, Clinical, Molecular and of Critical Area, Chair of Pediatric Surgery, University of Pisa, via Paradisa Pisa 56124, Italy (e-mail: c.spinelli@dc.med.unipi.it).

Eur J Pediatr Surg Rep 2014;2:58–62.

## Abstract

Spigelian hernia (SH) is a surgical rarity in children, which occurs through slit-like defects in the anterior abdominal wall adjacent to the semilunar line, the convexity lateral line which joins the nine ribs to the pubic tubercle and signs the limit between the muscular and aponeurotic portion of transversus abdominis muscle. As there are no specific symptoms and signs, the diagnosis is difficult, especially in children. We report a case of SH that comes to our observation: a 14-year-old girl presented recurrent abdominal pain associated to intermittent palpable mass in the paraumbilical region. Starting from our case report, we review the literature of pediatric SH from 2000 to 2013 and we describe the anatomy, etiology, clinical presentation, instrumental diagnosis, and surgical technique of pediatric SH.

## Keywords

- ▶ abdominal pain
- ▶ children
- ▶ hernia sac
- ▶ spigelian hernia

## Introduction

Spigelian hernia (SH) is a ventral hernia that occurs through slit-like defects in the anterior abdominal wall adjacent to the semilunar line. Adriaan van der Spiegel is credited as the first to describe the semilunar line in 1645. However, in 1764 Klinckosch<sup>1</sup> described a spontaneous lateral ventral hernia specifically located in the semilunar line. In 1935, Scopinaro<sup>2</sup> was the first to report a lateral ventral hernia in a pediatric patient.

SHs are rare in adults and exceedingly rare in children. Only 37 cases have been reported in the pediatric age group in a review of the literature from 1935 to 2000.<sup>3</sup> In children, SHs range is from newborn to 17 years of age (average, 4.52 years), they are more frequent in males than females (ratio, 3.7:1), and they are more commonly left-sided and may occur bilaterally in 15% of cases.<sup>4–6</sup> In adults, they most occur on the right side, between fourth to seventh decade of life, they are more frequent in women (ratio, 4:3) and are rarely bilateral.<sup>4,7,8</sup> Although adult hernias are considered to be acquired because of trauma or increased intra-abdominal

pressure, the pediatric cases are suspected to be congenital.<sup>4</sup> It is difficult to establish the correct clinical diagnosis because there are no characteristic symptoms<sup>9</sup> and SH may be interparietal with no signs on inspection or palpation.<sup>8,10</sup> Generally, patients present a localized pain that in time becomes diffuse and aggravating. In doubtful cases, ultrasonography (US), computed tomography (CT), and magnetic resonance imaging (MRI) can help to establish the correct diagnosis. The treatment of this hernia is surgery.

We report a case of SH in a 14-year-old girl presented with recurrent abdominal pain. In a review of literature from 2000 to 2013, we collected only 24 cases of SH in children younger than the age of 14 years, for a total of 25 cases including our case. We had considered the following parameters: age, sex, side, associated risk factors, associated anomalies, and content of hernia sac.

## Case Report

A tall, thin 14-year-old girl without other comorbid conditions or previous abdominal wall trauma, was admitted to our

received  
July 18, 2013  
accepted after revision  
December 31, 2013  
published online  
March 12, 2014

DOI <http://dx.doi.org/10.1055/s-0034-1370771>.  
ISSN 2194-7619.

© 2014 Georg Thieme Verlag KG  
Stuttgart · New York

License terms



outpatient surgical with 1 year history of recurrent abdominal pain associated to swelling usually appeared on the right lower abdominal quadrant after strain and spontaneously resolved. Physical examination revealed only tenderness and discomfort to palpation of the abdomen, especially in the right lower quadrant. US of the right midabdomen, using a 7.5 MHz linear transducer, noted a fascial plane defect. With

the suspected diagnosis of SH, the girl underwent open surgery under general anesthesia. A median incision presented a hernia lipoma sticking out from the lateral margin of the abdominal rectus. The orifice diameter was approximately 1.5 cm; it was as a ring like through the fibers of transversus and internal oblique muscles. The hernia sac contained a small part of the greater omentum, which was reduced. The

**Table 1** Reported cases of Spigelian hernia in children

Author	Year	Age	Sex	Side	Comment and associated anomalies	Content of hernia sac
Al-Salem <sup>3</sup>	2000	3 mo 1 wk	M M	Left Left	Left undescended testis Left undescended testis, micrognathia, cleft palate, malformed ears, right clubfoot, deformed left lower limb	Left testis, sigmoid colon Left testis
Losanoff et al <sup>11</sup>	2002	12 y	M	Right	No	Greater omentum
White <sup>12</sup>	2002	1 mo	F	Right	Bilateral inguinal hernias	Small intestine
Levy et al <sup>5</sup>	2003	1 mo 1 mo	M M	Bilateral Bilateral	Bilateral undescended testis Left undescended testis	Right sac: right testis, small bowel left sac: left testis Left testis, small intestine
Raveenthiran <sup>13</sup>	2005	Newborn	M	Right	Right undescended testis, imperforate anus, left inguinal hernia, umbilical hernia	Right testis, bowel
Vaos et al <sup>14</sup>	2005	20 mo	M	Left	Strangulated low Spigelian hernia	Small bowel, greater omentum
Torres de Aguirre et al <sup>15</sup>	2005	26 d 40 d	M M	Right Bilateral	Right undescended testis Bilateral undescended testis	Small intestine, right testis Intestine, testis
Aksu et al <sup>16</sup>	2008	4 y	F	Bilateral	Right short lower extremity, right pes valgus anomaly, absent right fibula, scoliosis, multiple skeletal anomalies	Small bowel
Christianakis et al <sup>17</sup>	2009	6 y	M	Left	Strangulated low Spigelian hernia	Large omentum
Fascetti-Leon et al <sup>18</sup>	2010	Newborn	M	Bilateral	Bilateral undescended testis, scalp aplasia cutis	Bilateral testis, small intestine, vas deferens
Rushfeldt et al <sup>4</sup>	2010	16 d	M	Right	Right undescended testis	Right testis, small intestine
Beasley et al <sup>19</sup>	2010	14 y	M	Left	Traumatic	Fat and vessels
Singal et al <sup>21</sup>	2011	3 y 3 mo	M M	Right Left	Right undescended testis Left undescended testis, glanular hypospadias	Right testis, vas deferens, spermatic vessel Left testis, cord structures
Present report	2013	14 y	F	Right	No	Greater omentum
Bilici et al <sup>22</sup>	2012	6 mo 1 y 2 y 5 y	M M M M	2 Left 2 Right	Ipsilateral undescended testis No gubernaculum or inguinal canal on the side of SH	Ipsilateral testis
Inan et al <sup>23</sup>	2012	20 d	M	Right	Right undescended testis	Right testis
Sudhir et al <sup>24</sup>	2013	9 y	M	Right	Traumatic low SH	Small bowel

Abbreviation: SH, Spigelian hernia.

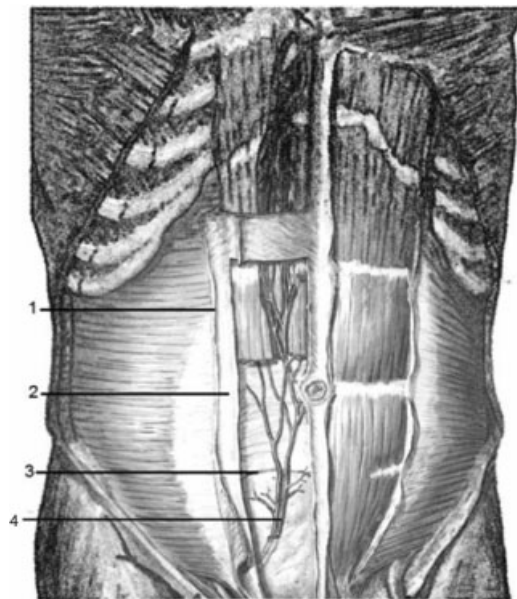
fascia defect was closed with absorbable suture in layers. After the operation, the patient remains free of symptoms and recurrence.

## Review of Literature

A Medline database search (2000–2013) revealed 17 articles for a total of 24 cases of pediatric SH (25 including our case)<sup>3–5,11–24</sup> (→Table 1). There were 22 (88%) males and 3 (12%) females, ratio 7:1. Their ages ranged from newborn to 14 years (average, 3 years). The hernia was situated on the right side in 11 (44%), the left side in 10 (40%), and was bilateral in 4 (16%) cases. In two cases, the hernia was caused by trauma<sup>19,24</sup>; in another case, there was imperforate anus.<sup>13</sup> Two children presented with a strangulated SH.<sup>14,17</sup> Twelve patients had anomalies associated to them: 16 (72.72%) undescended testis (13 ipsilateral and 3 bilateral), 2 (9.09%) inguinal hernia, 1 (4.54%) umbilical hernia, 1 (4.54%) glandular hypospadias, and 2 patients presented other anomalies. The contents of the hernia sac was in most cases the testis, 16 (42.10%); followed by small intestine, 11 (28.94%); omentum, 5 (13.15%); vas deferens, 2 (5.26%); cord structures, 1 (2.63%); fat and vessel, 1 (2.63%); spermatic vessel, 1 (2.63%); and sigmoid colon, 1 (2.63%).

## Discussion

SH protrudes through a congenital or usually acquired defect of the Spigelian fascia, which is the aponeurotic layer between the rectus abdominis muscle medially and the semilunar line laterally.<sup>8</sup> The term “Spigelian hernia” is usually referred to hernias located cranially to the inferior epigastric vessels. Those that cross the strip of Spigelian at the triangle of Hasselbach, caudally and medially to the vessels, are called “low” and are a rare entity in pediatric surgery often misdiagnosed as an inguinal hernia.<sup>10,24</sup> In 90% of cases, these hernias lies in the so-called SH belt, which is a transverse belt lying 6 cm cranial to the interspinal plane.<sup>25</sup> One of the weakest points is the insertion between the semilunar and semicircular line of Douglas. This line marks the caudal end of the posterior lamina of the aponeurotic rectus sheath in the infraumbilical area. In classic SH, the external oblique fascia remains generally intact and the hernial sac is located between the internal oblique muscle and aponeurosis of the transversus muscle (→Fig. 1). The etiology in children is still unclear: a congenital abnormality in the development of the abdominal wall secondary to a structural change of the internal oblique and transversus abdominis muscles, neurovascular openings in the fascia, infiltration of muscles layers with fat and muscle palsy has been hypothesized.<sup>11,18</sup> Most SHs reported in the pediatric age group are spontaneous and idiopathic, although posttraumatic and postoperative SH have been reported.<sup>5,11,19,24</sup> On the basis of the musculoaponeurotic defect etiology, diverse factors that increase intra-abdominal pressure or deteriorate the abdominal wall are considered predisposing factors such as collagen disorders, changes in body weight, aging, chronic pulmonary disease, trauma, previous abdominal surgery, previous or concomi-



**Fig. 1** Anatomy of abdominal wall: (1) Linea semilunaris; (2) Spigelian fascia; (3) Semicircular line; (4) Inferior epigastric vessels.

tant hernias, and imperforate anus.<sup>6,13,16</sup> An association of cryptorchidism, umbilical hernia, inguinal hernia, gastroschisis, omphalocele, meningomyelocele, congenital diaphragmatic hernia, and bladder or cloacal exstrophy have been reported for SH.<sup>3–5,12,13,15,16,18,21–23</sup>

Among male infants with SHs, 75% presented are associated with cryptorchidism and in most of these the undescended testis was found in the hernia sac.<sup>4,7,21–23</sup> There have been many hypotheses on the mechanism of this congenital association. Some authors<sup>4,5,21</sup> report that SH is the primary defect and the undescended testis takes the path of least resistance in the abdominal wall. Raveenthiran<sup>26</sup> instead hypothesized that the ectopic location of the testis is the primary abnormality and leads to the formation of a SH by dragging a peritoneal sac along with it. For all these authors, therefore, SH and undescended testis are in a sequence. Because of the high rate of coexistence of this two anomalies, Bilici et al<sup>22</sup> suggest for a congenital Spigelian–cryptorchidism syndrome, defined by defects in the Spigelian fascia, hernia sac containing the testis and absence of both the gubernaculum and the inguinal canal; on the other side, Mirilas<sup>27</sup> states that this association can be simply accidental: the discussion in literature is still open.

The submission of pediatric SHs is quite uncommon, therefore this often means a delayed diagnosis. They may be asymptomatic or present with no specific clinical symptoms and signs, ranging from pain, swelling, intermittent abdominal pain to an acute abdomen; in addition 20% of SHs in children present with strangulation.<sup>4,5,21</sup> Pain is usually limited to the area where the hernia has occurred; it varies in type, severity and location, and depends upon contents of hernia<sup>28</sup>; the contraction of the abdominal muscles or other maneuvers that increase intra-abdominal pressure, causing or exacerbating the pain, can help toward the correct

diagnosis. The presence of an intermittent palpable mass along the Spigelian aponeurosis that appears after physical exertion and spontaneously resolves, as reported in our case,<sup>29</sup> makes the diagnosis apparent.<sup>28</sup> In doubtful cases US, CT, and MRI should be considered.<sup>11</sup> A carefully performed US examination with a high-resolution linear transducer may demonstrate the fascial defect, the hernia sac, and its contents<sup>5</sup>; the test can also be conducted in association with Valsalva maneuver to help identify the hernia orifice and evaluate parietal muscle contractility. Differential diagnosis of SH in children includes the following: appendicitis and appendiceal abscess, ventral or inguinal hernia, tumor of the abdominal wall, and spontaneous hematoma of the rectus sheath.<sup>30</sup> SHs are usually small and the risk of strangulation is high, so it should be repaired.<sup>8,10,31</sup>

In adults, the validity of laparoscopic treatment is widely confirmed.<sup>29</sup> Recent studies support the possible role of laparoscopy in the diagnosis and treatment of SH also in children, suggesting that it may represent an acceptable therapeutic alternative.<sup>32</sup> The open surgery is still considered the technique of choice in children. In case of palpable hernia, transverse incision is recommended over the protrusion. External oblique aponeurosis is incised in the direction of its fibers to expose the peritoneal sac. Median or paramedian incision is indicated if there is not any palpable hernia or hernia orifice.<sup>10,28</sup> In pediatric age, recurrent rates following such repairs have been reported to be very low.<sup>7,8</sup> The hernial sac contains commonly testis, preperitoneal fat, small intestine, colon, omentum, although herniation of a Meckel diverticulum, gallbladder, stomach, urinary bladder, and ovary have been rarely reported in children.<sup>3-5,11-21</sup> After the hernia content reduction, the sac is excised and the fascia defect is closed with suture in layers. When the defect is larger and with coexisting recurrent risk factors, prosthetic

mesh, in the preperitoneal space or above the fascia, may be required to reinforce the suture and supports the laxity of Spigelian band<sup>7,21</sup> (→Table 2).

#### Conflict of Interest

None.

#### References

- Klinkosch JT. Programma Quo Divisionem Herniarum, Novumque Herniae Ventralis Specium Proponit. Berman. Rotterdam; 1764
- Scopinaro AJ. Hernia on spigels semilunar line in a newborn. *Sem Med* 1935;1:284-285
- Al-Salem AH. Congenital spigelian hernia and cryptorchidism: cause or coincidence? *Pediatr Surg Int* 2000;16(5-6):433-436
- Rushfeldt C, Oltmanns G, Vonen B. Spigelian-cryptorchidism syndrome: a case report and discussion of the basic elements in a possibly new congenital syndrome. *Pediatr Surg Int* 2010;26(9):939-942
- Levy G, Nagar H, Blachar A, Ben-Sira L, Kessler A. Pre-operative sonographic diagnosis of incarcerated neonatal Spigelian hernia containing the testis. *Pediatr Radiol* 2003;33(6):407-409
- Moles Morenilla L, Gómez Rubio D, Sánchez Blanco JM, Galindo Galindo A, Recio Moyano O, Brox Jiménez A. [The new congenital Spigelian hernia and cryptorchidism syndrome. Analysis of 16 cases]. *Cir Esp* 2008;84(3):154-157
- Durham MM, Ricketts RR. Congenital spigelian hernias and cryptorchidism. *J Pediatr Surg* 2006;41(11):1814-1817
- Larson DW, Farley DR. Spigelian hernias: repair and outcome for 81 patients. *World J Surg* 2002;26(10):1277-1281
- Stoppa R. Spigelian hernias. In: Chevrel JP, ed. *Hernia and Surgery of the Abdominal Wall*. 2nd ed. Berlin Heidelberg New York: Springer-Verlag; 1997:267-269
- Spangen L. Spigelian hernia. *Surg Clin North Am* 1984;64(2):351-366
- Losanoff JE, Richman BW, Jones JW. Spigelian hernia in a child: case report and review of the literature. *Hernia* 2002;6(4):191-193
- White JJ. Concomitant Spigelian and inguinal hernias in a neonate. *J Pediatr Surg* 2002;37(4):659-660
- Raveenthiran V. Congenital Spigelian hernia with cryptorchidism: probably a new syndrome. *Hernia* 2005;9(4):378-380
- Vaos G, Gardikis S, Zavras N. Strangulated low Spigelian hernia in children: report of two cases. *Pediatr Surg Int* 2005;21(9):736-738
- Torres de Aguirre A, Cabello Laureano R, García Valles C, Garrido Morales M, García Merino F, Martínez Caro A. [Spigelian hernia: two cases associated to cryptorchidism]. *Cir Pediatr* 2005;18(2):99-100
- Aksu B, Temizöz O, Inan M, Gençhellaç H, Başaran UN. Bilateral spigelian hernia concomitant with multiple skeletal anomalies and fibular aplasia in a child. *Eur J Pediatr Surg* 2008;18(3):205-208
- Christianakis E, Paschalidis N, Filippou G, Rizos S, Smailis D, Filippou D. Low Spigelian hernia in a 6-year-old boy presenting as an incarcerated inguinal hernia: a case report. *J Med Case Reports* 2009;3:34
- Fascetti-Leon F, Gobbi D, Gamba P, Cecchetto G. Neonatal bilateral spigelian hernia associated with undescended testes and scalp aplasia cutis. *Eur J Pediatr Surg* 2010;20(2):123-125
- Lopez R, King S, Maoate K, Beasley S. Trauma may cause Spigelian hernia in children. *ANZ J Surg* 2010;80(9):663
- Vega Y, Zequeira J, Delgado A, Lugo-Vicente H. Spigelian hernia in children: case report and literature review. *Bol Asoc Med PR* 2010;102(4):62-64

**Table 2** Main features of Spigelian hernia

- Congenital or acquired defect of Spigelian fascia, located between the rectus abdominis muscle medially and the semilunar line laterally.
- The external oblique fascia is generally intact.
- The hernia sac is located between the internal oblique muscle and aponeurosis of the transversus muscle and contains mostly preperitoneal fat, small intestine, colon, and omentum.
- SH can be associated with cryptorchidism; in most of these cases, the undescended testis is located in the hernia sac.
- Often asymptomatic; symptoms and signs ranging from pain, swelling, intermittent abdominal pain to acute abdomen.
- Differential diagnosis with appendiceal abscess, ventral or inguinal hernia, tumor of the abdominal wall, spontaneous hematoma of the rectus sheath.
- SH in children is small and has to be repaired because of a high risk of incarceration: open surgery is the technique of choice.

Abbreviation: SH, Spigelian hernia.

- 21 Singal AK, Ravikumar VR, Kadam V, Jain V. Undescended testis in Spigelian hernia—a report of 2 cases and review of the literature. *Eur J Pediatr Surg* 2011;21(3):194–196
- 22 Bilici S, Güneş M, Göksu M, Melek M, Pirinçci N. Undescended testis accompanying congenital Spigelian hernia: is it a reason, a result, or a new syndrome? *Eur J Pediatr Surg* 2012;22(2):157–161
- 23 Inan M, Basaran UN, Aksu B, Dortdogan Z, Dereli M. Congenital Spigelian hernia associated with undescended testis. *World J Pediatr* 2012;8(2):185–187
- 24 Sudhir KT, Salabh G, Saurabh G. Traumatic Spigelian Hernia Due to Handlebar Injury in a Child: A Case Report and Review of Literature. *Indian J Surg* 2013;75(Suppl):(1):404–406
- 25 Skandalakis PN, Zoras O, Skandalakis JE, Mirilas P. Spigelian hernia: surgical anatomy, embryology, and technique of repair. *Am Surg* 2006;72(1):42–48
- 26 Raveenthiran V. Congenital spigelian hernia and cryptorchidism: a distinct clinical syndrome. *J Pediatr Surg* 2007;42(10):1794–1795
- 27 Mirilas P. Congenital spigelian hernia and undescended testis: pitfalls in the transformation of a “coexistence” to “sequence” and “new syndrome”. *Eur J Pediatr Surg* 2013;23(2):167–168
- 28 Mittal T, Kumar V, Khullar R, et al. Diagnosis and management of spigelian hernia: A review of literature and our experience. *J Minim Access Surg* 2008;4(4):95–98
- 29 Ruiz de la Hermosa A, Amunategui Prats I, Machado Liendo P, Nevarez Noboa F, Muñoz Calero A. Spigelian hernia. Personal experience and review of the literature. *Rev Esp Enferm Dig* 2010;102(10):583–586
- 30 Graivier L, Bronsther B, Feins NR, Mestel AL. Pediatric lateral ventral (spigelian) hernias. *South Med J* 1988;81(3):325–326
- 31 Vos DJ, Scheltinga MR. Incidence and outcome of surgical repair of spigelian hernia. *Br J Surg* 2004;91(5):640–644
- 32 Lopez R, King S, Maoate K, Beasley S. Laparoscopic repair of paediatric traumatic Spigelian hernia avoids the need for mesh. *ANZ J Surg* 2011;81(5):396–397