

Pure transgastric NOTES ovarian cystectomy: the first human procedure

Natural orifice transluminal endoscopic surgery (NOTES) is an evolving minimally invasive procedure that aims to eliminate abdominal trauma as well as its related complications such as incisional hernia, infection, or abscess. However, most current NOTES procedures are performed with the help of laparoscopic instruments, which deviates from the initial NOTES purpose of no-scar surgery [1,2]. After safely and successfully accomplishing pure transgastric NOTES salpingostomy for ectopic pregnancy in a young woman [3], we went on to perform transgastric NOTES in a 23-year-old woman with an ovarian cyst.

On 21 July 2013, a 23-year-old woman was admitted to our hospital for a 2-month history of lower abdominal pain. She was a virgin and had no history of abdominal surgery. Ultrasonography showed a left ovarian cyst measuring 6×5 cm which was described as giving a regular-shaped,

well-distributed internal echo with a well-defined boundary. The patient feared experiencing abdominal pain postoperatively and wanted to have no abdominal scar. All the procedure-related risks and advantages were discussed with her and she gave her informed consent prior to the procedure. The procedure was previously approved by the hospital ethical committee.

The procedure was performed in the following stages. First, gastric access was created using a percutaneous endoscopic gastrostomy (PEG)-like technique. Pneumoperitoneum was then established using a 0.35-inch flexible abdominal drainage catheter, which was placed on the right lower abdomen and connected to a laparoscopic insufflator [3]. The pelvic cavity including the uterus (● Fig. 1 a) and bilateral adnexa was detected and a left ovarian cyst was found (● Fig. 1 b). The ovarian cystectomy was carried out as fol-

lows. A Hook knife was used to perform ovarian cystotomy. The cystic wall tissues were then bluntly dissected from the ovarian cortex using a biopsy forceps, with electrocautery using an argon knife for the part close to the ovarian hilum (● Fig. 1 c). The edge of the ovarian incision was cauterized to protect it from reforming an ovarian cyst (● Fig. 1 d). Finally, the gastric incision was closed with a combination of endoclips and nylon loops (● Fig. 1 e).

The cystic tissue was removed successfully, giving a specimen of 5.0×5.0 cm (● Fig. 1 f). The operative time was 130 minutes. The patient did well postoperatively. She did not feel obvious abdominal pain and could move freely without fear. She took fluid orally on the 3rd postoperative day with no discomfort. Antibiotics were given to her for prevention of infection during the first 3 postoperative days. The pathological diagnosis was simple ovarian cyst. The patient was discharged on the 4th postoperative day.

Endoscopy_UCTN_Code_TTT_1AT_2AF

Competing interests: None

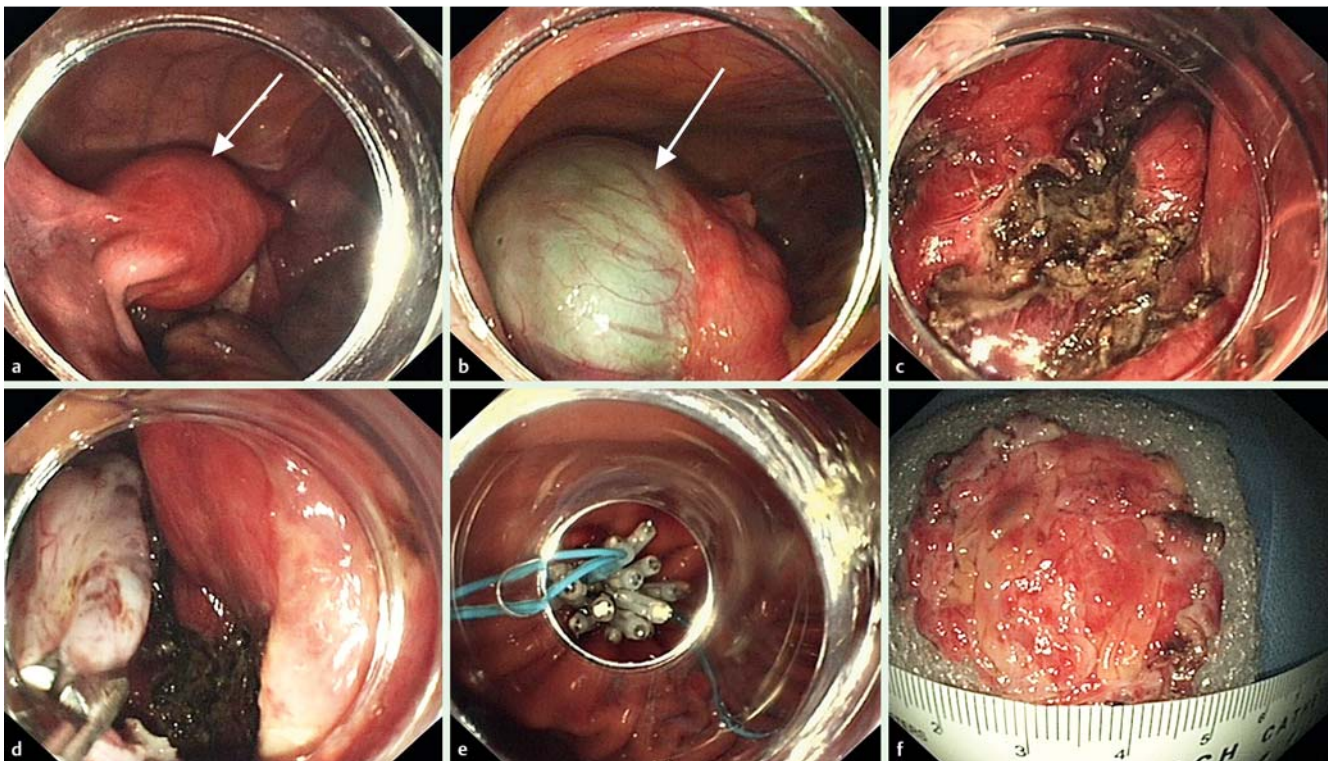


Fig. 1 Endoscopic views during pure natural orifice transluminal endoscopic surgery (NOTES) in a young woman with left ovarian cyst: **a** uterus (arrow); **b** ovarian cyst; **c** ovarian cortex after blunt dissection and electrocautery; **d** cautery of the ovarian incision edge; **e** completed gastric closure with endoclips and nylon loops; **f** surgical specimen.

**Bing-Rong Liu^{1*}, Guang-Xing Cui^{1*},
Xue-Yan Zhang¹, Kavanjit Kaur¹,
Ji-Tao Song¹, Yu Si², Xian-Chao Kong²**

¹ Department of Gastroenterology and Hepatology, the Second Affiliated Hospital of Harbin Medical University, Harbin, China

² Department of Gynecology and Obstetrics, the Second Affiliated Hospital of Harbin Medical University, Harbin, China

* The first two authors contributed equally to this article.

References

- 1 *Coomber RS, Sodergren MH, Clark J et al.* Natural orifice transluminal endoscopic surgery applications in clinical practice. *World J Gastrointest Endosc* 2012; 4: 65–74
- 2 *Mohan HM, O'Riordan JM, Winter DC.* Natural orifice transluminal endoscopic surgery (NOTES): minimally invasive evolution or revolution? *Surg Laparosc Endosc Percutan Tech* 2013; 23: 244–250
- 3 *Liu BR, Kong XC, Cui GX et al.* Pure transgastric NOTES in an adnexal procedure: the first human case report. *Endoscopy* 2013; 45: E290–E291

Bibliography

DOI <http://dx.doi.org/10.1055/s-0034-1365290>
Endoscopy 2014; 46: E199–E200
© Georg Thieme Verlag KG
Stuttgart · New York
ISSN 0013-726X

Corresponding author

Xian-Chao Kong, MD

Department of Gynecology and Obstetrics
The Second Affiliated Hospital of Harbin Medical University
246 Xue-fu Road
Nan-gang District
Harbin 150086
China
Fax: +86-451-86605980
18249517043@163.com