In vivo appearances of gallbladder carcinoma under magnifying endoscopy and probe-based confocal laser endomicroscopy after endosonographic gallbladder drainage

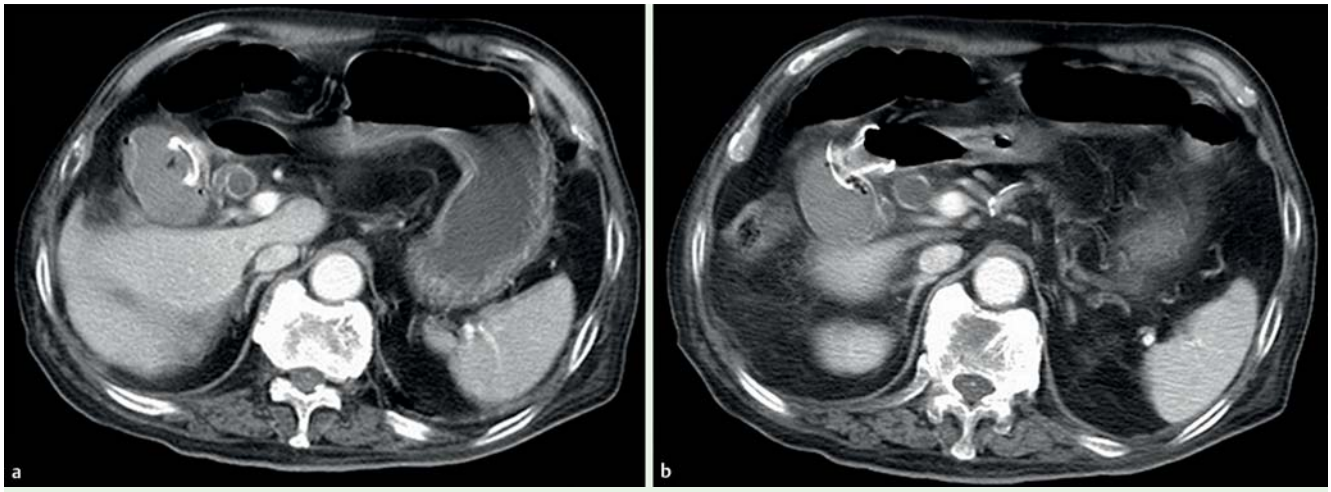

Fig. 1 **a, b** Computed tomography showing the lumen-apposing stent drainage of the gallbladder to the first part of the duodenum.

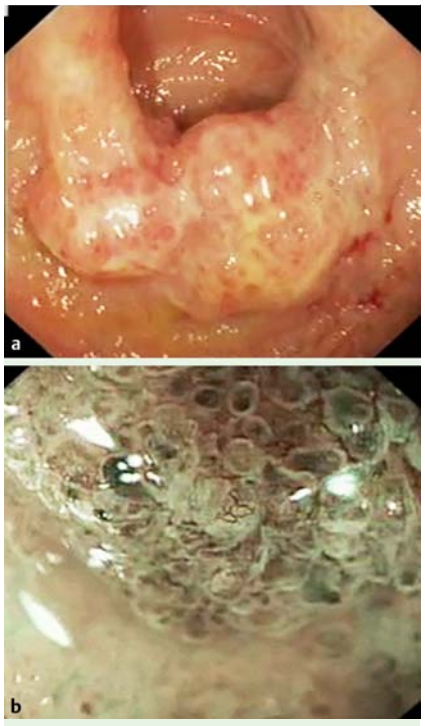

Fig. 2 Gallbladder adenocarcinoma in an 87-year-old man, seen at follow-up endoscopy 3 months after endosonographic gallbladder drainage with a lumen-apposing stent: **a** white light endoscopic view; **b** magnified narrow band imaging (NBI) appearance.

An 87-year-old man with multiple medical co-morbidities was admitted for right upper quadrant pain and fever. Computed tomography showed a distended gallbladder with gallstones and pericholecystic fluid compatible with a diagnosis of acute cholecystitis. There was no gallbladder mass. Since the patient had sepsis and was unfit for surgery, endoscopic ultrasound (EUS) drainage of the gallbladder was performed with a lumen-apposing stent (10×15 mm, AXIOS; Xlumena, Mountain View, California, USA) as an alternative to percutaneous cholecystostomy (**Fig. 1 a, b**). The patient had an uneventful recovery.

Follow-up cholecystoscopy performed 3 months later showed clearance of all stones. However, a 2-cm polypoid lesion was noted at the fundus of the gallbladder. Magnifying narrow band imaging (NBI) showed enlarged and irregular mucosal glands with dilated and corkscrew-appearance microvasculature that was suspicious for malignancy (**Fig. 2**). Probe-based confocal laser endomicroscopy (CLE) (GastroFlex; Mauna Kea Technologies, France) showed darkened and irregular columnar cells with loss of villous architecture (**Fig. 3 a, b**). Miniprobe EUS examination (UM-DP12–25R; Olympus, Tokyo, Japan) showed suspicion of tumor involvement of the gallbladder muscularis propria (**Fig. 4**). Final histological findings confirmed the presence of a gallbladder adenocarcinoma (**Fig. 5**). The patient was then treated conservatively as he was too frail to undergo any major surgery.

To our knowledge, this is the first description of a gallbladder adenocarcinoma discovered endoscopically. This was made possible through the use of endosonographic drainage that allowed endoscopic assessment of the gallbladder [1, 2]. Magnifying NBI endoscopy has revolutionized the diagnosis of early gastrointestinal neoplasms and is pivotal to performance of endoscopic mucosal resection or submucosal dissection [3]. CLE allows in vivo assessment of cellular architecture and has been shown to be associated with high sensitivity and specificity for diagnosis of Barrett's metaplasia and biliary malignancy [4]. EUS-guided gallbladder drainage in this patient opened the way for application of the above instruments in aiding diagnosis that was not suspected on CT.

Endoscopy_UCTN_Code_CCL_1AZ_2AC

Competing interests: None

This document was downloaded for personal use only. Unauthorized distribution is strictly prohibited.

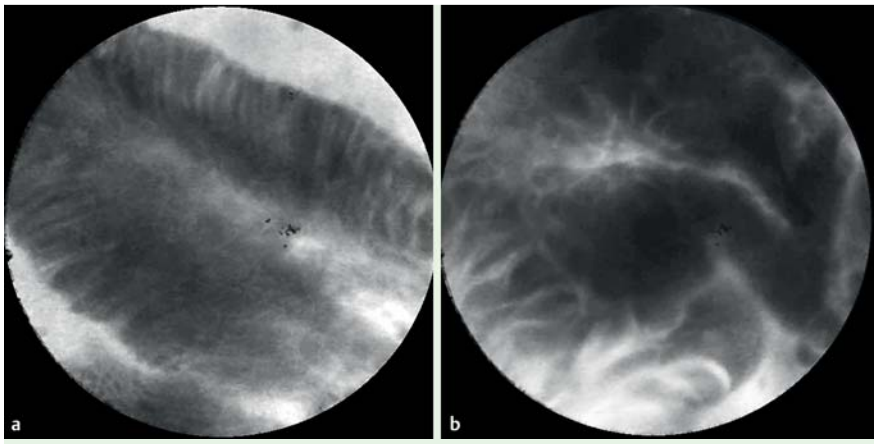

Fig. 3 **a** Confocal laser endomicroscopy (CLE) image of the normal-looking gallbladder mucosa, showing villous architecture with columnar epithelium. **b** CLE image of the gallbladder adenocarcinoma, displaying marked darkened, variably sized glands.

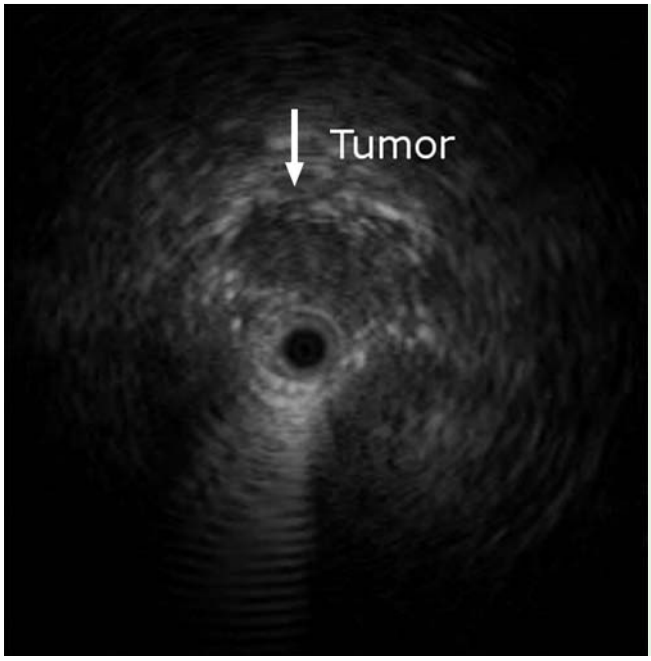

Fig. 4 Miniprobe examination with endoscopic ultrasound (EUS) showed tumor involvement of the muscularis propria of the gallbladder.

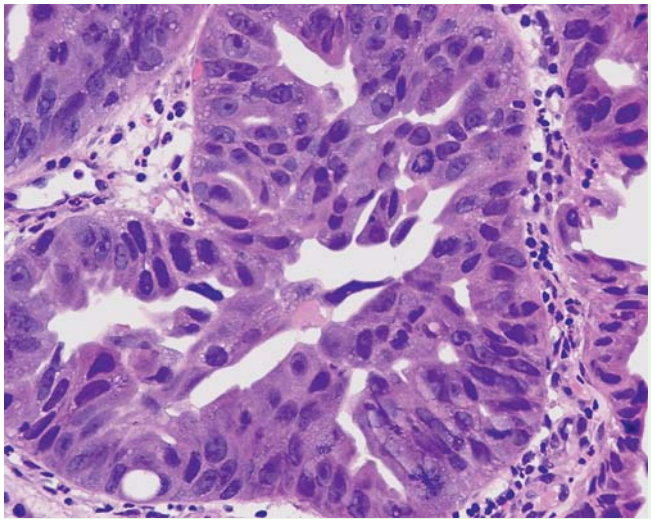

Fig. 5 A complex cribriform malignant gland is present in the stroma supporting the diagnosis of adenocarcinoma (hematoxylin and eosin [H&E], original magnification ×400).

Anthony Y. B. Teoh[1], Anthony W. H. Chan[2], Philip W. Y. Chiu[1], James Y. W. Lau[1]

[1] Department of Surgery, Prince of Wales Hospital, The Chinese University of Hong Kong, Hong Kong SAR

[2] Department of Anatomical and Cellular Pathology, Prince of Wales Hospital, The Chinese University of Hong Kong, Hong Kong SAR

References

1 *de la Serna-Higuera C, Pérez-Miranda M, Gil-Simón P* et al. EUS-guided transenteric gallbladder drainage with a new fistula-forming, lumen-apposing metal stent. Gastrointest Endosc 2013; 77: 303–308

2 *Itoi T, Binmoeller KF, Shah J* et al. Clinical evaluation of a novel lumen-apposing metal stent for endosonography-guided pancreatic pseudocyst and gallbladder drainage (with videos). Gastrointest Endosc 2012; 75: 870–876

3 Endoscopic Classification Review Group. Update on the Paris Classification of superficial neoplastic lesions in the digestive tract. Endoscopy 2005; 37: 570–578

4 *Nakai Y, Isayama H, Shinoura S* et al. Confocal laser endomicroscopy in gastrointestinal and pancreatobiliary diseases. Dig Endosc 28. 08. 2013. doi: 10.1111/den.12152 [Epub ahead of print]

Bibliography

DOI http://dx.doi.org/10.1055/s-0033-1359139
Endoscopy 2014; 46: E13–E14
© Georg Thieme Verlag KG
Stuttgart · New York
ISSN 0013-726X

Corresponding author

Anthony Y. B. Teoh, MD
Department of Surgery, Prince of Wales Hospital
The Chinese University of Hong Kong
Shatin, Hong Kong
Fax: +852-2637-7974
anthonyteoh@surgery.cuhk.edu.hk

This document was downloaded for personal use only. Unauthorized distribution is strictly prohibited.