Evaluation of Newly Adapted Clip Marker System in Ultrasound-Guided Core Needle Biopsy for Suspicion of Breast Cancer

Untersuchung eines neu entwickelten, direkt adaptierten Markierungsclip-Systems während sonografisch gesteuerter Stanzbiopsie bei Verdacht auf Mammakarzinom

Authors R. Schulz-Wendtland[1], P. Dankerl[1], G. Dilbat[2], M. Bani[3], P. A. Fasching[3], K. Heusinger[3], M. P. Lux[3], C. R. Loehberg[3], S. M. Jud[3], C. Rauh[3], C. M. Bayer[3], M. W. Beckmann[3], M. Uder[4], M. Meier-Meitinger[1], B. Brehm[1]

Affiliations
[1] Gynäkologische Radiologie, Radiologisches Institut des Universitätsklinikums Erlangen, Erlangen
[2] Radiologie, Radiologie Roth, Roth
[3] Frauenklinik, Universitätsklinikum Erlangen, Erlangen
[4] Radiologisches Institut, Universitätsklinikum Erlangen, Erlangen

Key words
- breast
- breast cancer
- ultrasound
- biopsy

Schlüsselwörter
- Mamma
- Mammakarzinom
- Ultraschall
- Biopsie

Deutschsprachige Zusatzinformationen online abrufbar unter: www.thieme-connect.de/ejournals/toc/gebfra

received 5.7.2013
revised 19.9.2013
accepted 19.9.2013

Bibliography
DOI http://dx.doi.org/10.1055/s-0033-1351086
Geburtsh Frauenheilk 2013; 73: 1135–1138 © Georg Thieme Verlag KG Stuttgart · New York · ISSN 0016-5751

Correspondence
Prof. Rüdiger Schulz-Wendtland, Dr. med.
Radiologisches Institut des Universitätsklinikums Erlangen
Gynäkologische Radiologie
Universitätsstraße 21–23
91054 Erlangen
ruediger.schulz-wendtland@uk-erlangen.de

Abstract

Introduction: A newly adapted clip system for intramammary marking during ultrasound-guided core needle biopsy for suspicion of breast cancer is described and evaluated here.
Material and Method: Fifty patients with suspicion of breast cancer (cT2) had ultrasound-guided core needle biopsy using a newly adapted clip marker system (HistoCore™ and O-Twist Marker™). Subsequently, ultrasound follow-up and tomosynthesis scans were done to determine the location of the marker clips.
Results: No dislocation of the marker clip was detected on ultrasound in 45 of 50 patients (90%), and 5 patients (10%) had a maximum dislocation of 5 mm along the x-, y- or z-axis. Tomosynthesis scans demonstrated precise placement without dislocation of the clip markers in 48 patients (96%); 2 patients (4%) had a maximum dislocation of 3 mm along the x-, y- or z-axis.
Conclusion: The newly developed clip marker system, a combination of a single-use breast biopsy needle and a precise, length-adapted intramammary marker clip, represents a further improvement in oncological therapy. This is of particular importance for patients requiring subsequent neoadjuvant chemotherapy, as in cases with complete tumour remission, there is no target point for preoperative, ultrasound-guided wire marking.

Zusammenfassung

Einleitung: Vorstellung und Untersuchung eines neu entwickelten, direkt adaptierten Clipsystems zur Optimierung der intramammären Clipmarkierung während sonografisch gesteuerter Stanzbiopsie bei Verdacht auf Mammakarzinom.
Material und Methode: Bei 50 Patientinnen mit Verdacht auf Mammakarzinom (cT2) erfolgte eine sonografisch gesteuerte Stanzbiopsie mit gleichzeitiger neu entwickelter adaptierter Clipmarkierung (HistoCore™ und O-Twist Marker™). Anschließend wurden sonografische Kontrolluntersuchungen und eine Tomosynthese zur Lokalisationsbestimmung des Markierungsclips durchgeführt.
Ergebnisse: Bei 45 der 50 Patientinnen war sonografisch keine Dislokation eines Markierungsclips diagnostizierbar (90%), bei 5 Patientinnen (10%) ergab sich eine Dislokation von max. 5 mm in x-, y- bzw. z-Achse. Die Tomosynthese zeigte eine exakte Platzierung ohne Dislokation des Markierungsclips bei 48 Patientinnen (96%), bei 2 Patientinnen (4%) stellte sich eine Dislokation von maximal 3 mm in x-, y- bzw. z-Achse dar.
Schlussfolgerung: Durch unsere Neuentwicklung, der Kombination von Mamma-Einmal-Biopsie-Nadel und exakt längenadaptierter intramammärer Clipmarkierung ist eine weitere Optimierung in der onkologischen Therapie gegeben. Dies ist von ganz besonderer Bedeutung vor neoadjuvanter Chemotherapie, da bei Komplettremission des Tumors ein Zielpunkt für die präoperative, sonografisch gesteuerte Drahtmarkierung fehlt.

Introduction

Women have a 10% risk of developing breast cancer at some stage in their life. This makes breast cancer the most common type of cancer found in women and the most common cause of death for women between the ages of 35 and 55 years. In Germany, around 58 000 women develop breast cancer every year, and approximately 20 000 die of it [1]. The treatment options and the characteristics determining the choice of therapy in patients with primary advanced breast cancer are

becoming ever more varied. New targeted therapies combined with established chemotherapies have expanded the range of options [2–8].

Both European treatment recommendations and the German interdisciplinary S3-Guideline on the Diagnosis, Therapy and Follow-up of Breast Cancer [9] propose that at least 70% of all breast lesions suspicious for malignancy (BI-RADS™ 4/5) be verified histologically preoperatively – the target is 90% of lesions [9–12]. By preoperatively investigating suspected malignant processes, the aim is to ensure that only one surgical intervention will be necessary. In addition, all non-palpable breast lesions should be marked prior to the actual surgical intervention (e.g. ultrasound-guided wire marking) [9–13].

Therapy studies performed in recent years in a neoadjuvant setting have greatly increased our understanding of the effectiveness of therapies and their impact on long-term survival [14].

Given the abundance of data on neoadjuvant chemotherapies and the good correlation with pathologic complete remission (pCR), the American Food and Drug Administration (FDA) carried out a meta-analysis of approximately 12 000 patients, which included contributions by German study groups [15]. The prognostic relevance of pCR for recurrence-free survival (HR 0.48, $p < 0.001$) and overall survival (HR 0.48, $p < 0.001$) was confirmed beyond doubt. It was found that there were no significant differences between the various definitions of pCR (with or without the inclusion of DCIS). As regards tumour biology, the study found that the more aggressive and sensitive to chemotherapy the tumour was, the higher the prognostic relevance of pCR.

However, the neoadjuvant therapy concept represents new challenges for breast surgeons, radiologists and pathologists, as with pCR there is no target point for preoperative, ultrasound-guided wire marking. This problem can be effectively solved by placing marker clips at the site of the primary breast tumour during ultrasound-guided core needle biopsy prior to neoadjuvant chemotherapy [16–19].

Based on our own extensive experience [20], the aim of our study was to evaluate the precision of a newly developed method of clip marking in patients suspicious for breast cancer.

Material and Methods

Single-use breast biopsy system (HistoCore™)

A single-use breast biopsy system (HistoCore™; BIP™ Biomed. Instrumente & Produkte GmbH, Germany) (**Fig. 1**) [20] was used, together with a 12 gauge, 10 cm long needle with a notch length of 18 or 25 mm. After careful disinfection of the skin and administration of a local anaesthetic (10 ml), the single-use breast biopsy system (a combination of a coaxial cannula [11 gauge] and a core needle [12 gauge]) was placed over the tumour focus, and core needle biopsy was done under ultrasound control, with the biopsy performed tangentially to the linear 13.0-MHz transducer. The needle length prior to and after the intervention was documented in pictures and on video. Four or more core needle biopsy specimens were obtained to obtain sufficient material for histological diagnosis and molecular-genetic investigation. A clip was placed in the puncture area directly above the coaxial needle (11 gauge), i.e. in the middle of the tumorous lesion.

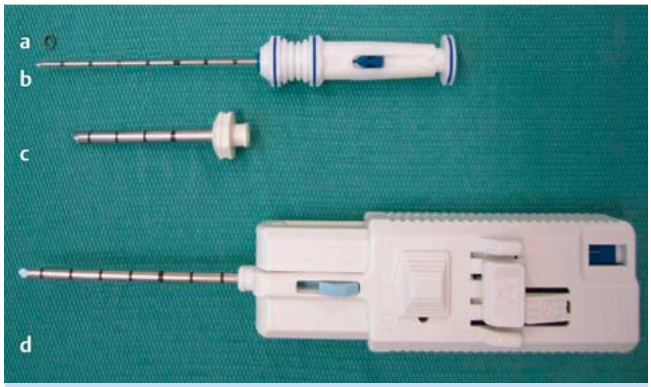

Fig. 1 a to **d** Single-use breast biopsy and clip marker system. **a** Clip, made of three biocompatible nitinol wires with diameters of 0.15 mm (memory metal) twisted together to form rings with a diameter of 2.5 mm. **b** Directly adapted, precise clip marker system (O-Twist Marker™), (20 gauge) – our own new development without a spacer. **c** Coaxial needle (11 gauge) precisely adapted to the single-use breast biopsy system (HistoCore™). **d** Single-use breast biopsy system (HistoCore™): 12 gauge needle, needle length: 10 cm, optional notch length: 18 or 25 mm.

Clip system (O-Twist Marker™)

The O-Twist Marker™ clip system (Biomed. Instrumente & Produkte GmbH [BIP™], Germany) has been on the market since 2003 [21]; it was modified by us in 2012 in cooperation with BIP™ by precisely adapting the length of the stylet to the HistoCore™ single-use breast biopsy system (**Fig. 1**).

The O-Twist Marker™ consists of three biocompatible nitinol wires with diameters of 0.15 mm (memory metal) twisted together to form rings with a diameter of 2.5 mm. Each ring is flattened and inserted into a 20-G cannula. The marker is ejected from the cannula through the stylet into the breast tissue where it assumes its pre-assigned ring shape again at body temperature. After placing the marker clip, control ultrasound (2D, Acuson Antares, 13 MHz; Siemens™) and tomosynthesis (Selenia Dimensions3D™; Hologic™) scans are carried out, which include computer-aided detection or diagnosis (CAD™ [R2™]) [19,22], to precisely locate the marker clip.

Results

Technical development

Our innovation consisted of the precise adaptation of stylet length to the HistoCore™ single-use breast biopsy system [20] (**Fig. 1**). Before, when using the O-Twist Marker™ clip system [21] (placed directly through the coaxial core needle for the biopsy), the notch length used during marker clip placement had to be varied for every procedure, depending on the respective length of the core needle, using a pre-fabricated sliding spacer fitted over the stylet. This approach was imprecise, as it was not possible to precisely adjust the fitted spacer using only the marking rings engraved at intervals of one centimetre. Our new development now offers the possibility of placing a precise marker clip for every core length without needing a spacer.

Ultrasound-guided core needle biopsy and clip marking

Between 10/2012 and 03/2013, a total of 50 patients were examined at the University Breast Centre for suspicion of invasive breast cancer (BI-RADS™ 4/5) with a minimum lesion diameter

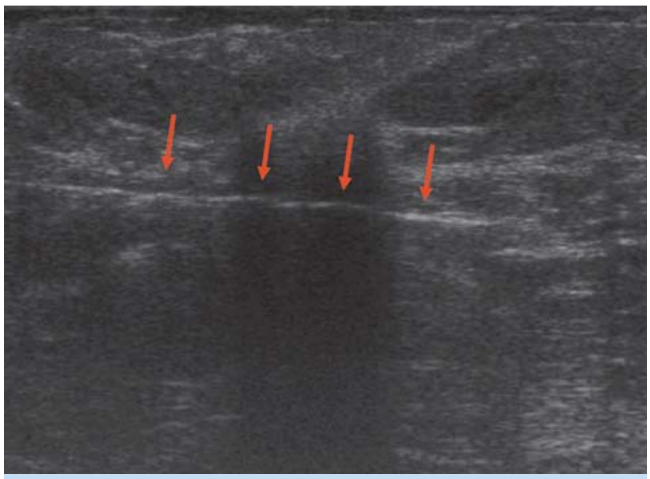

Fig. 2 Ultrasound-guided core needle biopsy of suspected breast lesions carried out using the HistoCore™ single-use breast biopsy system. The core needle is directly in the middle of the focal findings (arrows) (ultrasound done with the 2D, Acuson Antares, 13 MHz; Siemens™).

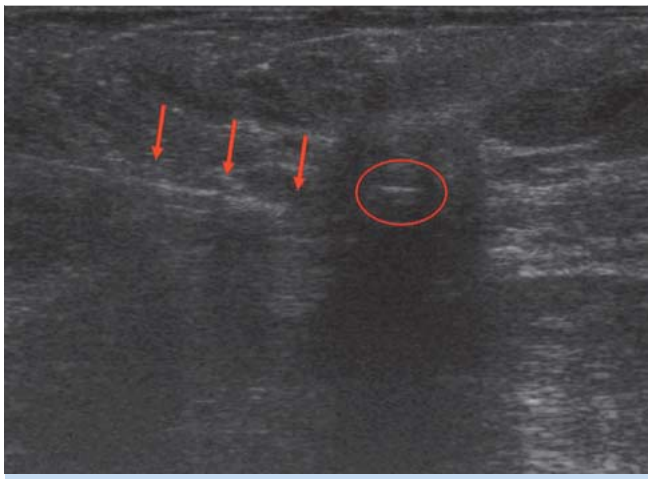

Fig. 3 Clip marking using the O-Twist Marker™ system during ultrasound-guided core needle biopsy of a suspicious breast lesion. The core needle is located directly in the lesion (arrows) after placement of the clip marker (marking circle) (ultrasound done using the 2D, Acuson Antares, 13 MHz; Siemens™).

of 2 cm (range: 2.3–3.3 cm) based on complementary breast diagnostics.

Findings were confirmed histologically in all 50 patients by ultrasound-guided core needle biopsy (**Fig. 2**) using the HistoCore™ single-use breast biopsy system [20].

In addition, intramammary marker clips were placed, using our newly developed clip system based on the well-known O-Twist Marker™ system [21] (**Fig. 3**).

Ultrasound and tomosynthesis scan to control location of marker clips

Ultrasound and tomosynthesis scans including CAD™ [19,22] were carried out after placement of the marker clips to determine the precise location of the marker clips (**Figs. 3** and **4**).

In 45 of 50 patients (90%), ultrasound found no dislocation of the marker clip; in 5 patients (10%) the maximum dislocation was 5 mm along the x-, y- or z-axis.

Tomosynthesis scans demonstrated precise placement without dislocation of the marker clip in 48 patients (96%); 2 patients (4%) had a maximum dislocation of maximal 3 mm along the x-, y- or z-axis.

Discussion

Interventional biopsy systems play an important role in complementary breast diagnostics and mammography screening (assessment). They help reduce the number of unnecessary diagnostic open surgical procedures in patients with suspicion of breast cancer (BI-RADS™ 4/5) and provide samples for the histological verification of lesions prior to the actual curative intervention or prior to neoadjuvant chemotherapy. The EUSOMA recommends reducing the number of second interventions and carrying out breast-conserving surgery in at least 70% (90% would be desirable) of all patients with breast cancer. This is only possible with the use of interventional biopsy systems [1–13].

Moreover, the inverse correlation between the number of tumour cells and the interval between biopsy and surgery suggests that displaced tumour cells do not survive. Other studies have shown that the rate of local recurrence and the interval to tumour recurrence does not differ between patients who had percutaneous core needle biopsy to verify the diagnosis and patients who had a primary surgical intervention [23–26]. Today, ultrasound-guided core needle biopsy is considered the standard approach for the diagnostic work-up of unclear lesions. Several studies have additionally shown that an identical or even higher degree of diagnostic certainty can be obtained with ultrasound-guided core needle biopsy compared to open biopsies of palpable and non-palpable findings, which have a false negative rate of between 0.3 und 8.2% [27,28].

The advantages of ultrasound-guided core needle biopsy, which can be carried out with little expenditure of time, are its limited invasiveness and the low costs involved [29,30]. Knowledge of the tumour's histological characteristics allows better planning

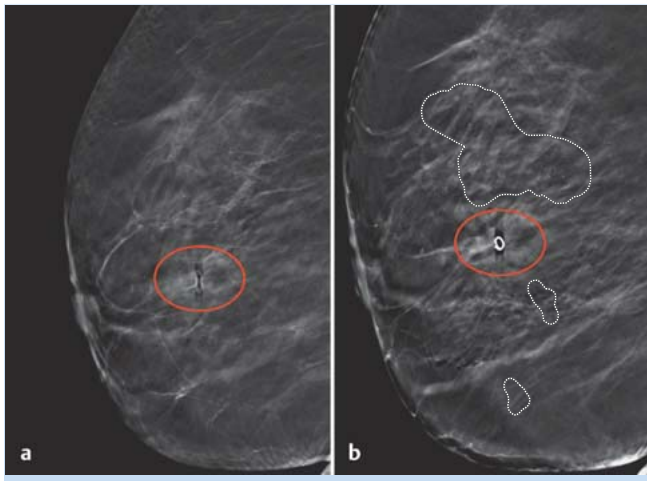

Fig. 4 a and **b** Tomosynthesis scan (Selenia Dimensions3D™; Hologic™) to control the location of the intramammary marker clip. **a** With CAD™ (R2™) – image 11; marker clip, blurred (circle), located directly in the centre of the lesion. **b** With CAD™ (R2™) – image 25; marker clip, sharply delineated (circle), located directly in the centre of the lesion; 3 areas of micro calcifications are marked (dotted lines) and classified as benign.

of surgical operations, if surgery is required, and a more targeted intervention. This is reflected in the lower rate of follow-up surgical interventions for incomplete tumour removal [31]. Moreover, around 75–80% of lesions found on imaging are benign, meaning that unnecessary surgical interventions can be avoided, provided that the assessment of the images obtained during scanning corresponds to the histological assessment of the lesion [32].

Based on our extensive experience [20] and using an established clip marker system [21], the goal of our study was to determine the precision of a new development to optimise marker placement after ultrasound-guided core needle biopsy in patients suspicious for breast cancer (BI-RADS™ 4/5). Subsequently, ultrasound and tomosynthesis scans including CAD™ (R2™) were done to monitor the precise location of the marker clips prior to carrying out further oncological therapy.

Our results confirm that our innovation permits precise adaptation of the length of the marker system used in the HistoCore™ single-use breast biopsy system. Previously, when using the O-Twist Marker™ clip system (placed directly through the coaxial core needle for the biopsy), the notch length used during marker clip placement had to be varied for every procedure, depending on the respective length of the core needle, using a prefabricated sliding spacer fitted over the stylet. This approach was imprecise as it was not possible to precisely adjust the fitted spacer using only the marking rings engraved at intervals of one centimetre. Our new development now offers the possibility of placing a precise marker clip for every core length without needing a spacer. This is particularly important prior to planned neoadjuvant chemotherapy, as in patients with pCR it is not possible to find a target point for preoperative ultrasound-guided wire marking [16–19].

Our innovation, which combines a single-use breast biopsy needle with precise, length-adapted markers clips placed directly through the coaxial needle, represents a further improvement in oncological therapy.

The results of ultrasound and tomosynthesis scans to monitor the placement and location of the marker clips confirm the precision of tomosynthesis.

Conflict of Interest

▼

The direct adaptation of the O-Twist Marker™ clip system was developed with the kind support of Biomed. Instrumente & Produkte GmbH (BIP™), Germany. BIP™ did not contribute in any way to the writing of this manuscript. The authors are alone responsible for the contents of this manuscript.

References

1 *Robert Koch-Institut.* Krebs in Deutschland 2005/2006. Häufigkeiten und Trends. Gesundheitsberichterstattung des Bundes. Berlin: Robert Koch-Institut; Gesellschaft der epidemiologischen Krebsregister in Deutschland e.V.: 2010; 56–59
2 *Fasching PA, Fehm T, Janni W et al.* Breast cancer therapy – a state of the art review. Geburtsh Frauenheilk 2010; 70: 875–886
3 *Lux MP, Maass N, Schütz F et al.* Breast cancer 2013 – interpretation of new and known data. Geburtsh Frauenheilk 2013; 73: 584–598
4 *Liedtke C, Wolf MK, Kiesel L.* New concepts for targeted systemic therapy in breast cancer. Geburtsh Frauenheilk 2010; 70: 625–633
5 *Kaufmann M, Rody A.* Breast cancer: reduced mortality by early detection and adjuvant therapy. Geburtsh Frauenheilk 2009; 69: 218–232
6 *Katalinic A.* Breast cancer: declining mortality despite its increasing incidence. Geburtsh Frauenheilk 2009; 69: 237–239
7 *Fasching PA, Ekici AB, Adamietz BR et al.* Breast cancer risk – genes, environment and clinics. Geburtsh Frauenheilk 2011; 71: 1056–1066
8 *Schulz-Wendtland R, Adamietz B, Meier-Meitinger M et al.* Sonographisch gezielte Stanzbiopsie: 15 Jahre Follow-up. Geburtsh Frauenheilk 2010; 70: 478–482
9 Interdisziplinäre S3-Leitlinie für die Diagnostik, Therapie und Nachsorge des Mammakarzinoms. AWMF 032/045OL-Kurzversion 3.0, Juli 2012. Geburtsh Frauenheilk 2013; 73: 556–583
10 *Perry NM.* Quality assurance in the diagnosis of breast disease. Eur J Cancer 2001; 37: 159–172
11 *Fischer U.* ACR-BI-RADS™ Klassifikation. Stuttgart, New York: Thieme Verlag; 2003
12 *Wallis M, Tardivon A, Helbich T et al.* Guidelines from the European Society of Breast Imaging for diagnostic interventional breast procedures. Eur Radiol 2007; 17: 581–588
13 *Albert US, Hrsg.* S3-Leitlinie Brustkrebs-Früherkennung in Deutschland. Aktualisierung 2012. München: W. Zuckschwerdt-Verlag; 2012; Online: www.senologie.org; last access: 01.07.2012
14 *von Minckwitz G, Untch M, Blohmer JU et al.* Definition and impact of pathologic complete response on prognosis after neoadjuvant chemotherapy in various intrinsic breast cancer subtypes. J Clin Oncol 2012; 30: 1796–1804
15 *Cortazar P, Zhang L, Untch M et al.* Meta-analysis results from the collaborative trials in neoadjuvant breast cancer (CTNeoBC). Cancer Res 2012; 72 (24 Suppl.): S1–S11
16 *Liberman L, Dershaw DD, Morris EA et al.* Clip placement after stereotactic vacuum-assisted breast biopsy. Radiology 1997; 205: 417–422
17 *Rosen EL, Vo TT.* Metallic clip during stereotactic breast biopsy: retrospective analysis. Radiology 2001; 218: 510–516
18 *Schulz-Wendtland R, Heywang-Köbrunner SH, Aichinger U et al.* Verbessert die Clipmarkierung im Rahmen der sonographischen oder stereotaktischen Brustbiopsie die Verlaufsbeurteilung kleiner Mammaläsionen und Lokalisation von Tumoren nach Chemotherapie? Röfo 2002; 174: 620–624
19 *Schulz-Wendtland R.* Neoadjuvant chemotherapy – monitoring: clinical examination, ultrasound, mammography, MRI, elastography: only one, only few or all? EUR J Radiol 2012; 81: 147–148
20 *Schulz-Wendtland R, Dilbat G, Bani MR et al.* HistoCore® – ein Mamma-Einmal-Biopsiesystem der nächsten Generation im täglichen klinischen Einsatz. Senologie 2010; 7: 1–4
21 *Sittek N, Heske N, Reiser M et al.* O-Twist-Marker zur postinterventionellen Markierung in der Bildgebung suspekter Mammaläsionen. Radiologe 2005; 45: 223–229
22 *Schulz-Wendtland R, Dilbat G, Beckmann MW et al.* Full field digital mammography (FFDM) versus CMOS technology, specimen radiography system (SRS) and tomosynthesis (DBT) – which system can optimise surgical therapy? Geburtsh Frauenheilk 2013; 73: 422–427
23 *Kopans DB, Gallagher WJ, Swann CA et al.* Does preoperative needle localization lead to an increase in local breast cancer recurrence? Radiology 1988; 167: 667–668
24 *Diaz LK, Wiley EL, Venta LA.* Are malignant cells displaced by large-gauge needle core biopsy of the breast? AJR Am J Roentgenol 1999; 173: 1303–1313
25 *King TA, Hayes DH, Cederbom GJ et al.* Biopsy technique has no impact on local recurrence after breast-conserving therapy. Breast J 2001; 7: 19–24
26 *Hoorntje LE, Schipper ME, Kaya A et al.* Tumour cell displacement after 14 G breast biopsy. Eur J Surg Oncol 2004; 30: 520–525
27 *Zannis VJ, Aliano KM.* The evolving practice pattern of the breast surgeon with disappearance if open biopsy for nonpalpable lesions. Am J Surg 2002; 176: 525–528
28 *Pijnappel RM, van den Donk M, Holland R et al.* Diagnostic accuracy for different strategies of image-guided breast intervention in cases of nonpalpable breast lesions. Br J Cancer 2004; 90: 595–600
29 *Libermann L, Feng TL, Dershaw DD et al.* US-guided core breast biopsy: use and cost-effectiveness. Radiology 1998; 208: 717–723
30 *Gruber R, Bernt R, Helbich TH.* Cost-effectiveness of percutaneous core needle breast biopsy (CNBB) versus open surgical biopsy (OSB) of nonpalpable breast lesions: metaanalysis and cost evaluation for German-speaking countries. Röfo 2008; 180: 134–142
31 *Liberman L, LaTrenta LR, Dershaw DD.* Impact of core biopsy on the surgical management of impalpable breast cancer: another look at margins. Am J Roentgenol 1997; 169: 1464–1465
32 *Böcker W, Hrsg.* Preneoplasia of the Breast. München: Elsevier Saunders; 2006