Diagnosis and Management of an Isolated Pediatric Plexiform Neurofibroma Involving the Hepatic and Celiac Plexus Using Multimodality Approach: Problem Solving with Diffusion-Weighted Magnetic Resonance Imaging

Merel M. Scheurkogel[1] June Koshy[1] Kenneth J. Cohen[2] Thierry A. G. M. Huisman[1] Thangamadhan Bosemani[1]

[1] Division of Pediatric Radiology, Russell H. Morgan Department of Radiology and Radiological Sciences, Johns Hopkins University School of Medicine, Baltimore, Maryland, United States
[2] The Johns Hopkins Oncology Center and Department of Pediatrics, The Johns Hopkins University School of Medicine, Baltimore, Maryland, United States

Address for correspondence Thangamadhan Bosemani, MD, Division of Pediatric Radiology, Johns Hopkins University School of Medicine, Zayed Tower, Room 4174, 1800 Orleans Street, Baltimore, MD 21287, United States (e-mail: tbosema1@jhmi.edu).

Eur J Pediatr Surg Rep 2013;1:5–8.

Abstract

Plexiform neurofibroma with involvement of the gastrointestinal tract is a very rare entity in children. Here, we present a rather unique case of a 9-year-old boy with no clinical signs or features of neurofibromatosis type 1. A periportal mass lesion was incidentally found after performing an ultrasound in this previously healthy child. Computed tomographic scan was subsequently performed which showed a low-density mass in a periportal distribution with extension along the celiac axis. Because the findings were nonspecific, a pre- and postcontrast magnetic resonance imaging of the abdomen was performed which included diffusion-weighted imaging. The lesion was then confirmed to be a plexiform neurofibroma with open biopsy. Management of plexiform neurofibromas varies widely. Given the extensive nature of the lesion, managing the patient with follow-up rather than surgical excision was favored.

Keywords
- plexiform neurofibroma
- liver
- MRI
- CT
- DWI

Introduction

We describe a unique case of a plexiform neurofibroma involving the celiac and hepatic plexus in a healthy child without stigmata of neurofibromatosis type 1 (NF-1). Given both the anatomic and functional details, magnetic resonance imaging (MRI) has proven to be the modality of choice for both diagnosis and follow-up in this case.

Case Report

A previously healthy 9-year-old boy presented with a 3-year history of nonspecific intermittent low back pain, for which a renal ultrasound was performed. The kidneys were unremarkable, but the ultrasound examination did reveal a heterogeneous hyperechogenic ill-defined infiltrative periportal mass lesion. The lesion was centered in the region of the porta hepatis with extension along the portal triads without biliary tract or vascular obstruction (►Fig. 1). A computed tomographic (CT) scan was performed that demonstrated a hypoattenuating mass lesion encasing the periportal vasculature and celiac axis without compression or obstruction (►Fig. 2). The diagnosis was not conclusive on the basis of ultrasound or CT findings, therefore MRI was performed. The MRI scan showed a T2-hyperintense, T1-hypointense, mildly

received
January 13, 2013
accepted after revision
March 15, 2013
published online
April 24, 2013

DOI http://dx.doi.org/10.1055/s-0033-1345105.
ISSN 2194-7619.

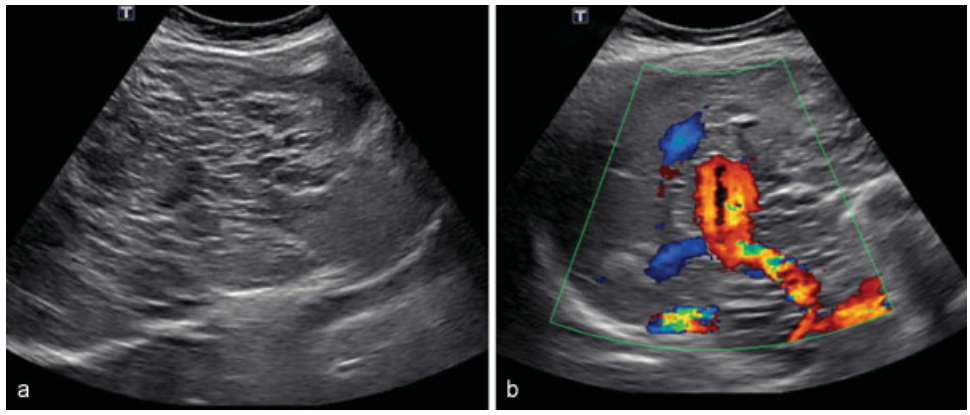

Fig. 1 (a) Ultrasound of the liver demonstrates an infiltrative hyperechoic mass within the liver. (b) The mass surrounds the portal vessels without obstruction.

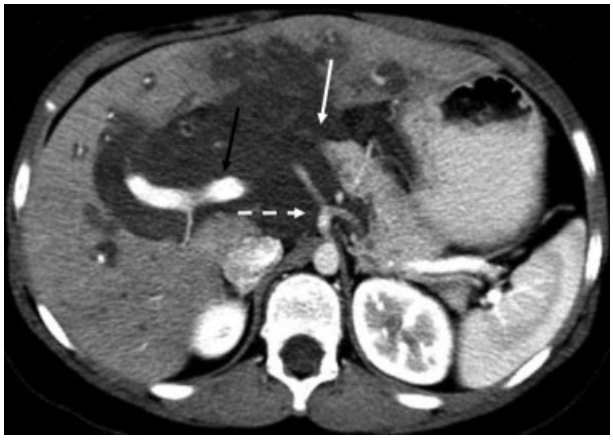

Fig. 2 Axial postcontrast computed tomographic scan at the level of the celiac axis demonstrates an infiltrative homogeneous low attenuation lesion with a periportal distribution (black arrow). The mass extends outside the liver and encases the pancreas (white arrow) and celiac axis (dashed white arrow).

enhancing polylobulated, serpiginous mass lesion within the retroperitoneal space that wrapped around the celiac trunk and extended via the porta hepatis into the liver and along the periportal spaces without obstruction of the vasculature. There was no evidence of microscopic or macroscopic fat content (►**Fig. 3**). On the basis of the ultrasonography and CT findings, the differential diagnosis included the following: lymphatic malformation, lymphoma, lipoma, liposarcoma, and plexiform neurofibroma. On the basis of the additional MRI findings, lipoma and liposarcoma were excluded. In addition, lymphoma and lymphatic malformation were unlikely because of the diffusion-weighted imaging (DWI) characteristics. Consequently, the most likely diagnosis was a benign plexiform neurofibroma.

Open liver biopsy revealed an infiltrative lesion within the liver that initially appeared cystic; however, it was determined to actually be a solid mass. Microscopic evaluation confirmed the diagnosis of neurofibroma without evidence of malignant degeneration.

Additional genetic counseling after this diagnosis revealed a negative family history; and on further clinical evaluation, the patient did not meet the minimal criteria for NF-1.

Treatment varies on the basis of the location of the lesion, clinical symptoms, and evidence of malignant degeneration. Because our patient was asymptomatic and there was no evidence of malignant degeneration, conservative treatment was opted. The DWI and the corresponding apparent diffusion coefficient (ADC) maps were crucial in the diagnostic pathway. The entire lesion had ADC value of approximately 2,097 mm^2/s, confirming its benign nature. Close clinical and imaging follow-up with MRI was recommended.

Discussion

Ultrasound and CT findings for plexiform neurofibromas of the celiac and hepatic axis are often nonspecific. Most neurofibromas tend to be hypoattenuating with ill-defined borders on CT,[1] which is thought to be the result of the myxoid and mucinous stroma of these tumors on pathological evaluation. The ropelike appearance, which represents the thickened, tortuous nerve sheath on cross section, is usually not appreciated on CT. Areas of excessive collagen can present as focal hyperattenuation. Although these features may suggest the diagnosis, CT cannot definitively distinguish neurofibromas from other malignancies.

In contrast to ultrasound and CT, neurofibromas have characteristic imaging features on MRI, and adding this modality to the diagnostic pathway can often be very helpful.[2–4]

Neurofibromas are typically heterogeneous on T2-weighted images, with high T2 signal reflecting areas of myxoid matrix and cystic degeneration and the low T2 signal reflecting areas of collagen and fibrous tissue. There is usually mild heterogeneous enhancement because of the collagen and fibrous septa. Hepatic neurofibromas may be focal or extensive, but no true liver infiltration occurs. Rather, the tumor follows the nerve fibers of the celiac and hepatic plexus, therefore extending along the periportal space. Only a few other pediatric cases have been described in which there is diffuse extension of the lesion toward the retroperitoneum

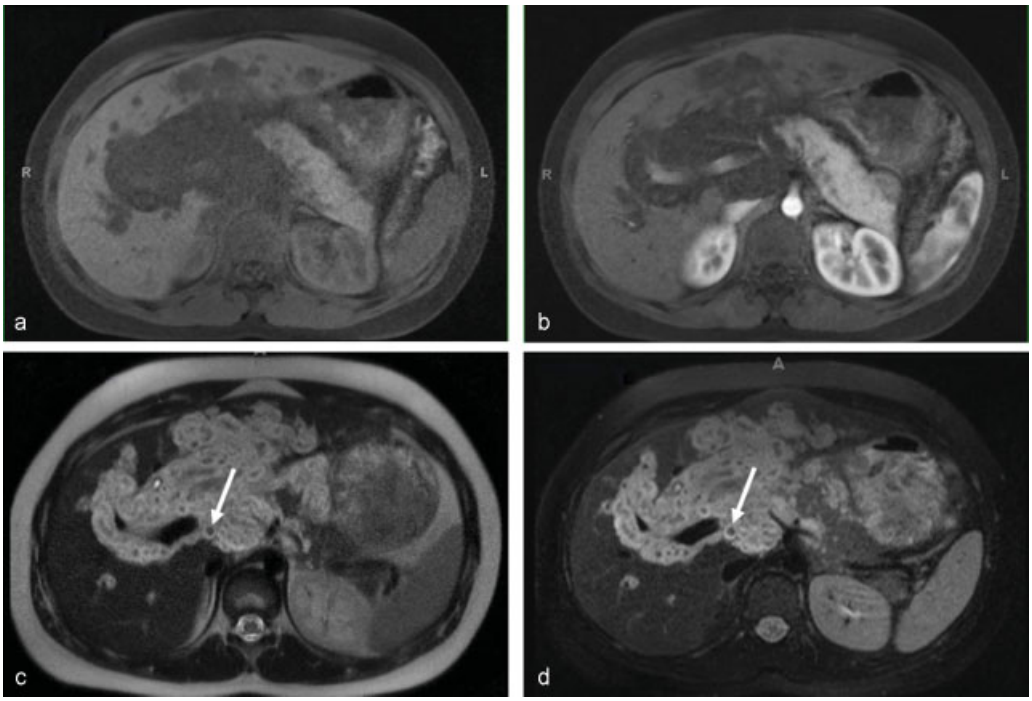

Fig. 3 Fat saturated (a) pre- and (b) postcontrast T1-axial images and (c) non–fat saturated and (d) fat saturated T2-weighted magnetic resonance images of the liver demonstrate a mildly enhancing polylobulated lesion, which is predominately T2 hyperintense with central areas of T2 hypointensity with a target appearance (white arrows). There is no loss of signal on fat saturated images.

and mesentery.[5] Because they often go unrecognized, these widespread lesions can mimic a malignancy.

The availability of DWI and the corresponding ADC maps are of great diagnostic value in allowing differentiation from solid high density tumors like lymphoma and neuroblastoma and cystic lesions such as lymphatic malformations. It is important to realize that plexiform neurofibromas can undergo malignant transformation and approximately 5% of NF-1 patients will develop malignant peripheral nerve sheath tumors.[6] Imaging findings suggesting malignant

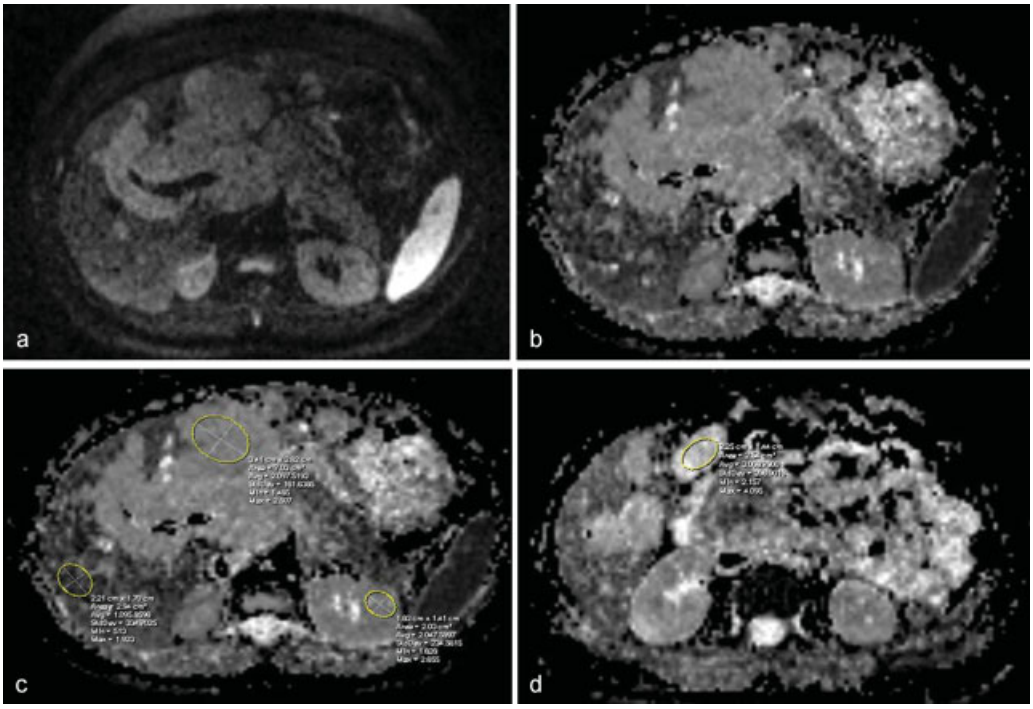

Fig. 4 (a) Axial diffusion-weighted magnetic resonance image and (b–d) axial apparent diffusion coefficient (ADC) maps demonstrate no evidence of restricted diffusion. The ADC value of the lesion measured was 2,097 mm^2/s. (c) This was elevated compared with the liver (1,095 mm^2/s); (d) however, significantly lower than fluid containing structures like the gallbladder (3,008 mm^2/s).

degeneration on MRI include an increased largest dimension of the mass, a peripheral enhancement pattern, presence of a perilesional edema-like zone, and presence of intratumoral cystic lesions.[7] DWI is also a promising adjunct to evaluate for malignant potential. In the study by Niwa et al,[6] DWI was used to differentiate between the benign and malignant areas of a retroperitoneal plexiform neurofibroma. The study showed that the malignant areas displayed high signal intensity on DWI and low signal intensity on the corresponding ADC map, likely because of high cellularity in areas of malignancy, with reducing the ability of water protons to move freely. The ADC of the malignant portion was approximately 1,200 mm^2/s, whereas the benign portion was 2,000 mm^2/s. Similar results were seen in our patient because the entire lesion had ADC values of approximately 2,097 mm^2/s (►**Fig. 4**). Consequently, DWI and ADC analysis allows us to limit the diagnosis and helps differentiate between malignant and benign plexiform neurofibromas. The optimal treatment management would be resection but extensive intra-abdominal plexiform neurofibromas are difficult to remove completely without causing significant harm. Therefore, a watchful waiting strategy can be followed. The use of DWI and ADC analysis could aid in recognizing areas of malignant transformation, and therefore, both should be included as diagnostic tools to follow progression of the disease.

Plexiform neurofibromas mainly occur in the setting of NF-1, an autosomal dominant neurocutaneous syndrome. It was thought that the presence of a plexiform neurofibroma is pathognomonic for NF-1. Our patient, however, did not meet the minimal clinical criteria for this syndrome. Although sometimes patients may develop stigmata of NF-1 later in life, there is also literature supporting that plexiform neurofibromas are highly suggestive but not exclusive for NF-1.[8]

To summarize, the use of MRI is extremely helpful in both diagnosis and management of patients with plexiform neurofibromas, especially because surgical resection is not always a viable option. In addition, it is important to remember that plexiform neurofibromas are not pathognomonic for NF-1 and this entity should be included in the differential diagnosis even in patients without clinical features of NF-1.

Conflict of Interest

None

References

1 Bass JC, Korobkin M, Francis IR, Ellis JH, Cohan RH. Retroperitoneal plexiform neurofibromas: CT findings. AJR Am J Roentgenol 1994;163(3):617–620
2 Levy AD, Patel N, Dow N, Abbott RM, Miettinen M, Sobin LH. From the archives of the AFIP: abdominal neoplasms in patients with neurofibromatosis type 1: radiologic-pathologic correlation. Radiographics 2005;25(2):455–480
3 Malagari K, Drakopoulos S, Brountzos E, et al. Plexiform neurofibroma of the liver: findings on mr imaging, angiography, and CT portography. AJR Am J Roentgenol 2001;176(2):493–495
4 Rastogi R. Intra-abdominal manifestations of von Recklinghausen's neurofibromatosis. Saudi J Gastroenterol 2008;14(2): 80–82
5 Fenton LZ, Foreman N, Wyatt-Ashmead J. Diffuse, retroperitoneal mesenteric and intrahepatic periportal plexiform neurofibroma in a 5-year-old boy. Pediatr Radiol 2001;31(9):637–639
6 Niwa T, Aida N, Fujita K, et al. Diffusion-weighted imaging of retroperitoneal malignant peripheral nerve sheath tumor in a patient with neurofibromatosis type 1. Magn Reson Med Sci 2008;7(1):49–53
7 Wasa J, Nishida Y, Tsukushi S, et al. MRI features in the differentiation of malignant peripheral nerve sheath tumors and neurofibromas. AJR Am J Roentgenol 2010;194(6):1568–1574
8 Lin V, Daniel S, Forte V. Is a plexiform neurofibroma pathognomonic of neurofibromatosis type I? Laryngoscope 2004;114(8): 1410–1414