

Efficient and safe esophageal endoscopic submucosal dissection using inverted overtube after changing patient position



Fig. 1 The outer appearance of the new inverted endoscopic overtube (Endo Rescue, TOP Co. Tokyo, Japan).

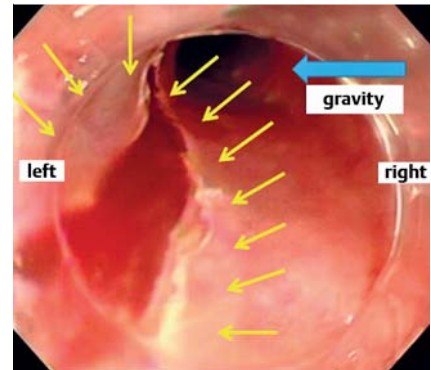


Fig. 2 Water and blood pooled over the lesion in the left esophageal wall when the patient was in the left lateral position (yellow arrows) due to the direction of gravity (blue arrow).

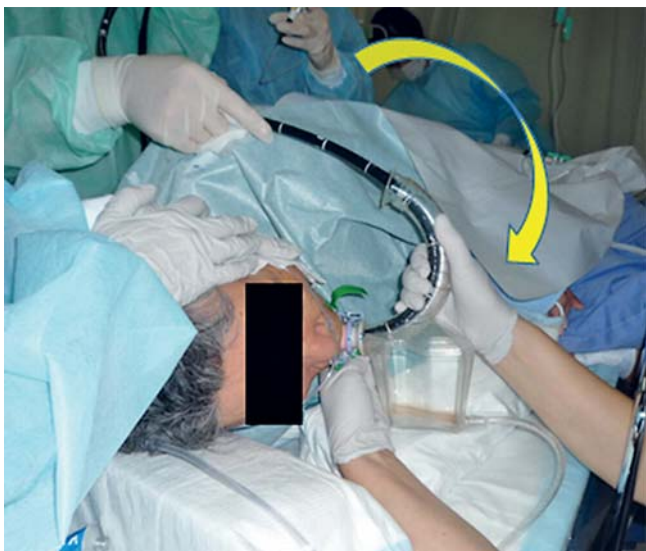

Fig. 3 The patient was rotated to the right lateral position (yellow curved arrow) and endoscopic submucosal dissection was restarted using the Endo Rescue. The endoscope was inserted from the left side of the patient through the Endo Rescue.

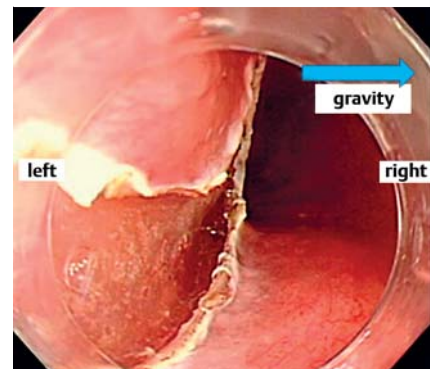


Fig. 4 Water and blood moved to right side of the esophagus and endoscopic submucosal dissection was performed under clear view.

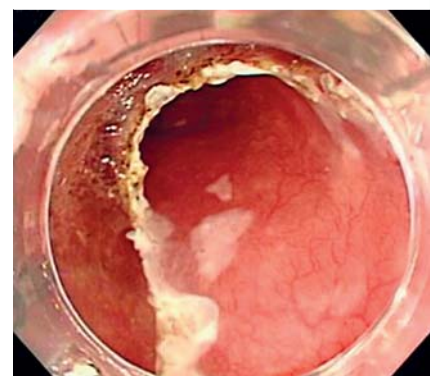

Fig. 5 The procedure time for the dissection of the lesion in the right lateral position was only 15 minutes.

During esophageal endoscopic submucosal dissection (ESD), a left-sided lesion may be affected by the direction of gravity, which causes pooling of water, blood, and tiny resection fragments that obscure the lesion [1]. We used a new inverted endoscopic overtube (Endo Rescue, TOP Co. Tokyo, Japan) to perform esophageal ESD more effectively and safely in left-sided lesions (● Fig. 1).

A 67-year-old man with early esophageal cancer underwent ESD. The lesion was 40 mm in diameter and located mainly in the left side of half of the circumference of the esophagus. The patient was laid in the conventional left lateral position and the esophageal ESD procedure was started. Water and blood pooled over the lesion

(● Fig. 2). Written informed consent had been obtained from the patient and his family to use the Endo Rescue during ESD [2]. The patient was therefore rotated to the right lateral position, and esophageal ESD was restarted using the Endo Rescue (● Fig. 3). Water and blood moved to right side of the esophagus and the lesion was revealed under clear view without water and blood (● Fig. 4; ● Video 1). ESD was easily and safely performed under this clear view and required only 15 minutes (● Fig. 5).

To date, esophagogastroduodenoscopy has been performed with the patient in the left lateral position and the endoscopist standing at the left side of the patient. In contrast, during colonoscopy, the pa-

tient's position is usually rotated according to the best insertion position for the colonoscope based on the direction of gravity [3]. These position changes can

also be used when performing ESD. Endo Rescue enabled the patient's position to be changed so that pooling blood and water would be dislodged by gravity and would not affect the view of the lesion, while allowing the endoscopist to perform the esophageal ESD from the conventional standing position at the left of the patient. Thus, esophageal ESD was performed easily, safely and quickly.

Video 1

By rotating the patient to the right lateral position, water and blood moved to the right side of the esophagus and endoscopic submucosal dissection was performed under clear view.

Endoscopy_UCTN_Code_TTT_1AO_2AG

Competing interests: None

Hirohito Mori^{1,2}, Hideki Kobara¹, Noriko Nishiyama¹, Shintaro Fujihara¹, Tae Matsunaga¹, Maki Ayaki¹, Tatsuo Yachida¹, Takaaki Tsushimi², Tsutomu Masaki¹

¹ Department of Gastroenterology and Neurology, Kagawa University, Kagawa, Japan

² Department of Gastroenterological Surgery, Ehime Rosai Hospital, Ehime, Japan

References

- 1 Yamamoto H. Endoscopic submucosal dissection of early cancers and large flat adenomas. *Clin Gastroenterol Hepatol* 2005; 3: 74–76
- 2 Mori H, Kobara H, Fujihara S et al. Accurate hemostasis with a new endoscopic overtube for emergency endoscopy. *World J Gastroenterol* 2013; 19: 2723–2726
- 3 Stock C, Hoffmeister M, Birkner B et al. Performance of additional colonoscopies and yield of neoplasms within 3 years after screening colonoscopy: a historical cohort study. *Endoscopy* 2013; 45: 537–546

Bibliography

DOI <http://dx.doi.org/10.1055/s-0033-1344874>
 Endoscopy 2014; 46: E88–E89
 © Georg Thieme Verlag KG
 Stuttgart · New York
 ISSN 0013-726X

Corresponding author

Hirohito Mori, MD, PhD

Department of Gastroenterology and Neurology
 Kagawa University
 1750-1 Ikenobe
 Miki, Kita
 Kagawa 761-0793
 Japan
 Fax: +81-87-8912158
 hiro4884@med.kagawa-u.ac.jp