Surgical removal of a severed Dormia basket from the bile duct

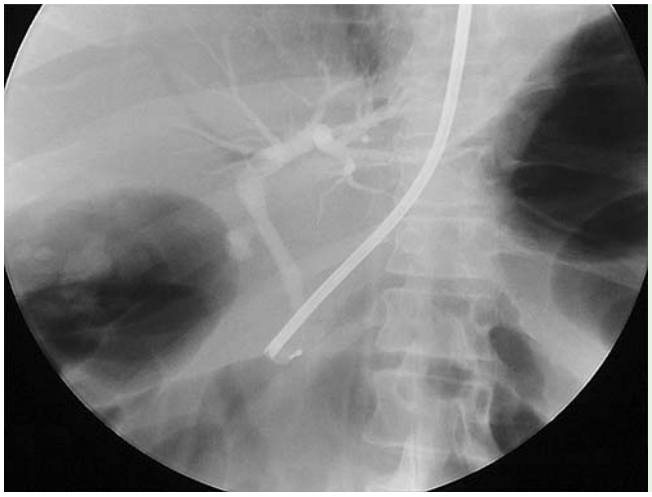

Fig. 1 Advancing a mechanical lithotripsy device over the loops of a Dormia basket, with the intention of fragmenting the entrapped stone. The patient was a 63-year-old man with obstructive jaundice due to cholecysto-choledocholithiasis.

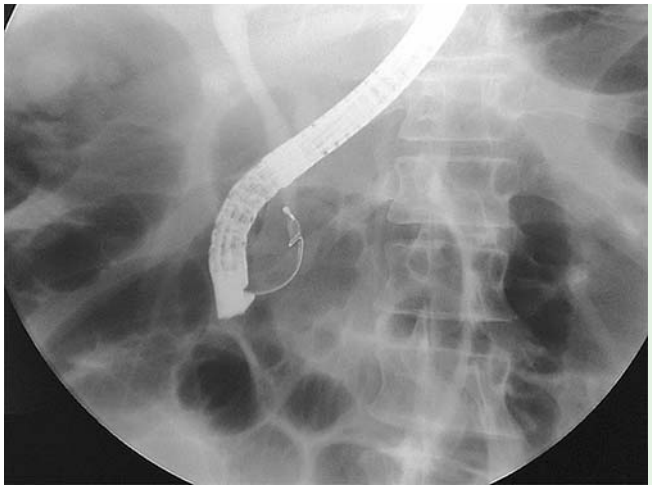

Fig. 2 On application of greater force, the Dormia basket has deformed.

Fig. 3 **a** The severed Dormia basket and the impacted stone. **b** With the additional stone material.

A 63-year-old man, with a body mass index of 32 kg/m^2, was admitted with obstructive jaundice due to cholecysto-choledocholithiasis. He was febrile and had had subcostal pain for at least 3 weeks. Endoscopic retrograde cholangiopancreatography (ERCP) confirmed the presence of stones in the common bile duct (CBD). Papillotomy was carried out and stone retrieval commenced with a Dormia basket. One stone became entrapped in the Dormia basket and it was impossible to remove it through the papilla. A Soehendra mechanical lithotripsy device was advanced over the Dormia basket with the intention of fragmenting the stone. However, the stone did not fracture on application of force (**Fig. 1**). On increase of the level of force applied, the Dormia basket deformed (**Fig. 2**) and eventually fractured, with its tip and the embedded stone remaining in the distal CBD.

Following surgical consultation, open CBD exploration was scheduled. During the procedure, there was evidence of severe and subacute cholecystitis and cholecystectomy was carried out. The area surrounding the bile duct was severely inflamed, and longitudinal choledochotomy was carried out in the supraduodenal portion of the duct. A pair of Randall forceps was advanced distally to retrieve the severed Dormia basket with the embedded stone; additional proximal and distal passes of a biliary Fogarty catheter allowed retrieval of additional stone material (**Fig. 3**). The bile duct was closed with a conventional 14-Fr T-tube (Kehr type). Postoperative serum amylase levels pointed to pancreatitis, as a sequela of the transpapillary manipulation.

When doing lithotripsy using a Dormia basket, care should be taken to keep the wire loops under fluoroscopic control. Stones that are 2 cm in diameter or larger are prone to becoming embedded in the wire loops during removal [1]. In addition, cholecystitis and/or cholangitis may induce inflammatory changes in the CBD, leading to stiffness and deformation of the duct, which reduces the working space between the stone and the wall of the CBD [2]. Once distortion of the Dormia basket, similar to the that described herein (see **Fig. 1**), has occurred, impaction or rupture becomes very likely, and it may be better to consider alternative ways of widening of the papilla or fragmenting the stone. In some cases, use of a second basket or shockwave lithotripsy can help remove or fragment the entrapped stone [3,4], but once the basket be-

This document was downloaded for personal use only. Unauthorized distribution is strictly prohibited.

comes severed, with its opened loops facing downwards, manipulation from below is likely impossible and dangerous, and its removal through open choledochotomy may become mandatory [2].

Endoscopy_UCTN_Code_CPL_1AK_2AC

Competing interests: None

Rudolf García-Gallont, Jose S. Velasquez, W. Duarte

Department of Surgery, Herrera-Llerandi Hospital, Guatemala City, Guatemala

References

1 *Khawaya FI, Ahmad MM*. Basketing a basket. A novel emergency rescue technique. World J Gastrointest Endosc 2012; 4: 429 – 431
2 *Fukino M, Oida T, Kawasaki A* et al. Impaction of a lithotripsy basket during endoscopic lithotomy of a CBD stone. World J Gastroenterol 2010; 16: 2832 – 2834
3 *Sauter G, Sackmann M, Holl J* et al. Dormia baskets impacted in the bile duct: Release by ESWL. Endoscopy 1995; 27: 364 – 367
4 *Schutz SM, Chinea C, Friederichs P*. Successful endoscopic removal of a severed, impacted Dormia basket. Am J Gastroenterol 1997; 92: 679 – 681

Bibliography
DOI http://dx.doi.org/10.1055/s-0033-1344829
Endoscopy 2014; 46: E20–E21
© Georg Thieme Verlag KG Stuttgart · New York
ISSN 0013-726X

Corresponding author
Rudolf García-Gallont
Department of Surgery
Herrera-Llerandi Hospital
6 Ave. 7-55 Zona 10
Guatemala City
Guatemala 01010
garciagallont@hotmail.com

This document was downloaded for personal use only. Unauthorized distribution is strictly prohibited.