Intralymphatic Histiocytosis following Orthopaedic Metal Implant

Intralymphatische Histiozytose nach orthopädischer Metallimplantation

Authors A. Hassan Ibrahim[1,2], S. Pullmann[1], C. Assaf[1], M. Baltaci[1]

Institutions [1] Klinik für Dermatologie und Venerologie, Helios Klinikum Krefeld
[2] Mostafa Kamel Hospital, Alexandria, Egypt

Bibliography
DOI http://dx.doi.org/10.1055/s-0033-1344439
Akt Dermatol 2013; 39: 328–331
© Georg Thieme Verlag KG Stuttgart · New York
ISSN 0340-2541

Corresponding author
Dr. med. Ahmed Hassan Ibrahim
Dermatologist and venerologist
Mostafa Kamel Hospital
Sidi Gaber El Sheikh 1
Alexandria, Egypt
dr_ahmedhassan27@yahoo.com

Abstract

An 80-year-old man presented with a 2-month history of asymptomatic livid brown nodules on his right thigh, where two previous hip operations were done for a hip replacement. Histopathological examination revealed an intensive hyperplasia of lymphatic vessels with a mixed dermal infiltrate composed mainly of lymphocytes, histiocytes and plasma cells. We describe a rare case of intralymphatic histiocytosis, which is a benign process with a chronic course.

Intravascular histiocytosis (IH) is a benign cutaneous condition first reported in 1994 [1]. IH resembles similarities to reactive angioendotheliomatosis, which is first described by Gottron and Nikolowski [2]. In this context IH is thought to be a reactive condition which may be an earlier stage of reactive angioendotheliomatosis [3]. The underlying causes in these disorders include infectious, renal, hepatic and cardiovascular diseases, rheumatoid arthritis and cryoproteinaemia [2]. Histopathologically, they are characterized by the proliferation of histiocytes in the blood or lymphatic vessels [4].

Case report

An 80-year-old man presented with asymptomatic livid brown nodules on his right thigh. The eruption has been present for approximately 2 months and remained unchanged since onset. 2 years previously he got two orthopaedic operations on his right hip due to hip joint related disorders, where a metal implant was inserted. Physical examination revealed multiple asymptomatic 10–20 mm poorly demarcated, erythematous to brown plaques and nodules with a plebbly surface on his inner side of upper right thigh surrounded by purple, livedo-like discoloration (**Fig. 1**).

Fig. 1 Erythematous to brown plaques and nodules with a plebbly surface on his inner side of upper right thigh surrounded by purple, livedo-like discoloration.

The patient has no history of any autoimmune disease. Laboratory test results, including a full blood cell count and serum were within normal ranges with no evidence of underlying coagulopathy. X-chest ray and abdominal ultrasound were normal. Inguinal lymph nodes were not palpable. Clinical differential diagnosis included cutaneous lymphoma, sarcoidosis, dermatofibrosarcoma protuberans, Kaposi sarcoma, angiosarcoma, fungal infection and mycobacterial infection. A skin biopsy was performed. Histopathological examination revealed an intensive hyperplasia of vessels, mainly lymphatics with a mixed dermal infiltrate composed of macrophages, lympocytes and plasma cells (**Fig. 2**, **Fig. 3** and **Fig. 4**). Intravascular thrombi were not observed. The immuno-histochemistry of the vessels was positive for CD31 (**Fig. 5**), CD34 and CD anti-D2–40 antibody (**Fig. 6**) which is specific for lymphatics. Endothelial cells showed no atypia and no increase in the proliferating activity could be observed in Ki 67. Human Herpes Virus 8 (HHV 8), Ziehl-Neelsen stain and Periodic acid-Schiff reagent were negative. Most of the mononuclear

This document was downloaded for personal use only. Unauthorized distribution is strictly prohibited.

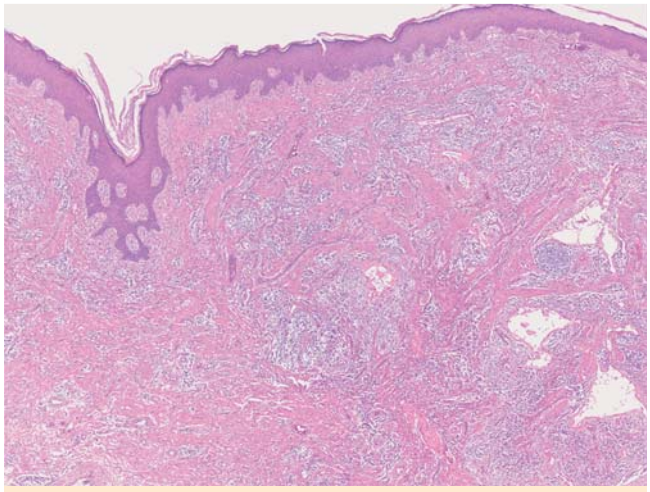

Fig. 2 HE 25×. Dilated vessels in the reticular dermis with a mixed dermal infiltrate composed of macrophages, lympocytes and plasma cells.

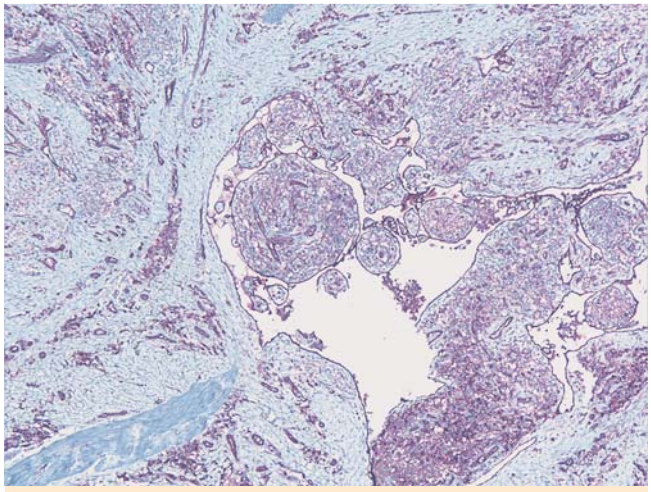

Fig. 5 Endothelial cells and the intraluminal cells are positive for CD31 expression.

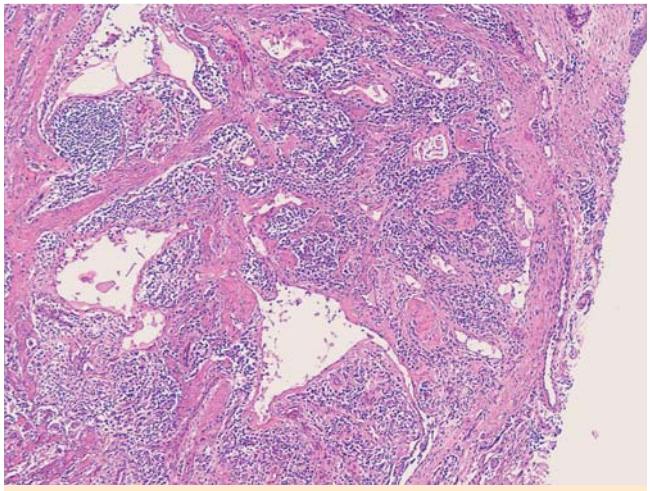

Fig. 3 HE 100×. Intravascular accumulation of macrophages, lympocytes and plasma cells.

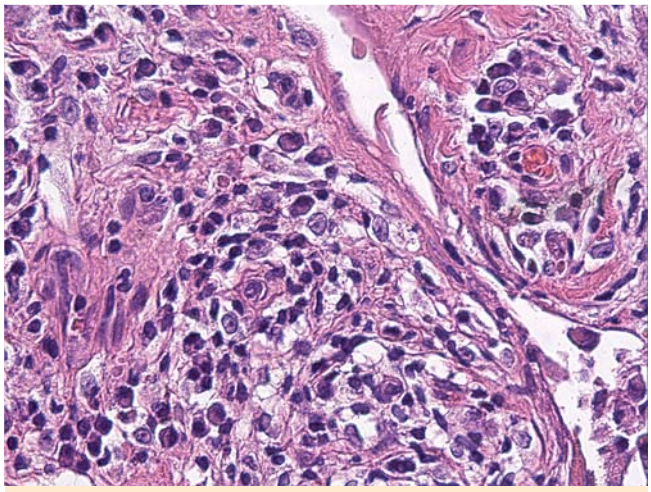

Fig. 6 Endothelial cells decorating dilated vessels are positive for D2–40.

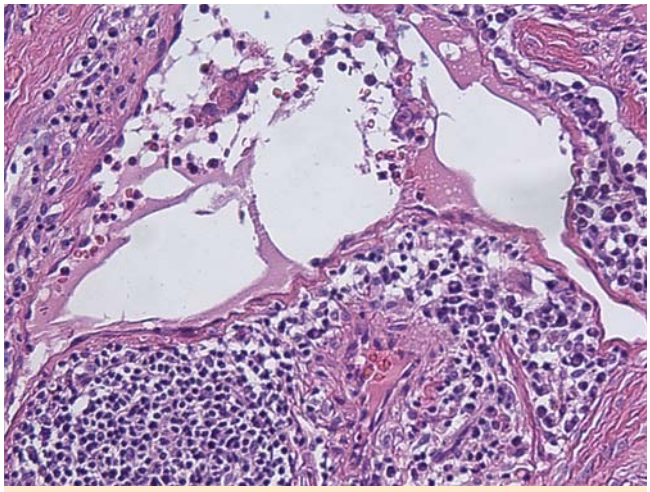

Fig. 4 HE 400×. High power view of the mixed intravascular infiltrate.

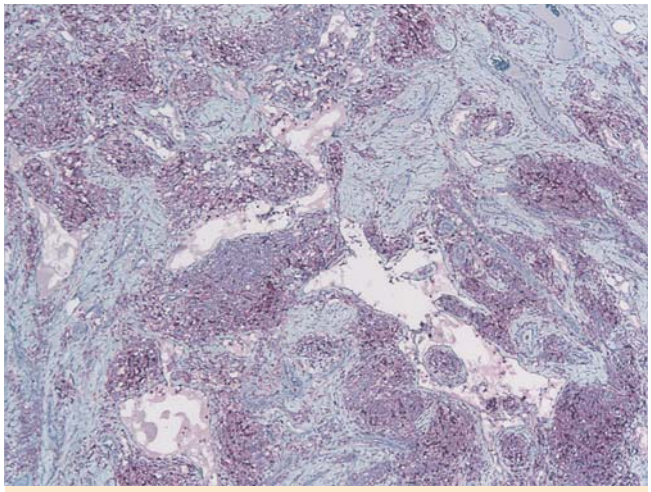

Fig. 7 Immunochemistry showing CD68 positivity of the mononuclear cells in dilated vessels.

This document was downloaded for personal use only. Unauthorized distribution is strictly prohibited.

cells were positive for CD68 (▶ **Fig. 7**), partly for CD3, CD4, CD8, CD79 but negative for CD1a.

Discussion

Cutaneous complications due to orthopaedic metal implants have been reported occasionally [4]. The most common manifestations were eczema and urticaria, while IH was extremely rare with less than 40 cases reported in the literature. IH is a benign disorder first described in 1994 by O'Grady et al. Although most cases of intravascular or IH have been associated with rheumatoid arthritis, some patients showed no evidence of rheumatoid arthritis. Recently, Requena et al. [5] published a series of 34 cases with IH. Of these, 18 patients were afflicted with rheumatoid arthritis, with an additional two patients testing positive for rheumatoid factor [5]. The majority of the reported cases have been seen in women and elderly. Although the clinical lesions are seen near the involved joints, the rash does not match the clinical activity of the patient's rheumatoid arthritis.

To our knowledge, there are hitherto only five cases reported in the literature describing an association with a metal prosthesis [6]. The three cases outlined by Requena's group included two cases of IH that developed overlying a surgical scar following a hip joint replacement with a metal prosthesis, as well as a case associated with an orthopedic metal implant of the left knee. The fourth and the fifth case are reported by Grekin et al. [6] and Watanabe et al. [7]. In all cases, cutaneous lesions have been localized in direct proximity to the affected joints.

Clinically, the typical lesions of IH have been seen overlying or in close proximity to a joint. It presents with erythematous plaques, sometimes with livedo-like pattern, as well as papules, nodules and vesicles [8]. Our patient's rash displayed many of these features, including a livedo-like appearance. The lesions follow a chronic but benign course. They tend to be refractory to topical and systemic treatment [9]. Histopathological findings of IH are characterized by dilated vascular structures in the reticular dermis and by CD68-positive intraluminal histiocytes.

Immunohistochemical studies of the endothelial cells show positivity for CD31, CD34, D2–40. The intravascular histiocytes are positive for CD68 and also for CD31, the latter of which could potentially result in misinterpretation of the lesion as a vascular tumour [10].

The histopathological differential diagnosis of IH includes reactive angioendotheliomatosis (RAE), intravascular lymphoma, metastatic carcinoma, acroangiodermatitis and glomeruloid hemangioma. The principle differential diagnosis in this case was RAE which is also a rare condition that presents as reddish to violaceous patches and plaques. Some examples of RAE have purpuric changes, while other cases have shown blisters, necrosis or ulceration [11]. The lesions show a propensity for the limbs, and constitutional symptoms have been reported in association with the cutaneous findings. Histopathological examination of RAE reveals a proliferation of epithelioid, round or spindle shaped cells within the lumina of dermal blood vessels, which stain positively for CD31 and CD34 [12]. Intravascular thrombi may also be seen. The characteristic features common to both RAE and IH can prove a challenge distinguishing between these entities.

The pathogenesis of IH is unclear and multiple hypotheses have been suggested [13]. Some authors suggest that IH represents an early stage of RAE [3], or occurs as the result of draining histiocytes through the lymphatic vessels from rheumatic joints. Others have postulated that the lesions arise from lymphangiectasia, lymphatic obstruction because of congenital disorders or acquired damage resulting from surgery, trauma, infection or radiation [5]. The common occurrence of IH in association with rheumatoid arthritis suggests that inflammation could be promoting lymphatic stasis, eventuating with lymphangiectasia [5].

In conclusion, IH is a rare condition that occurs most commonly in association with rheumatoid arthritis. There are now six cases of IH that have been reported in association with an underlying metal implant. The association of IH with underlying metal implants suggests a role for lymphatic stasis secondary to chronic inflammation or surgery involving or in proximity to a joint. The pathogenesis of intralymphatic histiocytosis remains to be elucidated.

Conflict of Interest

The authors have no conflict of interest.

Zusammenfassung

Intralymphatische Histiozytose nach orthopädischer Metallimplantation

Ein 80-jähriger Patient stellt sich vor mit seit zwei Monaten bestehenden asymptomatischen livid-braunen Knoten am rechten Oberschenkel dorsal. In diesem Bereich erfolgten zuvor zweimalig Operationen im Rahmen eines Hüftgelenksersatzes. Die histologische Untersuchung zeigte eine ausgeprägte Hyperplasie von Lymphgefäßen begleitet von einem gemischtzelligen Entzündungsinfiltrat bestehend aus Lymphozyten, Histiozyten und Plasmazellen. Dieser seltene Fall ist beschreibend für eine intralymphatische Histiozytose, die eine gutartige Erkrankung mit einem chronischen Verlauf ist.

References

1 *O'Grady JT*, *Shahidullah H*, *Doherty VR* et al. Intravascular histiocytosis. Histopathology 1994; 24: 265
2 *Gottron HA*, *Nikolowski W*. Extrarenale Lohlein-Herdnephritis der Haut bei Endocarditis. Arch Klin Exp Dermatol 1958; 10: 207
3 *Rieger E*, *Soyer HP*, *Leboit PE* et al. Reactive angioendotheliomatosis or intravascular histiocytosis? An immunohistochemical and ultrastructural study in two cases of intravascular histiocytic cell proliferation. Br J Dermatol 1999; 140: 497–504
4 *Rostoker G*, *Robin J*, *Binet O* et al. Dermatitis due to orthopaedic implants. J Bone Joint Surg 1987; 69A: 1408–1412
5 *Requena L*, *El-Shabrawi-Caeken L*, *Walsh SN* et al. Intralymphatic histiocytosis. A clinicopathologic study of 16 cases. Am J Dermatopathol 2009; 31: 140
6 *Grekin S*, *Mesfin M*, *Kang S* et al. Intralymphatic histiocytosis following placement of a metal implant. J Cutan Pathol 2010; 38: 351
7 *Watanabe T*, *Yamada N*, *Yoshida Y* et al. Intralymphatic histiocytosis with granuloma formation associated with orthopaedic metal implants. British Journal of Dermatology 2008; 158: 402
8 *Takiwaki H*, *Aachi A*, *Kohno H* et al. Intravascular or intralymphatic histiocytosis associated with rheumatoid arthritis: a report of 4 cases. J Am Acad Dermatol 2004; 50: 585

This document was downloaded for personal use only. Unauthorized distribution is strictly prohibited.

9 *Catalina-Fernandez I*, *Alvarez AC*, *Martin FC* et al. Cutaneous intralymphatic histiocytosis associated with rheumatoid arthritis: report of a case and review of the literature. Am J Dermatopathol 2007; 29: 165
10 *McKenney JK*, *Weiss SW*, *Folpe AL*. CD31 expression in intratumoral macrophages: a potentially serious diagnostic pitfall. Am J Surg Pathol 2001; 25: 1167
11 *Rongioletti F*, *Rebora A*. Cutaneous reactive angiomatoses: patterns and classification of reactive vascular proliferation. J Am Acad Dermatol 2003; 49: 887
12 *Pouryazdanparast P*, *Yu L*, *Dalton VK* et al. Intravascular histiocytosis presenting with extensive vulvar necrosis. J Cutan Pathol 2009; 36 (Suppl. 01): 1
13 *O'Grady JT*, *Shahidullah H*, *Doherty VR* et al. Intravascular histiocytosis. Histopathology 1994; 24: 265

This document was downloaded for personal use only. Unauthorized distribution is strictly prohibited.