

## Feasibility of endoscopic ultrasound-guided hepaticogastrostomy in a patient with previous gastric banding

Endoscopic ultrasound-guided hepaticogastrostomy (EUS-HGS) was first reported in 2003 [1,2]. However, reported experience with EUS-HGS is still limited, and therefore we describe an interesting case of EUS-HGS in a 53-year-old male with severe obesity and previous gastric banding who presented with advanced Klatskin tumor.

During endoscopic retrograde cholangiopancreatography (ERCP), an uncovered self-expandable metallic stent (USEMS) was placed in order to drain the right bile ducts. Drainage of the left lobe bile ducts failed during ERCP. An external percutaneous transhepatic biliary drain (PTBD) was left in place, after internal-external PTBD placement failed, despite three attempts.

EUS-HGS was not considered as the first-line option because gastric banding, as with any foreign body applied at the level of the cardia, could theoretically prevent EUS-HGS execution, due to the reduction

and distortion of the anatomic window for stent application. In addition, the gastric band itself could interfere with the stent by establishing a valve mechanism and reducing stent patency.

As the external PTBD was consistently draining 300–600 mL/day of clear bile and due to poor patient compliance for a lifetime external drain, EUS-HGS was attempted. A 10-cm half-covered metal stent (Giobor, Niti-S biliary stent; Tae-Woong Medical, Gyeonggi-do, Korea) was successfully placed (▶ **Video 1**). A computed tomography scan performed 2 days

later (▶ **Fig. 1**) showed the USEMS and Giobor in place. There were no complications and therefore the PTBD was removed.

The Giobor was patent for over 4 months and 2 weeks. A USEMS was inserted into the Giobor 134 days after EUS-HGS due to tumor progression.

To our knowledge, there are no reports of EUS-HGS performed in patients with gastric bands. Due to the increasing number of patients undergoing bariatric procedures and subsequently presenting with biliary diseases, we think that the limits of EUS-HGS should be further investigated in this population.

Endoscopy\_UCTN\_Code\_TTT\_1AS\_2AD

**Competing interests:** None

**D. Galasso<sup>1</sup>, E. Bories<sup>2</sup>, F. Caillol<sup>2</sup>, E. A. Forero Pineros<sup>3</sup>, C. Pesenti<sup>2</sup>, M. Giovannini<sup>2</sup>**

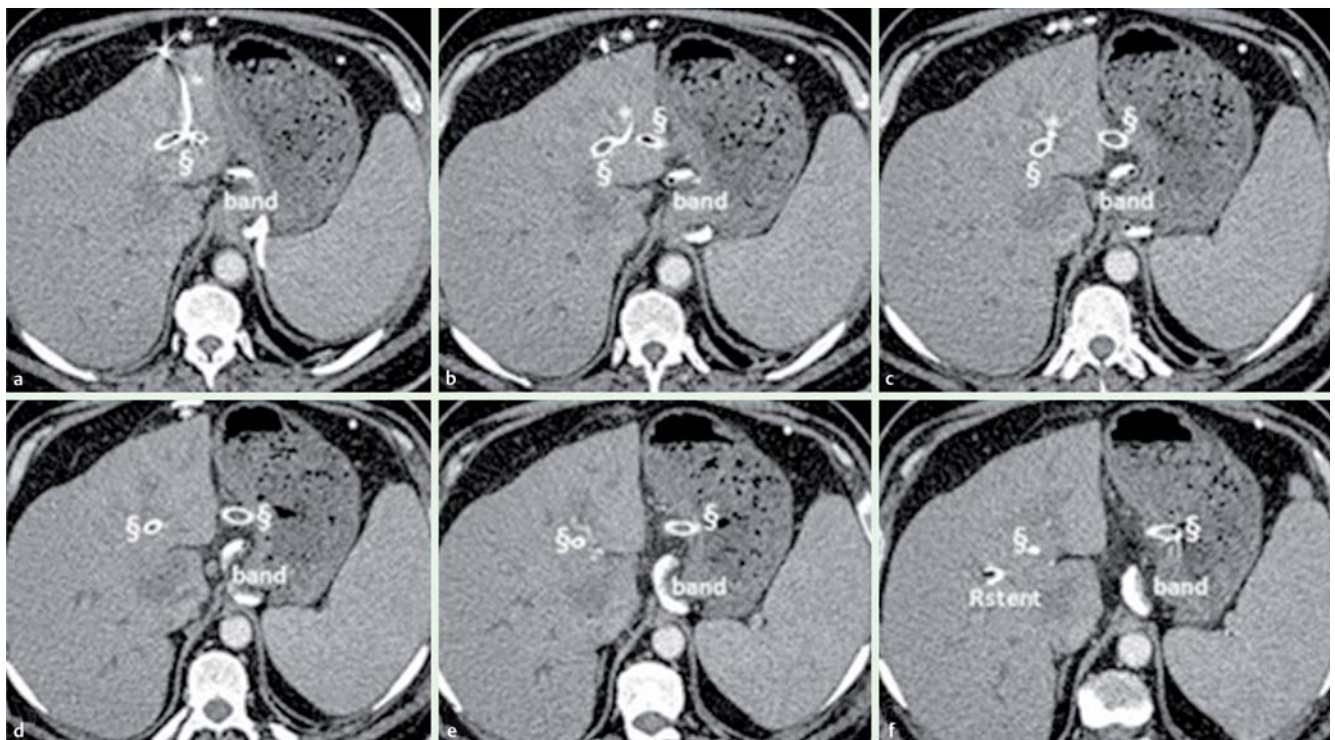
<sup>1</sup> A. Gemelli Hospital, Digestive Endoscopy Unit, Rome, Italy

<sup>2</sup> Paoli Calmette Institute, Endoscopy, Marseille, France

<sup>3</sup> Police Hospital, Gastroenterology, Bogota, Colombia

### Video 1

Hepaticogastrostomy followed by post-procedure computed tomography scan images (showing uncovered self-expandable metallic stent, Giobor Niti-S biliary stent, percutaneous transhepatic biliary drainage, and gastric band in place).



**Fig. 1** Progressive images (from a to f) of a computed tomography scan performed 2 days after the hepaticogastrostomy, showing the percutaneous transhepatic biliary drainage (\*), the hepaticogastrostomy stent (§), the gastric band (band), and the self-expandable metallic stent draining the right bile ducts (Rstent).

## References

- 1 *Burmester E, Niehaus J, Leineweber T et al.* EUS-cholangio-drainage of the bile duct: report of 4 cases. *Gastrointest Endosc* 2003; 57: 246–251
- 2 *Giovannini M, Dotti M, Bories E et al.* Hepaticogastrostomy by echo-endoscopy as a palliative treatment in a patient with metastatic biliary obstruction. *Endoscopy* 2003; 35: 1076–1078

## Bibliography

**DOI** <http://dx.doi.org/10.1055/s-0033-1344322>  
*Endoscopy* 2013; 45: E233–E234  
© Georg Thieme Verlag KG  
Stuttgart · New York  
ISSN 0013-726X

## Corresponding author

**D. Galasso, MD**  
Digestive Endoscopy Unit  
A. Gemelli Hospital  
L.go A. Gemelli 8  
Rome 00168  
Italy  
Fax: +39-06-30156581  
[domenicogalasso512@yahoo.it](mailto:domenicogalasso512@yahoo.it)