

# Vaginal Removal of Very Large Nascent Uterine Myoma – Case Report and Literature Review

## Vaginale Entfernung eines extrem großen Uterusmyoms – Fallbericht und Literaturübersicht

### Authors

M. Terzic<sup>1</sup>, S. Maricic<sup>2</sup>, J. Dotlic<sup>3</sup>

### Affiliations

<sup>1</sup> Clinical Center of Serbia, Clinic of Obstetrics and Gynecology; Department of Obstetrics and Gynecology, Faculty of Medicine, University of Belgrade, Belgrade, Serbia

<sup>2</sup> Occupational Health Department, General Health Center “Savski Venac”, Belgrade, Serbia

<sup>3</sup> Clinical Center of Serbia, Clinic of Obstetrics and Gynecology, Belgrade, Serbia

### Key words

- benign uterine tumor
- nascent myoma
- vaginal myomectomy

### Schlüsselwörter

- benigne Uterustumoren
- entstehendes Myom
- vaginale Myomektomie

received 24.2.2013  
revised 1.4.2013  
accepted 1.5.2013

### Bibliography

DOI <http://dx.doi.org/10.1055/s-0032-1328724>  
Geburtsh Frauenheilk 2013; 73: 724–726 © Georg Thieme Verlag KG Stuttgart · New York · ISSN 0016-5751

### Correspondence

**Prof. Milan M. Terzic, MD, PhD, Ob/Gyn**  
Clinical Center of Serbia, Clinic of Obstetrics and Gynecology  
Department of Obstetrics and Gynecology, Faculty of Medicine  
University of Belgrade  
Belgrade  
Serbia  
terzicmilan@yahoo.co.uk

### Abstract

This report shows that even extremely large nascent uterine myomas can be removed vaginally. A 25-year-old nulligravid and nulliparous patient with malaise, hypermenorrhea, and intermittent cramping pain in the lower abdomen was referred to our clinic. Gynecological examination revealed a round cauliflower-like tumor, 7 cm in diameter, originating from the external cervical os with a rough surface and without a palpable stalk or base. Ultrasound scan showed a hyperechogenic mass within the uterine cavity with two distinct subunits: one (55 × 44 mm) well-demarcated from the surrounding structures and the other (43 × 38 mm) in close proximity to the lower part of the anterior uterine wall and in continuity with the myometrium. At surgery, the myoma was completely removed vaginally. Recovery was prompt, complete, and uneventful. Follow-up at one and three months confirmed normal gynecological and sonographic findings. In conclusion, vaginal myomectomy is the treatment of choice for prolapsed pedunculated submucous myoma; even extremely large nascent myomas can be efficiently removed vaginally.

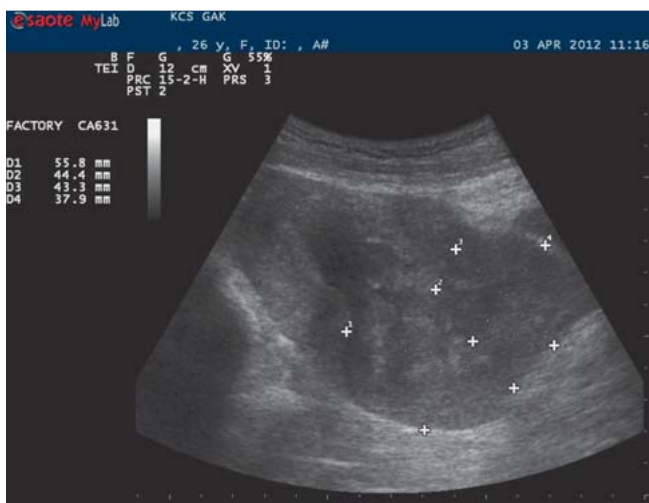### Introduction

Uterine myomas are classified according to their location as subserosal, intramural, submucosal, broad ligament or cervical [1]. Submucosal myomas grow in the inner aspect of the myometrium and project into the uterine cavity. If pedunculated, they may finally protrude through the gradually dilating cervical canal and prolapse into the vagina. Very large myomas can also prolapse into the vagina. The main complication of this condition is necrotic degeneration and infection [1,2]. The subgroup of prolapsed pedunculated sub-

### Zusammenfassung

Die vaginale Entfernung eines riesigen Uterusmyoms wird hier beschrieben. Eine 25-jährige Nullipara/Nulligravida wurde mit folgenden Beschwerden vorstellig: sie fühlte sich nicht wohl, litt unter Hypermenorrhö und leichten krampfartigen Schmerzen im Unterleib. Der gynäkologische Befund ergab einen runden, blumenkohlförmigen Tumor mit einem Durchmesser von 7 cm an der Endozervix. Der Tumor hatte eine grobe Oberfläche und war ohne erkennbaren Stiel oder Basis. Die Ultraschalluntersuchung zeigte eine hyperechogene Masse in der Gebärmutterhöhle, die sich in 2 Partien gliederte: einen klar abgegrenzten Teil (54 × 44 mm) und einen sehr nah am unteren Teil der vorderen Gebärmutterwand gelegenen Teil (43 × 38 mm) mit Verbindung zum Myometrium. Der Tumor wurde chirurgisch vaginal entfernt. Die Genesung war schnell und problemlos. Die gynäkologischen und sonografischen Befunde bei den Kontrolluntersuchungen nach 1 und 3 Monaten waren normal. Fazit: Die vaginale Myomektomie stellt eine mögliche Therapie dar zur Behandlung von submukösen Prolapsmyomen; sie kann aber auch erfolgreich bei riesigen Myomen angewandt werden.

mucous myomas, also known as nascent myomas, represents a separate entity regarding their treatment. They can be removed vaginally because they are usually easily accessible, produce little bleeding and do not require additional dilatation of the cervix [2]. However, large broad-based nascent myomas may bleed heavily and pose a risk for uterine inversion during their removal, and hence may even require a hysterectomy. The aim of this report was to demonstrate that even an extremely large nascent uterine myoma can be completely and successfully removed vaginally.



**Fig. 1** Preoperative ultrasound finding of extremely large intrauterine mass consisting of two components.

## Case Report

A 25-year-old nulligravid and nulliparous patient was referred to our Ob/Gyn Department for malaise, hypermenorrhea, and intermittent cramping pain in the lower abdomen. Six months earlier, she had undergone gynecological examination for the same complaints, but the appropriate diagnosis was not made and she was advised to take progestagens along with iron supplementation. On admission, gynecological examination revealed an extremely large, round, cauliflower-like tumor, 7 cm in diameter, originating from the external cervical os with a rough surface and without a palpable stalk or base. Apart from the enlarged and softened uterus, other gynecological findings were normal. All laboratory analyses (blood, urine, etc.) were within referral ranges. Ultrasound scan confirmed the presence of a hyperechogenic mass within the uterine cavity, well-demarcated from the surrounding structures, except at the anterior uterine wall near to the lower part of the uterus where it was noted to be in continuity with the myometrium. The tumor had two subunits: the first

(55 × 44 mm) was well demarcated, and the second (43 × 38 mm) was in close proximity to the anterior uterine wall (● Fig. 1).

At surgery, both tumor parts were completely removed vaginally (● Fig. 2). After removal, the large and wide tumor base was clearly visualized, divided, clamped, cut, and sutured (● Fig. 3). Pathohistological findings confirmed the presence of a degenerating uterine myoma (connective tissue and proliferating smooth muscle bundles in a whorl-like pattern, with an extensive area of hyalinization and edema).

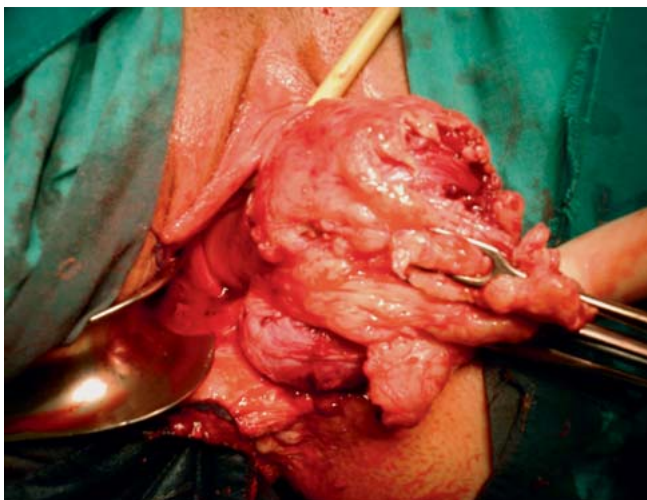
Broad-spectrum antibiotics were administered. The postoperative course was uneventful and the patient was discharged on the second day after surgery. Follow-up was at one and three months after surgery and confirmed normal gynecological and sonographic findings.

## Discussion

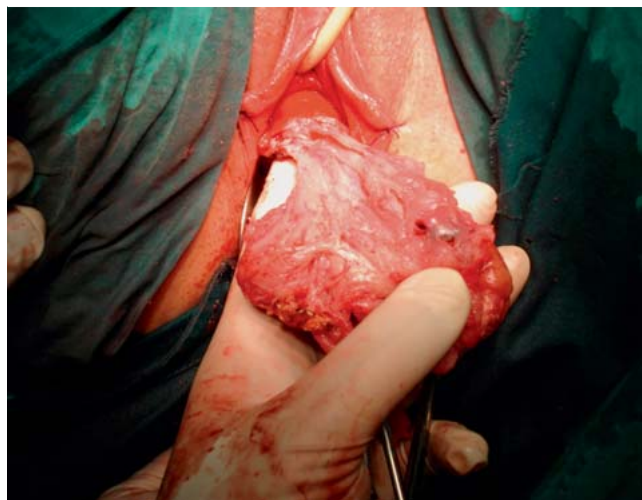
Uterine fibroids (myomas or leiomyomas) are the most common benign, monoclonal, smooth muscle cell tumors of the human uterus. Their etiology is multifactorial, and the incidence ranges from 5 to 77% in women of reproductive age [1].

The majority of women with uterine fibroids are asymptomatic and fibroid tumors therefore often remain undiagnosed. Symptomatic women typically complain of heavy and prolonged bleeding, especially if the myoma is located intramurally or submucosally [2,3]. In addition, women with uterine fibroids may suffer more often from dyspareunia, dysmenorrhea, or non-cyclic pelvic pain and heaviness in the pelvic region with compression of a neighboring organ such as the bladder or rectum [4].

The diagnosis of prolapsed pedunculated myoma is easy once the myoma has protruded through the cervical canal. However, a broad-based endometrial polyp may sometimes be difficult to distinguish from a prolapsed pedunculated submucosal myoma. Moreover, both conditions present with similar symptoms (irregular uterine bleeding) [2]. Although preoperative ultrasonographic examination can be used to assess the position and size of the fibroid to select the best operative procedure, the overall predictive value of ultrasound is unsatisfactory because findings may be confused with those typical of other endometrial tumors (malignant tumors, molar tissue, etc.), especially when the myo-



**Fig. 2** Vaginal extraction of the nascent myoma.



**Fig. 3** Myoma base.

ma has degenerated [5,6]. A recently described new ultrasound marker, referred to as “the bright edge of the polyp”, may be of diagnostic assistance in distinguishing between myomas and polyps [2]. Some authors suggest magnetic resonance imaging (MRI) as the best diagnostic method to determine an intracavitary pathology when precise mapping of tissue is needed [1,5]. Although our patient presented with the usual symptoms, the correct diagnosis was not made until the myoma could be confirmed visually. In this patient, ultrasonography proved to be appropriate and accurate for the evaluation of the myoma's structure.

There are many treatment options for myomas, ranging from surgical to medical options. The choice must depend on the severity of symptoms, the number and size of the leiomyomas, patient age and chronological proximity to menopause, the patient's wish for children, and patient preference [1]. The gold standard to treat symptomatic leiomyoma is surgery. Uterine fibroids are the leading indication for hysterectomies, especially if the uterine size estimated preoperatively is larger than 12 weeks of gestation [4]. Hysterectomy is the definitive surgical operation, but it is unsuitable for women who wish to have children. Different conservative therapeutic options are available for such patients. Although gonadotropin-releasing hormone agonists and medications that manipulate concentrations of steroid hormones are effective, their side effects limit their long-term use, and the formation of new leiomyomas after these conservative therapies remains a substantial problem [1]. Consequently, the best option might be myomectomy. Other recently developed techniques, such as uterine artery embolization (UAE), magnetic resonance-guided focused ultrasound surgery (MRgFUS), and myolysis are emerging as alternative minimally invasive procedures [7]. However, UAE can have serious complications affecting future fertility and its efficacy is limited if fibroids are large. Moreover, UAE is contraindicated if the myoma is submucosal or subserosal and is attached by a pedicle [3].

If the myoma is submucosal, is contained within the uterine cavity and 4 cm in diameter or smaller, then hysteroscopic resection is the preferred technique [3]. However, for larger lesions, hysteroscopy is difficult, especially for submucous myomas with a considerable intramural component, similar to the one described in this report; in these cases hysteroscopy may not be adequate and additional surgical sessions may be necessary for complete resection. Hence, this approach is less attractive [8].

Vaginal myomectomy for symptomatic prolapsed pedunculated submucous myoma is generally a very successful, quick and safe procedure with reduced operating times. Therefore, this approach is recommended as the initial treatment of choice for prolapsed pedunculated submucosal myoma [2]. For large pedunculated submucosal myomas which cannot be extracted in one piece or for which vaginal hysterectomy cannot be performed, some authors have suggested transcervical resection or clamping of a pedicle before surgery to reduce tumor size [9]. As a result, most nascent myomas can be safely extracted vaginally without the need for hysterectomy. The average size of myomas successfully removed vaginally was 50 mm [10]. However, we have

shown here that vaginal extraction of an even larger nascent myoma with a diameter of 7 cm can be done effectively.

After successful vaginal myomectomy, most patients are asymptomatic and menstruate normally [2]. The presented case once again demonstrates that the postoperative course of an adequately performed vaginal myomectomy can be uneventful with a quick recovery time, even if the nascent myoma was very large and broad-based.

## Conclusions

▼ In conclusion, vaginal myomectomy is the treatment of choice for prolapsed pedunculated submucosal myoma, and even an extremely large nascent uterine myoma can be successfully removed vaginally. The vaginal approach for nascent myomas is safe, short, simple, definitive, and, in most cases, causes minimal discomfort to patients.

## Acknowledgements

▼ This work was supported by grant 175062 from the Ministry of Science and Technological Development of the Republic of Serbia.

## Conflict of Interest

▼ None.

## References

- 1 Rice KE, Secrist JR, Woodrow EL et al. Etiology, diagnosis, and management of uterine leiomyomas. *J Midwifery Womens Health* 2012; 57: 241–247
- 2 Golan A, Zachalka N, Lurie S et al. Vaginal removal of prolapsed pedunculated submucous myoma: a short, simple, and definitive procedure with minimal morbidity. *Arch Gynecol Obstet* 2005; 271: 11–13
- 3 Faivre E, Surroca MM, Deffieux X et al. Vaginal myomectomy: literature review. *J Min Inv Gyn* 2010; 17: 154–160
- 4 Zimmermann A, Bernuit D, Gerlinger C et al. Prevalence, symptoms and management of uterine fibroids: an international internet-based survey of 21,746 women. *BMC Womens Health* 2012; 12: 6
- 5 Shiota M, Kotani Y, Umemoto M et al. Estimation of preoperative uterine weight in uterine myoma and uterine adenomyosis. *Asian J Endosc Surg* 2012; 5: 123–125
- 6 Terzic M, Dotlic J, Maricic S et al. Hydatiform mole mimicking enlarged uterine fibromyoma four months after ART. *Cent Eur J Med* 2011; 6: 201–204
- 7 Sabry M, Al-Hendy A. Medical treatment of uterine leiomyoma. *Reproductive Sciences* 2012; 19: 339–353
- 8 Camanni M, Bonino L, Delpiano EM et al. Hysteroscopic management of large symptomatic submucous uterine myomas. *J Minim Invasive Gynecol* 2010; 17: 59–65
- 9 Brito LG, Magnani PS, de Azevedo Trapp AE et al. Giant prolapsed submucous leiomyoma: a surgical challenge for gynecologists. *Clin Exp Obstet Gynecol* 2011; 38: 299–300
- 10 Rolli R, Favilli A, Acanfora MM et al. Vaginal myomectomy is a safe and feasible procedure: a retrospective study of 46 cases. *J Obstet Gynaecol Res* 2012; 38: 1201–1205