

# Small Cell Ovarian Carcinomas – Characterisation of Two Rare Tumor Entities

## Kleinzellige Ovarialkarzinome – Charakterisierung von 2 seltenen Tumorentitäten

### Authors

K. Münstedt, R. Estel, T. Dreyer, A. Kurata, A. Benz

### Affiliation

Frauenklinik, Universitätsklinikum Gießen, Gießen

### Key words

- ovarian cancer
- ovarian tumor
- ovary

### Schlüsselwörter

- Ovarmalignom
- Ovar
- benignes Ovariumtumor

received 20.2.2013  
revised 28.4.2013  
accepted 29.4.2013

### Bibliography

**DOI** <http://dx.doi.org/10.1055/s-0032-1328658>  
Geburtsh Frauenheilk 2013; 73: 698–704 © Georg Thieme Verlag KG Stuttgart · New York · ISSN 0016-5751

### Correspondence

**Prof. Karsten Münstedt**  
Universitätsklinikum Gießen  
Frauenklinik  
Klinikstraße 33  
35435 Gießen  
karsten.muenstedt@gyn.med.uni-giessen.de

### Abstract



**Objective:** Small cell ovarian carcinomas (SCOC) are differentiated into two types: hypercalcaemic (SCOCHT) and pulmonary (SCOCP). Unfortunately, little is known about pulmonary-type small cell ovarian carcinoma.

**Study Design:** We carried out a systematic analysis of all available reports in the literature on individual cases of SCOCHT and SCOCP.

**Results:** We found that patients with SCOCP were significantly older than those with SCOCHT. Vimentin and chromogranin detection by immunohistochemistry allow good differentiation between the two types. Interestingly, SCOCP but not SCOCHT was found to be associated with other benign and malignant ovarian tumours in about 44% of cases. Although the percentage of R0/R1 resections was high (~74%), survival was poor; even in patients with disease limited to the ovaries (stage Ia and Ib) the recurrence rate was 40%. Chemotherapy with etoposide or anthracyclines could be useful.

**Conclusion:** Taking the limitations of our study such as its retrospective nature into account and based on the results from studies of small cell carcinomas originating from other tumour sites, we conclude that treatment of SCOCP should be based on the therapies used to treat other small cell carcinomas. Surgery is appropriate, especially in very early stages of disease, but chemotherapy should not be omitted. Newer concepts such as treatment with somatostatin analogues could help to control symptoms and stabilise some slow-growing tumours.

### Zusammenfassung



**Einleitung:** Es gibt 2 Arten von kleinzelligen Ovarialkarzinomen – die vom hyperkalzämischen (SCOCHT) und die vom pulmonalen Typ (SCOCP). Leider ist wenig über die Karzinome vom pulmonalen Typ bekannt.

**Material und Methode:** Wir führten ein systematisches Review aller zur Verfügung stehenden Fälle aus der Literatur zu beiden Tumorentitäten durch.

**Ergebnisse:** Patientinnen mit SCOCP waren signifikant älter als diejenigen mit SCOCHT. Vimentin- und Chromogranin-Expression in der Immunohistochemie erlaubte eine gute Unterscheidung zwischen beiden Tumorentitäten. Interessanterweise waren Fälle von SCOCP, aber nicht solche mit SCOCHT häufig (44%) assoziiert mit anderen benignen und malignen Ovarialtumoren. Trotz hoher Rate an R0/R1-Resektionen (~74%) war das Überleben der Patientinnen selbst in frühen Tumorstadien (FIGO-Stadium Ia oder Ib) sehr schlecht, und es zeigte sich eine Rezidivrate hier von 40%. Soweit beurteilbar, erschienen Chemotherapien mit Etoposide oder Anthrazyklinen beim pulmonalen Typ sinnvoll.

**Schlussfolgerungen:** Unter Berücksichtigung der Probleme dieses Studienansatzes und im Vergleich zu Studiendaten zu kleinzelligen Tumoren anderer Lokalisationen kann man schließen, dass sich die Behandlung des SCOCP allgemein an den dort gewonnenen Erkenntnissen orientieren sollte. Operationen sind angebracht, insbesondere in den frühen Stadien, aber Chemotherapie darf niemals unterlassen werden. Möglicherweise sind neue Behandlungsansätze wie die Behandlung mit Somatostatin-Analoga geeignet, die Erkrankung und deren Symptomatik positiv zu beeinflussen.

## Key Message box

Small cell ovarian carcinomas of the pulmonary and hypercalcaemic type are two entities with a poor prognosis and may require different treatment concepts than those used for the more common epithelial tumors. Surgery seems to be effective only in the very early stages.

## Abbreviations

SCOCHT small cell ovarian carcinoma of the hypercalcaemic type

SCOCPT small cell ovarian carcinoma of the pulmonary type

## Introduction

Ovarian carcinomas are quite common. Clear treatment guidelines have been established and include radical surgery and combination chemotherapy with paclitaxel, carboplatinum and bevacizumab in the advanced stage of disease. The role of prophylactic surgery in women at risk for familial breast or ovarian cancer has been defined [1].

Small cell ovarian carcinoma (SCOC) is a rare neoplasm divided histologically into the subgroups SCOC of the hypercalcaemic type (SCOCHT; 8041/3) and SCOC of the pulmonary type (SCOCPT; 8041/3) [2]. They comprise about 1% of all ovarian neoplasms and are distinguished by their growth patterns and immunoprofiles. SCOCHT generally stains for epithelial membrane antigens whereas SCOCPT is typically positive for neuron-specific enolase and, in some cases, chromogranin [2]. However, little is known about SCOCPT and there are no specific treatment guidelines for this tumour type although the prognosis is known to be poorer than the prognosis for common epithelial ovarian carcinomas. Primary ovarian small cell carcinomas of the pulmonary type histologically resemble their counterparts in other organs. They are composed of small cells with little cytoplasm and oval to spindle-shaped nuclei [3]. Recently, we characterised all published cases of SCOCHT [4]. This allowed some conclusions to be made on how treatment of this entity could be improved. However, a systematic review and analysis of all reported cases of SCOCPT has not previously been done. The aim of this study was to assess the cases of SCOCPT in the literature and compare the characteristics of this entity with those of SCOCHT.

## Materials and Methods

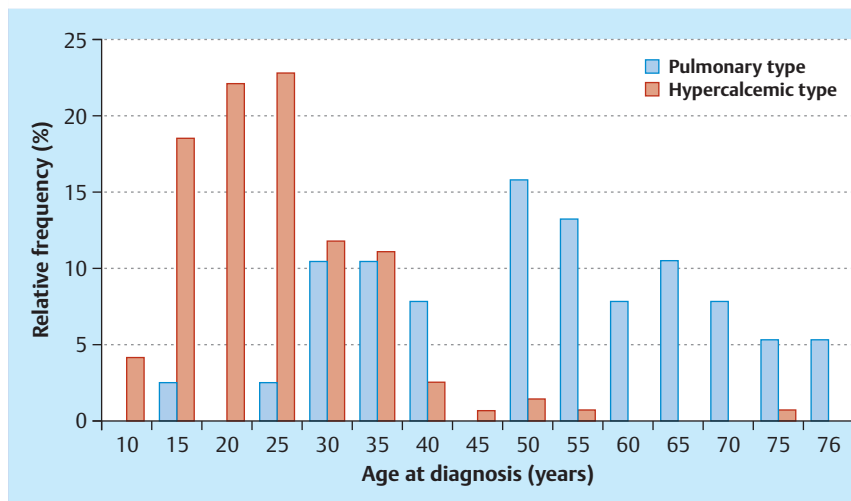
### Search strategy

To identify articles on small cell ovarian carcinoma, we searched Medline and PubMed using the search terms “small cell carcinoma”, “ovary”, “ovarian” and cross-checked the references from retrieved articles. We used the search engine google.de for further investigations.

The search covered articles published between February 1975 and July 2012. All articles were evaluated for individualised patient data on clinical presentation, preoperative diagnostics, surgical and adjuvant therapies as well as follow-up data. In addition to papers in English, papers in French, Italian, Polish, Japanese and Korean were evaluated.

**Table 1** Patient characteristics and immunohistochemical expression patterns of SCOCPT and SCOCHT.

Variable	SCOCPT	SCOCHT
<b>Age (years)</b>		
▶ Mean	47.8	22.8
▶ SD	17.1	9.8
<b>Distribution of stage at diagnosis (% [n +/n<sub>total</sub>])</b>		
▶ 1	42.9 (9/21)	46.8 (52/111)
▶ 2	4.8 (1/21)	11.7 (13/111)
▶ 3	47.6 (10/21)	37.8 (42/111)
▶ 4	4.8 (1/21)	3.6 (4/111)
<b>Clinical symptoms at the time of presentation (% [n +/n<sub>total</sub>])</b>		
▶ overall	94.3 (33/35)	97.6 (80/82)
Specific		
▶ nausea and vomiting	60.0 (21/35)	25.6 (21/82)
▶ palpable mass	48.6 (17/35)	10.9 (9/82)
▶ increase in waist circumference	34.3 (12/35)	24.4 (20/82)
▶ lower abdominal pain	22.9 (8/35)	26.8 (22/82)
▶ stomach ache	20.0 (7/35)	45.1 (37/82)
▶ fatigue	20.0 (7/35)	8.5 (7/82)
▶ urinary pain	17.1 (6/35)	7.3 (6/82)
▶ amenorrhoea, spotting	11.4 (4/35)	8.5 (7/82)
▶ acute abdomen	8.6 (3/35)	3.7 (3/82)
▶ back pain	5.7 (2/35)	7.3 (6/82)
▶ constipation	5.7 (2/35)	18.3 (15/82)
▶ weight loss	5.7 (2/35)	17.0 (14/82)
<b>Serum tumour markers at presentation (% [n +/n<sub>total</sub>])</b>		
▶ hypercalcaemia	0.0 (0/11)	67.1 (57/85)
▶ parathormone	not reported	27.3 (3/11)
▶ CA 125	82.4 (14/17)	80.0 (28/35)
▶ CA 153	0.0 (0/1)	0.0 (0/2)
▶ CA 19-9	37.5 (3/8)	25.0 (1/4)
▶ CEA	36.4 (4/11)	0.0 (0/7)
▶ NSE	85.7 (6/7)	not reported
▶ SCC	33.3 (1/3)	not reported
▶ AFP	0.0 (0/7)	0.0 (0/19)
<b>Affected side (% [n +/n<sub>total</sub>])</b>		
▶ left	37.1 (13/35)	35.5 (33/93)
▶ right	31.4 (11/35)	60.2 (56/93)
▶ bilateral	31.4 (11/35)	4.3 (4/93)
<b>Mean tumour size and volume</b>		
▶ size (cm)	13.5 (SD 6.6)	15.2 (SD 4.8)
▶ volume (cm <sup>3</sup> )	1449	2165
<b>Association with other tumours (% [n +/n<sub>total</sub>])</b>		
▶ overall	44.4 (16/36)	1.8%, 2/110
Specific		
▶ endometrioid adenocarcinoma	16.6 (6/36)	–
▶ mucinous carcinoma	8.3 (3/36)	–
▶ benign teratoma	8.3 (3/36)	1.8%, 2/110
▶ Brenner tumours	5.5 (2/36)	–
<b>Expression of tumour characteristics (% [n +/n<sub>total</sub>])</b>		
▶ synaptopodin	68.4% (13/19)	50.0% (5/10)
▶ neuron-specific enolase (NSE)	86.4% (19/22)	80.0% (16/20)
▶ epithelial membrane antigen (EMA)	55.6% (10/18)	78.8% (26/33)
▶ chromogranin	53.3% (15/28)	9.5% (2/21)
▶ vimentin	4.8% (1/21)	93.9% (46/49)
▶ cytokeratin	68.2% (15/22)	87.7% (50/57)



**Fig. 1** Age distribution of patients with SCOCPT and SCOCHT ( $F_{T-Test} = 25.7$ ,  $p < 0.001$ ).

In all, we identified 127 studies which focussed on primary ovarian small cell carcinoma. Papers were excluded if they were about molecular or histological topics ( $n = 25$ ), did not provide sufficient data on individual patients ( $n = 4$ ), or were in a language not included in our research ( $n = 1$ ). Two articles were not accessible by the means available. After excluding these 32 studies, a total of 95 case studies and reports from case series remained with sufficient data on patients (SCOCPT:  $n = 26$ ; SCOCHT:  $n = 69$ ) [5–99].

Eighty-six of these papers were published as case reports (from 1 to 3 patients) (SCOCPT:  $n = 25$ ; SCOCHT:  $n = 61$ ), and 9 consisted of smaller case series (up to 17 patients) (SCOCPT:  $n = 1$ ; SCOCHT:  $n = 8$ ). One of the cases not published in the literature was reported by the Department of Obstetrics and Gynaecology, Hanau Clinics, Germany, in 2009 as a case report by Hrgovic et al. In total, 182 individual cases were available for analysis (SCOCPT:  $n = 38$ ; SCOCHT:  $n = 144$ ).

### Statistical analysis

SPSS software 17.0 (SPSS Inc, Chicago, IL, USA) for Windows® was used for data management and statistical analysis. Actual disease-free survival and overall survival of patients with reported follow-up was estimated using the Kaplan-Meier life-table method. Differences in survival rates were assessed by log-rank test. The Mann-Whitney U-test was used to check for significant differences in quantitative parameters and the chi-square test was used for qualitative variables. Survival time was measured from the date of the initial laparotomy. We compared the data from this analysis to our earlier analysis of small cell ovarian carcinoma of the hypercalcaemic type [3]. A  $p$  value below 0.05 ( $p < 0.05$ ) was regarded as indicating a significant difference. We informed the local ethics committee of the study prior to analysis. The local ethics committee consented to the study on January 15th, 2010 (application number 07/2010).

### Results

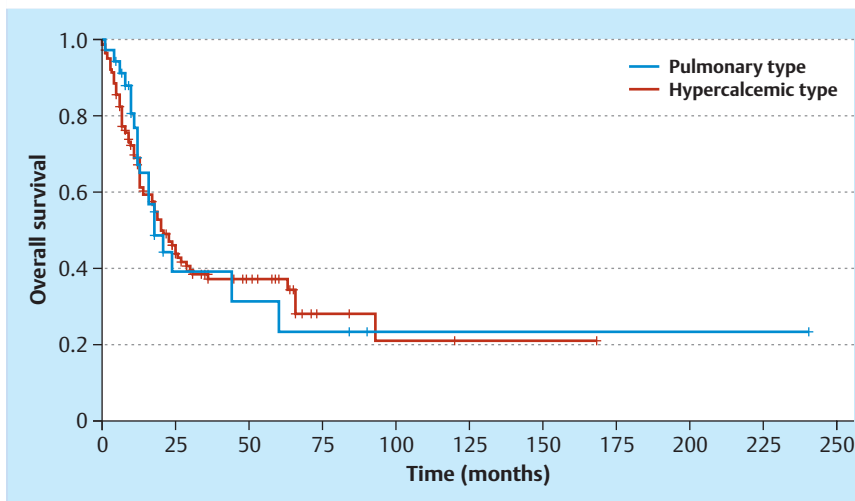
Various characteristics are shown and compared in **Table 1**. Mean age of patients with SCOCPT was significantly higher than that of patients with SCOCHT ( $F_{T-Test} = 25.7$ ,  $p < 0.001$ ). A more detailed age distribution of the two entities is shown in **Fig. 1**.

Most patients with either tumour type had clinical symptoms at the time of presentation. A detailed summary of complaints is given in **Table 1**. Time between onset of symptoms and diagnosis in patients with SCOCPT was 16.1 weeks (SD = 14.8), which was much longer compared to that in SCOCHT (4.9 weeks, SD 4.4;  $F_{T-Test} = 19.1$ ,  $p < 0.001$ ). At diagnosis, several tumour markers were elevated. CA125 was increased in both tumour entities. Neuron-specific enolase (NSE) and carcinoembryonic antigen (CEA) were more frequently elevated in patients with SCOCPT, whereas hypercalcaemia was not found in patients with SCOCPT but frequently in patients with SCOCHT (**Table 1**).

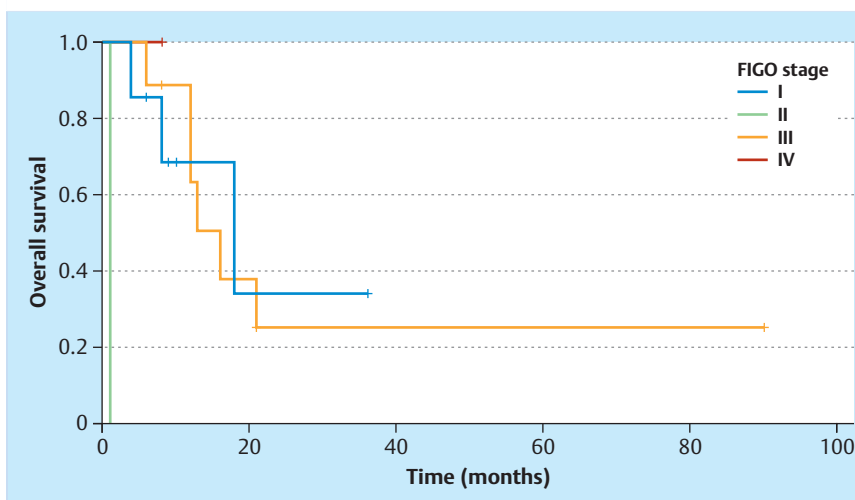
We also found evidence that SCOCHT occurred more frequently as a right-sided unilateral tumour, which was not the case for SCOCPT ( $\chi^2_{Pearson} = 20.0$ ;  $df = 2$ ;  $p < 0.001$ ; **Table 1**). Average tumour size and volume of SCOCPT was significantly lower compared to SCOCHT, however, due to the low numbers this is only significant for size ( $F_{T-Test} = 5.4$ ,  $p = 0.022$ ; **Table 1**). We also found that vimentin and chromogranin were the best parameters to distinguish between tumour types using immunohistochemistry.

Distribution of tumour stages according to the International Federation of Gynecology and Obstetrics (FIGO) classification is also shown in **Table 1**. Prognosis was very poor for both tumour types (**Fig. 2**). Metastases of SCOCPT were found in the omentum ( $n = 8$ ), lymph nodes ( $n = 6$ ), the peritoneum ( $n = 5$ ), intestine ( $n = 5$ ), the liver ( $n = 3$ ), lungs ( $n = 2$ ) and breast ( $n = 2$ ). All but 2 patients (94.7%; 36/38) underwent primary surgery that included bilateral ( $n = 24$ ) and unilateral ( $n = 9$ ) salpingo-ovariectomy, hysterectomy ( $n = 24$ ), omentectomy ( $n = 17$ ), lymphadenectomy ( $n = 14$ ) and bowel surgery ( $n = 2$ ). R0/R1 resection was achieved in 73.9% of the patients (17/23) and R2 resection in 26.1% (6/23). In three cases, additional surgical interventions were required to complete tumour resection; one case required interval debulking surgery and another case required second-look surgery.

FIGO tumour stage proved to be a significant prognostic factor after classifying some cases based on the descriptions (log-rank<sub>SCOCPT</sub> = 18.2;  $df = 3$ ;  $p = 0.0004$ ; log-rank<sub>SCOCHT</sub> = 12.6;  $df = 3$ ;  $p = 0.006$ ). The result of the Kaplan-Meier analysis is shown in **Fig. 3**. Recurrence rates even in patients with disease limited to the ovaries (stage Ia and Ib) were high. Of the 5 patients with SCOCPT staged as FIGO Ia or Ib and followed up, two (40%; 2/5) had recurrence and died of the disease.



**Fig. 2** Comparison of overall survival in patients with SCOCPT and SCOCHT (n.s.).



**Fig. 3** Survival of patients with SCOCPT depending on tumour stage (FIGO; log-rank = 18.2; df = 3; p = 0.0004).

SCOCPT was frequently found to be associated with other ovarian tumours which contrasts with SCOCHT ( $\chi^2_{\text{Pearson}} = 45.6$ ; df = 1;  $p < 0.001$ ). We investigated whether there were differences between “primary” SCOCPT, consisting solely of SCOCPT, and “secondary” SCOCPT, originating from or associated with other tumours. Information on associated tumours was available in 36 cases. We found no differences with respect to the parameters in **Table 1**, except for NSE, which was expressed in all cases of primary SCOCPT (n = 12) but only in 70% (n = 10) of secondary SCOCPT ( $\chi^2 = 4.2$ ;  $p = 0.041$ ). There was a trend for primary SCOCPT to be found more frequently in early FIGO stages I and II (70%; n = 10), whereas 63.6% of secondary SCOCPT were found in the advanced FIGO stages III and IV.

82.4% (28/34) of patients with SCOCPT received additional post-operative chemotherapy, complemented in 2 cases with radiotherapy. Chemotherapeutic regimens mainly consisted of cisplatin or carboplatinum (83.9%; 26/31), etoposide (41.9%; 13/31), alkylating agents (cyclophosphamide or iphosphamide [25.8%; 8/31]), paclitaxel (19.4%; 6/31), anthracyclines (doxorubicin 12.9%, 4/31), bleomycin (12.9%, 4/31), vinca alkaloids (6.5%; 2/31) and irinotecan (6.5%; 2/31). Using Kaplan-Meier analysis, we investigated the possible effect of various therapeutic approaches. We found a trend towards improved survival with the use of etoposide ( $p = 0.123$ ) and anthracyclines ( $p = 0.154$ ).

Radiotherapy and other types of chemotherapy failed to show such effects. Interestingly, the success of surgery as indicated by R0/R1 resection did not prove to be a prognostic factor.

For SCOCHT we showed that administration of etoposide (log-rank = 18.5; df = 1;  $p < 0.001$ ), cisplatin or carboplatinum (log-rank = 5.9; df = 1;  $p = 0.015$ ) or vinca alkaloids (log-rank = 3.9; df = 1;  $p = 0.047$ ) was associated with improved survival.

Recurrence was reported for 60% of patients with SCOCPT (18/30). Most frequently, local recurrence was reported as liver metastasis (n = 8), followed by brain metastasis (n = 7), bone metastasis (n = 5), lung (n = 3) and lymph node metastasis (n = 3). Information on treatment for recurrence was available for 15 patients. Two patients (13.3%) underwent surgery for recurrence, 10 (66.7%) underwent chemotherapy and 9 received radiotherapy (60.0%).

## Discussion



To the best of our knowledge, this is the most comprehensive analysis of SCOCPT to date. SCOCPT is a highly malignant tumour that affects women at a median age of 45 years. It has a poor prognosis even when diagnosed at an early stage. As noted previously by other authors, SCOCPT is frequently associated with oth-



er tumours, which raises the question whether it may have a different pathogenesis [29,93]. Interestingly, we found that radical surgery was not as successful as in the treatment of common epithelial ovarian carcinomas. Moreover, we observed that vimentin and chromogranin allowed a good immunohistochemical distinction between SCOCPT and SCOCHT. Taking the limitations of this study into account (publication and selection bias; the fact that information on prognostic factors was incomplete in many reports or few details on surgical outcomes including residual tumour mass were available), we identified that treatment with etoposide and anthracyclines could be useful. This is very much in line with other reports which showed a beneficial effect of both drugs on small cell cancers originating from areas other than the ovaries [100,101]. Since patients with stage 1 disease have a better survival, surgery appears to be a reasonable option for these patients but not necessarily for patients in more advanced stages [100,101]. In contrast to other epithelial ovarian tumours, additional chemotherapy should not be omitted, even at very early stages. The conclusion is that treatment of SCOCPT should be based on the therapies used to treat other small cell carcinomas. The transfer of findings from other small cell carcinomas originating in other tissues could be useful. For example, it has been noted that somatostatin analogues can control symptoms and stabilise certain slow-growing tumours [102]. Integrating such approaches, perhaps even the use of oncolytic viruses, into the management of SCOCPT could help to improve patients' chances of survival [103].

As shown for SCOCHT, treatment with etoposide, cisplatin or carboplatin and vinca alkaloids may offer some benefits [4]. Again, the poor prognosis for this entity calls the concept of primary surgery in advanced stages of disease into question. Only patients with early stage disease appear to benefit from surgery [4]. Since it is very unlikely that there will be studies of these two rare tumour entities, the authors of case reports of these malignant tumours are requested to include all relevant information as this would allow future investigations to include multifactorial analysis.

## Conflict of Interest

None.

## References

- Rhiem K, Pfeifer K, Schmutzler RK et al. Risk-reducing surgery in women at risk for familial breast or ovarian cancer. *Geburtsh Frauenheilk* 2012; 72: 833–839
- Tavassoli FA, Devilee P, eds. World Health Organization Classification of Tumours. Pathology and Genetics of Tumours of the Breast and Female Genital Organs. Lyon: IARC Press; 2003
- Kupryjańczyk J. Neuroendocrine tumors of the ovary – a review. *Verh Dtsch Ges Pathol* 1997; 81: 253–259
- Estel R, Hackethal A, Kalder M et al. Small cell carcinoma of the ovary of the hypercalcaemic type: an analysis of clinical and prognostic aspects of a rare disease on the basis of cases published in the literature. *Arch Gynecol Obstet* 2011; 284: 1277–1282
- Abeler V, Kjørstad KE, Nesland JM. Small cell carcinoma of the ovary. A report of six cases. *Int J Gynecol Pathol* 1988; 7: 315–329
- Baeyens L, Amat S, Vanden Houste K et al. Small cell carcinoma of the ovary successfully treated with radiotherapy only after surgery: case report. *Eur J Gynaecol Oncol* 2008; 29: 535–537
- Barondeau J, Rodgers M, Braun L et al. Small cell ovarian carcinoma: a rare, aggressive tumor masquerading as constipation in a teenager with a fatal outcome. *J Pediatr Hematol Oncol* 2010; 32: e139–e141
- Benito Reyes V, Martinez Lanao D, Lubrano Rosales A et al. Ovarian small cell carcinoma of hypercalcaemic-type: history of the disease in a patient who refused treatment. *J Obstet Gynaecol* 2011; 31: 354–356
- Benrubi GI, Pitel P, Lammert N. Small cell carcinoma of the ovary with hypercalcaemia responsive to sequencing chemotherapy. *South Med J* 1993; 86: 247–248
- Bertoni F, Ferramosca B, Bacchini P. Small cell ovarian carcinoma with hypercalcaemia: the role of the parathyroid hormone. *G Clin Med* 1983; 64: 564–570
- Blatt J, Van Le L, Weiner T et al. Ovarian carcinoma in an adolescent with transgenerational exposure to diethylstilbestrol. *J Pediatr Hematol Oncol* 2003; 25: 635–636
- Bourgain A, Acker O, Lambaudie E et al. Small cell carcinoma of the ovary of the hypercalcaemic type revealed by a severe acute pancreatitis: about one case. *Gynecol Obstet Fertil* 2005; 33: 35–38
- Brown H, Lane M. Cushing's and malignant carcinoid syndromes from ovarian neoplasm. *Arch Intern Med* 1965; 115: 490–494
- Buono JP, Dechelotte P, Glowaczower E et al. Ploidy analysis in a case of ovarian small cell carcinoma with hypercalcaemia. *Ann Pathol* 1995; 15: 134–137
- Cannon PM, Smart CR, Wilson ML et al. Hypercalcaemia with ovarian granulosa cell carcinoma. *Rocky Mt Med J* 1975; 72: 72–74
- Chakraborty J, Biswas S, Sanyal S et al. Small cell carcinoma of ovary: a rare pathology. *Indian J Pathol Microbiol* 2007; 50: 322–324
- Chan LC, Cheung A, Cheng D. Small cell carcinoma of the ovary associated with *ins(10;5)(p13;q31q13)*. *Cancer Genet Cytogenet* 1994; 77: 89–90
- Chang DH, Hsueh S, Soong YK. Small cell carcinoma with neurosecretory granules arising in an ovarian dermoid cyst. *Gynecol Oncol* 1992; 46: 246–250
- Chen F, Koenig C, Heller DS. A 26-year-old woman with right ovarian mass. Small cell carcinoma of ovary, hypercalcaemic type. *Arch Pathol Lab Med* 2006; 130: e56–e58
- Chen L, Dinh TA, Haque A. Small cell carcinoma of the ovary with hypercalcaemia and ectopic parathyroid hormone production. *Arch Pathol Lab Med* 2005; 129: 531–533
- Cheng Z, Yin H, Du J et al. Bilateral breast metastasis from small-cell carcinoma of the ovary. *J Clin Oncol* 2008; 26: 5129–5130
- Christin A, Lhomme C, Valteau-Couanet D et al. Successful treatment for advanced small cell carcinoma of the ovary. *Pediatr Blood Cancer* 2008; 50: 1276–1277
- Dharan M. Intraoperative cytology of small cell carcinoma of the ovary with hypercalcaemia. A case report. *Acta Cytol* 1993; 37: 61–66
- Di Vagno G, Melilli GA, Cormio G et al. Large-cell variant of small cell carcinoma of the ovary with hypercalcaemia. *Arch Gynecol Obstet* 2000; 264: 157–158
- Dickersin GR, Kline IW, Scully RE. Small cell carcinoma of the ovary with hypercalcaemia: a report of eleven cases. *Cancer* 1982; 49: 188–197
- Distelmaier F, Calaminus G, Harms D et al. Ovarian small cell carcinoma of the hypercalcaemic type in children and adolescents: a prognostically unfavorable but curable disease. *Cancer* 2006; 107: 2298–2306
- Donato G, Conforti F, Zuccala V et al. Large cell variant ovarian small cell carcinoma: case report. *Ultrastruct Pathol* 2008; 32: 206–210
- Dykgraaf RH, de Jong D, van Veen M et al. Clinical management of ovarian small-cell carcinoma of the hypercalcaemic type: a proposal for conservative surgery in an advanced stage of disease. *Int J Gynecol Cancer* 2009; 19: 348–353
- Eichhorn JH, Young RH, Scully RE. Primary ovarian small cell carcinoma of pulmonary type. A clinicopathologic, immunohistologic, and flow cytometric analysis of 11 cases. *Am J Surg Pathol* 1992; 16: 926–938
- Ferrera PC, Whitman MC. Ovarian small cell carcinoma: a rare neoplasm in a 15-year-old female. *Pediatr Emerg Care* 2000; 16: 170–172
- Fignon A, Fétissov F, Calais G et al. Small cell carcinoma of the ovary. A clinical and anatomopathologic entity. *J Gynecol Obstet Biol Reprod (Paris)* 1993; 22: 372–378
- Florell SR, Bruggers CS, Matlak M et al. Ovarian small cell carcinoma of the hypercalcaemic type in a 14 month old: the youngest reported case. *Med Pediatr Oncol* 1999; 32: 304–307
- Forster C, Ostertag H, Schmitt J et al. Small cell carcinoma of the ovary, hypercalcaemic type. A case report with immunohistochemical, ultrastructural and cytophotometric analysis and review of the literature. *Gen Diagn Pathol* 1997; 142: 365–370

- 34 Fukunaga M, Endo Y, Miyazawa Y et al. Small cell neuroendocrine carcinoma of the ovary. *Virchows Arch* 1997; 430: 343–348
- 35 Fukunaga M, Endo Y, Nomura K et al. Small cell carcinoma of the ovary: a case report of large cell variant. *Pathol Int* 1997; 47: 250–255
- 36 Grandjean M, Legrand L, Waterkeyn M et al. Small cell carcinoma of pulmonary type inside a microinvasive mucinous cystadenocarcinoma of the ovary: a case report. *Int J Gynecol Pathol* 2007; 26: 426–431
- 37 Hamilton S, Beattie GJ, Williams AR. Small cell carcinoma of the ovary: a report of three cases and review of the literature. *J Obstet Gynaecol* 2004; 24: 169–172
- 38 Harada H, Kinoshita T, Fujii S et al. Small cell carcinoma arising in post-operative ovary after enucleation for dermoid cysts; a case report. *Jpn J Clin Radiol* 2003; 48: 890–893
- 39 Harrison ML, Hoskins P, du Bois A et al. Small cell of the ovary, hypercalcemic type – analysis of combined experience and recommendation for management. A GCG study. *Gynecol Oncol* 2006; 100: 233–238
- 40 Hirabayashi K, Yasuda M, Osamura RY et al. Ovarian nongestational choriocarcinoma mixed with various epithelial malignancies in association with endometriosis. *Gynecol Oncol* 2006; 102: 111–117
- 41 Holtz G, Johnson Jr. TR, Schrock ME. Paraneoplastic hypercalcemia in ovarian tumors. *Obstet Gynecol* 1979; 54: 483–487
- 42 Idei Y, Kitazawa S, Fujimori T et al. Ovarian small cell carcinoma with K-ras mutation: a case report with genetic analysis. *Hum Pathol* 1996; 27: 77–79
- 43 Ikota H, Kaneko K, Takahashi S et al. Malignant transformation of ovarian mature cystic teratoma with a predominant pulmonary type small cell carcinoma component. *Pathol Int* 2012; 62: 276–280
- 44 Inadome Y, Shibata T, Suzuki K et al. Hypercalcemic-type ovarian small cell carcinoma with unique CD34 expression. *Pathol Int* 2009; 59: 766–768
- 45 Isonishi S, Nishii H, Saitou M et al. Small cell carcinoma of the ovary: clinical and biological study. *Int J Clin Oncol* 2008; 13: 161–165
- 46 Kanwar VS, Heath J, Krasner CN et al. Advanced small cell carcinoma of the ovary in a seventeen-year-old female, successfully treated with surgery and multi-agent chemotherapy. *Pediatr Blood Cancer* 2008; 50: 1060–1062
- 47 Kawasaki F, Takai N, Narahara H et al. A rare case of bilateral small cell carcinoma of the ovary diagnosed during pregnancy. *Int J Clin Oncol* 2000; 5: 200–203
- 48 Kedzia H. Small cell carcinoma of the ovary. *Ginekolog Pol* 1994; 65: 146–152
- 49 Kim J, Kim Y, Seong H et al. Primary small cell carcinoma of the ovary and the long-term survival after systemic chemotherapy. *Korean J Med* 2007; 72: 563–567
- 50 Kira N, Takai N, Ishii T et al. Ovarian small cell carcinoma complicated by carcinomatous meningitis. *Rare Tumors* 2012; 4: e26
- 51 Koven BJ, Dollinger MR, Nadel MS. Response to actinomycin D of malignant carcinoid arising in an ovarian teratoma. *Am J Obstet Gynecol* 1968; 101: 267–268
- 52 Krivak T, Alagöz T. Small cell ovarian cancer: A case report and review of the literature. *The Female Patient* 2002; 12: 3–16
- 53 Lamovec J, Bracko M, Cerar O. Familial occurrence of small-cell carcinoma of the ovary. *Arch Pathol Lab Med* 1995; 119: 523–527
- 54 Lee J, Kim H, Son Y et al. Small cell carcinoma of the ovary of pulmonary type: immunohistochemical and ultrastructural study. *A Case Report. 대부종클리닉회지* 1998; 9: 307–311
- 55 Lifschitz-Mercer B, David R, Dharan M et al. Small cell carcinoma of the ovary: an immunohistochemical and ultrastructural study with a review of the literature. *Virchows Arch A Pathol Anat Histopathol* 1992; 421: 263–270
- 56 Lim SC, Choi SJ, Suh CH. A case of small cell carcinoma arising in a mature cystic teratoma of the ovary. *Pathol Int* 1998; 48: 834–839
- 57 Lo Re G, Canzonieri V, Veronesi A et al. Extrapulmonary small cell carcinoma: a single-institution experience and review of the literature. *Ann Oncol* 1994; 5: 909–913
- 58 Longy M, Toulouse C, Mage P et al. Familial cluster of ovarian small cell carcinoma: a new Mendelian entity? *J Med Genet* 1996; 33: 333–335
- 59 Malfetano JH, Degnan E, Florentin R. Para-endocrine hypercalcemia and ovarian small cell carcinoma. *N Y State J Med* 1990; 90: 206–207
- 60 Martinez-Borges AR, Petty JK, Hurt G et al. Familial small cell carcinoma of the ovary. *Pediatr Blood Cancer* 2009; 53: 1334–1336
- 61 McCormick TC, Muffly T, Lu G et al. Aggressive small cell carcinoma of the ovary, hypercalcemic type with hypercalcemia in pregnancy, treated with conservative surgery and chemotherapy. *Int J Gynecol Cancer* 2009; 19: 1339–1341
- 62 McDonald JM, Karabakhtsian RG, Pierce HH et al. Small cell carcinoma of the ovary of hypercalcemic type: a case report. *J Pediatr Surg* 2012; 47: 588–592
- 63 Mebis J, De Raeve H, Baekelandt M et al. Primary ovarian small cell carcinoma of the pulmonary type: a case report and review of the literature. *Eur J Gynaecol Oncol* 2004; 25: 239–241
- 64 Meganck G, Moerman P, De Schrijver D et al. A non-diploid, small cell carcinoma of the ovary of the hypercalcemic type. *Int J Gynecol Cancer* 1998; 8: 430–433
- 65 Montalto SA, Gupta A, Hakmi A et al. Small cell carcinoma of the ovary: hypercalcaemic type. *J Obstet Gynaecol* 2011; 31: 199–200
- 66 Nelsen LL, Muirhead DM, Bell MC. Ovarian small cell carcinoma, hypercalcemic type exhibiting a response to high-dose chemotherapy. *S D Med* 2010; 63: 375–377
- 67 Niimi S, Kiyokawa T, Takakura S et al. Recurrent small cell carcinoma of the ovary treated with docetaxel: A case report. *Int J Gynecol Cancer* 2006; 16: 1944–1946
- 68 Patsner B, Piver MS, Lele SB et al. Small cell carcinoma of the ovary: a rapidly lethal tumor occurring in the young. *Gynecol Oncol* 1985; 22: 233–239
- 69 Peccatori F, Bonazzi C, Lucchini V et al. Primary ovarian small cell carcinoma: four more cases. *Gynecol Oncol* 1993; 49: 95–99
- 70 Powell JL, McAfee RD, McCoy RC et al. Uterine and ovarian conservation in advanced small cell carcinoma of the ovary. *Obstet Gynecol* 1998; 91: 846–848
- 71 Pruett KM, Gordon AN, Estrada R et al. Small-cell carcinoma of the ovary: an aggressive epithelial cancer occurring in young patients. *Gynecol Oncol* 1988; 29: 365–369
- 72 Rana S, Warren BK, Yamada SD. Stage IIIC small cell carcinoma of the ovary: survival with conservative surgery and chemotherapy. *Obstet Gynecol* 2004; 103: 1120–1123
- 73 Rasmussen KL, Jensen ML, Nielsen KM et al. Small cell carcinoma of the ovary diagnosed in early pregnancy. *Acta Obstet Gynecol Scand* 1991; 70: 377–379
- 74 Reckova M, Mego M, Rejlekova K et al. Small-cell carcinoma of the ovary with breast metastases: a case report. *Klin Onkol* 2010; 23: 43–45
- 75 Reed WC. Small cell carcinoma of the ovary with hypercalcemia: report of a case of survival without recurrence 5 years after surgery and chemotherapy. *Gynecol Oncol* 1995; 56: 452–455
- 76 Rosenbaum T, Gartner J, Korholz D et al. Paraneoplastic limbic encephalitis in two teenage girls. *Neuropediatrics* 1998; 29: 159–162
- 77 Rovithi M, Pallis AG, Kalykaki A et al. Small cell ovarian cancer in adolescents: report of two cases and review of the literature. *Case Rep Med* 2011; 2011: 749516
- 78 Rund CR, Fischer EG. Perinuclear dot-like cytokeratin 20 staining in small cell neuroendocrine carcinoma of the ovary (pulmonary-type). *Appl Immunohistochem Mol Morphol* 2006; 14: 244–248
- 79 Saika N, Malhotra P, Khandelwal N et al. Small cell carcinoma of the ovary presenting as bone marrow metastasis: a rare presenting feature. *Indian J Pathol Microbiol* 2005; 48: 402–404
- 80 Saitoh-Sekiguchi M, Nakahara K, Kojimahara T et al. Complete remission of ovarian small cell carcinoma treated with irinotecan and cisplatin: a case report. *Anticancer Res* 2007; 27: 2685–2687
- 81 Schleeff J, Wagner A, Kleita R et al. Small-cell carcinoma of the ovary of the hypercalcemic type in an 8-year-old girl. *Pediatr Surg Int* 1999; 15: 431–434
- 82 Schultz KA, Sencer SF, Messinger Y et al. Pediatric ovarian tumors: a review of 67 cases. *Pediatr Blood Cancer* 2005; 44: 167–173
- 83 Schweiger LM, Hsiang HY. Pathological case of the month. Acute symptomatic hypercalcemia associated with ovarian small cell carcinoma. *Arch Pediatr Adolesc Med* 2002; 156: 83–84
- 84 Selvaggi SM. Small-cell carcinoma of the ovary in peritoneal fluid. *Diagn Cytopathol* 1994; 11: 266–270
- 85 Senekjian EK, Weiser PA, Talerman A et al. Vinblastine, cisplatin, cyclophosphamide, bleomycin, doxorubicin, and etoposide in the treatment of small cell carcinoma of the ovary. *Cancer* 1989; 64: 1183–1187
- 86 Sholler GL, Luks F, Mangray S et al. Advanced small cell carcinoma of the ovary in a pediatric patient with long-term survival and review of the literature. *J Pediatr Hematol Oncol* 2005; 27: 169–172
- 87 Shrimali RK, Correa PD, Reed NS. Dose-dense and dose-intense chemotherapy for small cell ovarian cancer: 2 cases and review of literature. *Med Oncol* 2011; 28: 766–770
- 88 Stephens B, Anthony SP, Han H et al. Molecular characterization of a patient's small cell carcinoma of the ovary of the hypercalcemic type. *J Cancer* 2012; 3: 58–66

- 89 *Sundersingh S, Rajasundaram S, Majhi U.* Bilateral adrenal metastases from bilateral small cell neuroendocrine carcinoma of the ovary. *Indian J Surg* 2003; 65: 373–375
- 90 *Suzuki N, Kameyama K, Hirao T et al.* A case of pulmonary type of ovarian small cell carcinoma. *J Obstet Gynaecol Res* 2007; 33: 203–206
- 91 *Taraszewski R, Rosman PM, Knight CA et al.* Small cell carcinoma of the ovary. *Gynecol Oncol* 1991; 41: 149–151
- 92 *Tewari K, Brewer C, Cappuccini F et al.* Advanced-stage small cell carcinoma of the ovary in pregnancy: long-term survival after surgical debulking and multiagent chemotherapy. *Gynecol Oncol* 1997; 66: 531–534
- 93 *Tsolakidis D, Papanikolaou A, Ktenidis K et al.* Primary ovarian small cell carcinoma of pulmonary type with enlarged paraaortic lymph node masses: a case report and review of the literature. *Eur J Gynaecol Oncol* 2012; 33: 312–315
- 94 *Ulbright TM, Roth LM, Stehman FB et al.* Poorly differentiated (small cell) carcinoma of the ovary in young women: evidence supporting a germ cell origin. *Hum Pathol* 1987; 18: 175–184
- 95 *Walt H, Hornung R, Fink D et al.* Hypercalcemic-type of small cell carcinoma of the ovary: characterization of a new tumor line. *Anticancer Res* 2001; 21: 3253–3259
- 96 *Wynn D, Everett GD, Boothby RA.* Small cell carcinoma of the ovary with hypercalcemia causes severe pancreatitis and altered mental status. *Gynecol Oncol* 2004; 95: 716–718
- 97 *Yi S, Sohn W, Park H et al.* A case of small cell carcinoma of pulmonary type of ovary associated with huge mucinous cystadenocarcinoma. *Korean J Obstet Gynecol* 2008; 51: 777–783
- 98 *Young RH, Goodman A, Penson RT et al.* Case records of the Massachusetts General Hospital. Case 8-2010. A 22-year-old woman with hypercalcemia and a pelvic mass. *N Engl J Med* 2010; 362: 1031–1040
- 99 *Young RH, Oliva E, Scully RE.* Small cell carcinoma of the ovary, hypercalcemic type. A clinicopathological analysis of 150 cases. *Am J Surg Pathol* 1994; 18: 1102–1116
- 100 *Strosberg JR, Coppola D, Klimstra DS et al.* The NANETS consensus guidelines for the diagnosis and management of poorly differentiated (high-grade) extrapulmonary neuroendocrine carcinomas. *Pancreas* 2010; 39: 799–800
- 101 *Hann CL, Rudin CM.* Management of small-cell lung cancer: incremental changes but hope for the future. *Oncology (Williston Park)* 2008; 22: 1486–1492
- 102 *Reidy DL, Tang LH, Saltz LB.* Treatment of advanced disease in patients with well-differentiated neuroendocrine tumors. *Nat Clin Pract Oncol* 2009; 6: 143–152
- 103 *Hartkopf AD, Fehm T, Wallwiener M et al.* Oncolytic viruses to treat ovarian cancer patients – a review of results from clinical trials. *Geburtsh Frauenheilk* 2012; 72: 132–136