

Potential role of endoscopic ultrasound (EUS) in the diagnosis of aortic intramural lesions

A 58-year-old woman complaining of abdominal pain suspicious for pancreatitis was referred to our institution for endoscopic ultrasound (EUS). Physical examination and laboratory tests were unremarkable except for mild elevation of the serum amylase level. EUS revealed hyper-echoic foci in the pancreas, but the most relevant finding was the presence of aortic wall lesions (● Fig. 1). The ascending aorta showed increased crescent-shaped wall thickness with layered structures separated by echolucent zones, and no flow on Doppler ultrasound. Below this lesion, between the abdominal and thoracic aorta, was a septum giving the impression of a double-lumen aorta. Doppler ultrasound revealed absence of flow in one of the lumens during ventricular systole. Acute aortic syndrome with an intramural hematoma (IMH) and aortic dissection was suspected. Computed tomography (CT) confirmed presence of aortic dissection extending from the thorax to the iliac artery bifurcation. However, IMH was not observed.

The acute aortic syndrome includes aortic dissection, IMH, and penetrating atherosclerotic ulcer of the aorta [1]. It results from the progression of atheromatous plaque that has induced injury in the tunica intima and tunica media of the vessel wall. Aortic dissection is a medical emergency with high rates of mortality and appears subsequent to IMH. Clinical presentation varies from a silent disease to severe pain [2]. The condition is diagnosed based on abnormal findings on imaging, sometimes incidentally discovered during radiological imaging procedures [2].

Image modalities for confirming the diagnosis of acute aortic syndrome include CT, magnetic resonance imaging (MRI), transesophageal echocardiography, angiography, and intravascular ultrasound, with sensitivity and specificity varying from 78% to 100% [3–5]. Due to disadvantages and limitations associated with each modality, the diagnosis requires use of multiple imaging modalities. The unusual findings in the present case demonstrate the potential role of EUS in the diagnosis of aortic intramural pathologies.

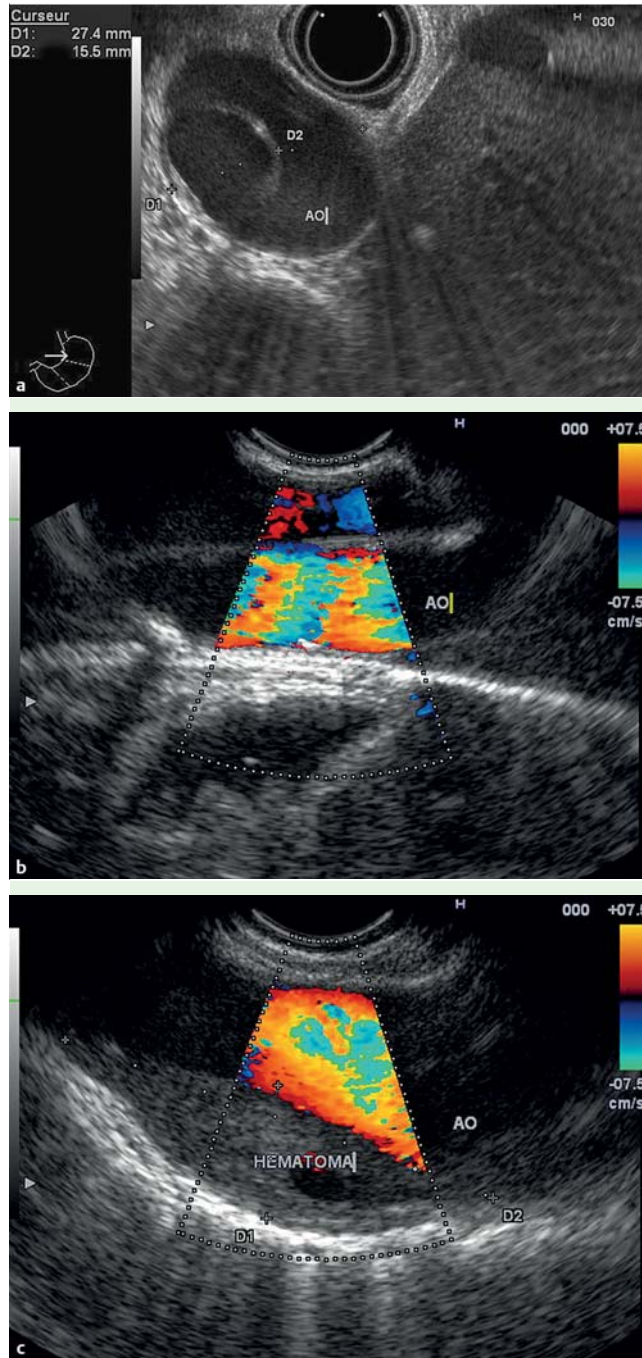


Fig. 1 Endoscopic ultrasound (EUS) findings in a 58-year-old woman complaining of abdominal pain suspicious for pancreatitis. **a** Radial EUS view of the abdominal aorta showing an intraluminal septum mimicking a double-lumen aorta. **b** Linear EUS view of the thoracic aorta showing the intraluminal septum using Doppler color. **c** Linear EUS view of the thoracic aorta showing the intramural hematoma.

Endoscopy_UCTN_Code_CCL_1AF_2AG_3AD

Competing interests: None

C. Robles-Medranda, R. Del Valle, H. Pitanga Lukashok

Instituto Ecuatoriano de Enfermedades Digestivas (IECED), University Hospital Omni, Espiritu Santo University, Guayaquil, Ecuador

References

- 1 *Barnes RW*. Vascular holism: the epidemiology of vascular disease. *Ann Vasc Surg* 1995; 9: 576–582
- 2 *Upadhye S, Schiff K*. Acute aortic syndrome in the emergency department: diagnostic, challenges and evidence-based management. *Emerg Med Clin North Am* 2012; 30: 307–327
- 3 *Thomas T, Nienaber C, Eagle K*. Contemporary reviews in cardiovascular medicine. Acute aortic syndromes. *Circulation* 2005; 112: 3802–3813
- 4 *Zamorano JL, Pérez de Isla L, González R et al*. Diagnostic imaging in acute aortic syndrome. *Rev Esp Cardiol* 2003; 56 (Suppl. 05): 498–508
- 5 *Jacques K, Ramaiah VG, Diethrich EB*. Intra-vascular ultrasound imaging as applied to the aorta: a new tool for the cardiovascular surgeon. *Rev Ann Thoracic Surg* 2008; 86: 1391–1398

Bibliography

DOI <http://dx.doi.org/10.1055/s-0032-1326457>
Endoscopy 2013; 45: E149–E150
© Georg Thieme Verlag KG
Stuttgart · New York
ISSN 0013-726X

Corresponding author

Dr Carlos Robles-Medranda

Instituto Ecuatoriano de Enfermedades Digestivas (IECED)
University Hospital Omni
Av. Abel Romero Castillo Y
Av. Juan Tanca Marengo
S/N Torre Vitalis 1
Oficina Mezanine 1
Ecuador
Fax: +593-42-109180
carlosoakm@yahoo.es