Preliminary clinical experience with high-definition colonoscope illuminated by light-emitting diode

Fig. 1 The prototype high-definition colonoscope illuminated by light-emitting diodes (LEDs). Two packages of white LEDs are attached to the distal end of the colonoscope. The colonoscope has no need of a large light source apparatus and light-guiding fiber bundle. High-definition images and image-enhanced endoscopy using flexible spectral imaging color enhancement are available. CCD, charge-coupled device

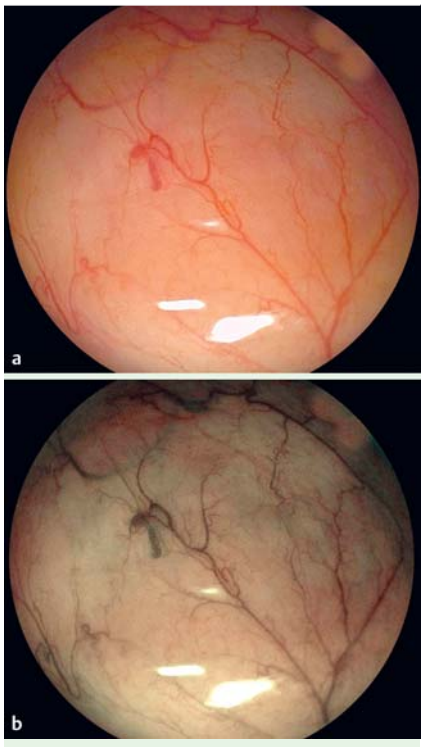

Fig. 2 Colonoscopic images of the high-definition light-emitting diode (LED) colonoscope. **a** Ordinary high-definition LED observation. The luminous intensity is sufficient and the vascular structure of the colorectal mucosa is observed clearly. **b** With flexible spectral imaging color enhancement (525 nm, 495 nm, 495 nm), the fine vascular structure of the colonic mucosa is clear without the use of a magnifying mechanism.

The development of gastrointestinal endoscopes has been closely related to innovations in light sources and observation devices [1]. We anticipated that the light-emitting diode (LED) might be useful for innovation of the gastrointestinal endoscope system and started the development of a test scope with white LEDs on its tip [2, 3]. The LED gastrointestinal endoscope does not need a large light source apparatus or light-guiding fiber bundle. Furthermore, the LED gastrointestinal endoscope system may be manufactured simply at low cost and is relatively independent of a power supply infrastructure.

In cooperation with Fujifilm Corporation (Tokyo, Japan) and Yamaguchi University, our group has developed a high-definition colonoscope that uses white LEDs (**Fig. 1**). Image-enhanced endoscopy (IEE) with flexible spectral imaging color enhancement (FICE) is also possible. For a preliminary evaluation of the image quality of the high-definition LED colonoscope, we performed observations mainly of non-diseased colorectal mucosa in patients with colorectal disease at the National Hospital Organization Kanmon Medical Center. We obtained written informed consent from all patients and the study had the approval of the institutional review board.

From July 2010 to September 2011, we performed 10 sigmoidoscopies and 4 total colonoscopies in 14 patients. The patients were nine women and five men, and their mean age was 66.9 years (range 43–87 years). Four patients had colorectal cancer, nine had previously undergone colorectal polypectomy, and one patient had ulcerative colitis. The study was performed safely without any incident or malfunction of the scope system.

Using the high-definition LED colonoscope, the vascular structure of the colorectal mucosa was observed clearly (**Fig. 2a**). The luminous intensity was sufficient for observation of the colorectal lumen. The light was evenly distributed in the lumen, which may be related to the wide opening of the LED package surface. Used with flexible imaging color enhancement, the fine vascular structure was clearly observed without any magnifying mechanism (**Fig. 2b**).

This preliminary study indicates the potential usefulness of the high-definition LED colonoscope, not only for screening of colon polyps, but also for fine diagnosis of superficial colorectal cancers. The use of scope tip illumination may evoke a major platform innovation of the gastrointestinal endoscope system. This system would also be suitable for mobile hospitals and endoscopy units [4]. The low cost and reduced dependency on electrical power infrastructure of the LED gastrointestinal endoscope system will contribute to worldwide dissemination of high-level gastrointestinal endoscopy and gastrointestinal cancer screening [5].

Endoscopy_UCTN_Code_CCL_1AD_2AJ

Competing interests: None

H. Yanai[1], J. Nishikawa[2], T. Okamoto[2], K. Kikuchi[3], I. Sakaida[2]

[1] Department of Clinical Research, National Hospital Organization Kanmon Medical Center, Shimonoseki, Japan
[2] Department of Gastroenterology and Hepatology, Yamaguchi University Graduate School of Medicine, Ube, Japan
[3] Medical System Business Division, Fujifilm Corporation, Kanagawa, Japan

Acknowledgment

The development cost of the prototype high-definition colonoscope was supported by a grant from the Ministry of Education, Culture, Sports, Science and Technology, Japan.

References

1 *Classen M*. Two centuries of digestive tract endoscopy: a concise report. In: Classen M, Tytgat GNJ, Lightdale CJ, eds. Gastroenterological endoscopy. Stuttgart: Thieme; 2010: 2 – 13

2 *Yanai H*, *Okita K*, *Kikuchi K* et al. Preliminary experience with a gastrointestinal endoscope using a white light-emitting diode. Endoscopy 2006; 38: 290 – 291

3 *Nishikawa J*, *Yanai H*, *Okamoto T* et al. A novel colonoscope with high color-rendering white light-emitting diodes. Gastrointest Endosc 2011; 73: 598 – 602

4 *Talukdar R*, *Reddy DN*. Making endoscopy mobile: a novel initiative for public healthcare. Endoscopy 2012; 44: 186 – 189

5 *Pox CP*, *Altenhofen L*, *Brenner H* et al. Efficacy of a nationwide screening colonoscopy program for colorectal cancer. Gastroenterology 2012; 142: 1460 – 1467

Bibliography

DOI http://dx.doi.org/10.1055/s-0032-1326217
Endoscopy 2013; 45: E1–E2

ISSN 0013-726X

Corresponding author

H. Yanai, MD, PhD
Department of Clinical Research
National Hospital Organization Kanmon Medical Center
1-1 Sotoura, Chofu
Shimonoseki
752-8510, Japan
yanaih@kanmon-mc2.hosp.go.jp