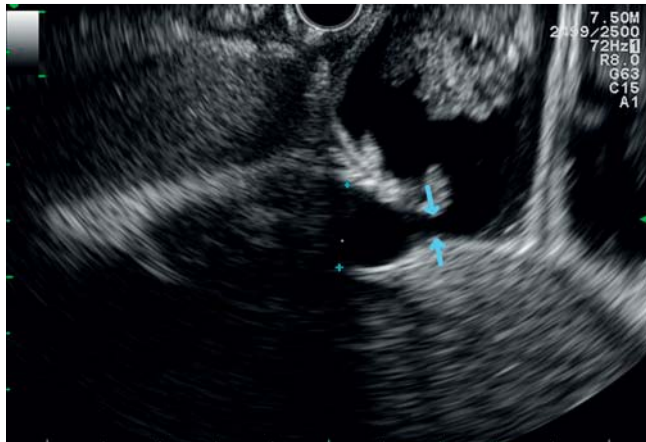
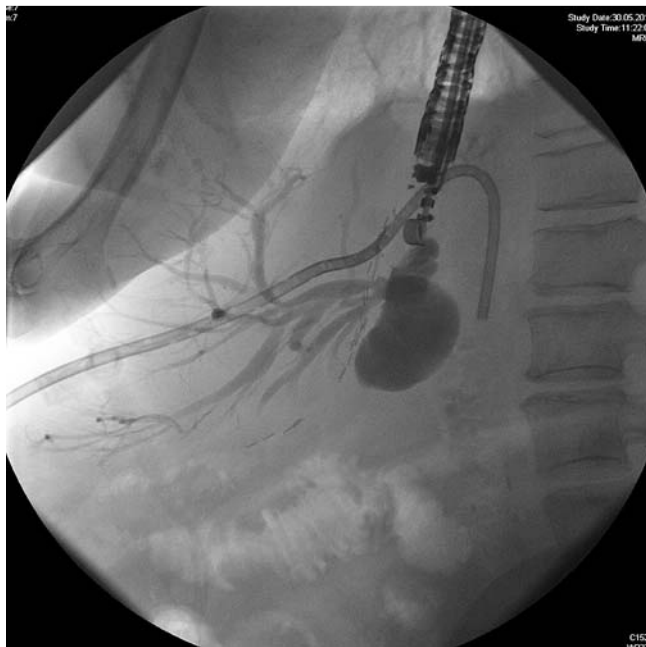

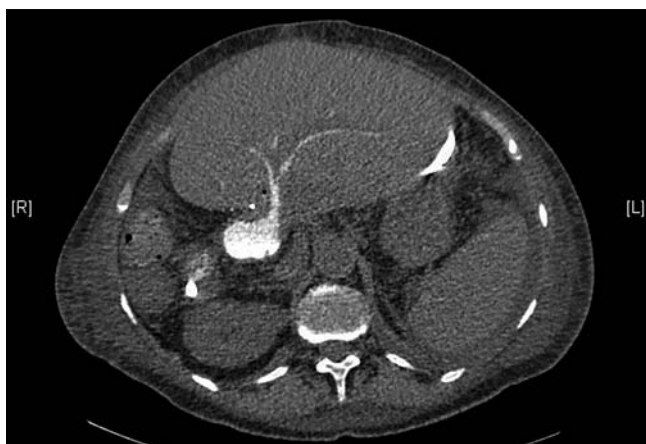## Endoscopic ultrasound (EUS)-guided transduodenal drainage of an obstructed jejunal loop after hepaticojejunostomy as treatment for recurrent biliary sepsis



**Fig. 1** Endoscopic ultrasound (EUS) with transducer in the duodenal bulb in a 70-year-old man having recurrent episodes of biliary sepsis (patient 2). Note the dilated intrahepatic bile duct (15 mm, left between crosses) and efferent jejunal loop (33 mm, right) with open anastomosis (arrows).



**Fig. 2** Fluoroscopy after EUS-guided contrast injection into the efferent loop in a 76-year-old woman with recurrent biliary sepsis showing retrograde filling of the intrahepatic bile ducts and lack of antegrade flow. Note also the additional percutaneous transhepatic drainage in a different liver segment with the tip in the adjacent non-obstructed portion of jejunum.



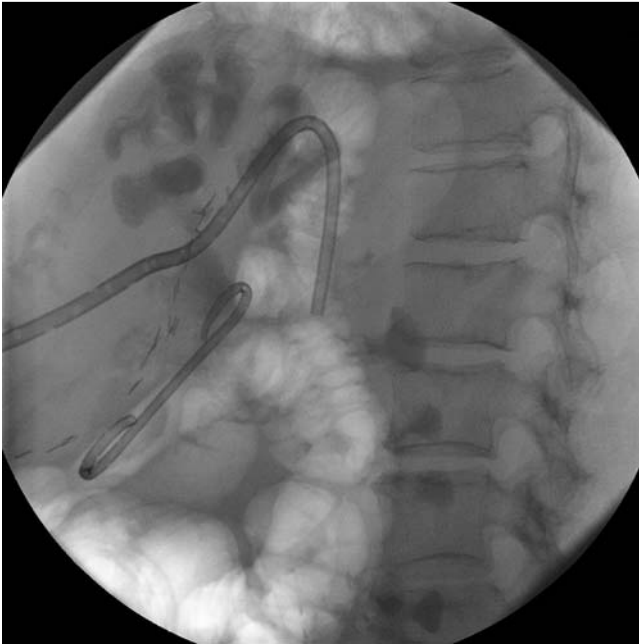**Fig. 3** Computed tomography 1 day after endoscopic ultrasound (EUS)-guided contrast injection in patient 1. The contrast medium is still seen in the efferent jejunal loop.

Hepaticojejunostomy is an established treatment for cholestasis. Complications arise due to obstruction of either the anastomosis or the efferent loop with risk of biliary sepsis. We present a novel approach, transduodenal interventional drainage guided by endoscopic ultrasound (EUS), used in two patients after unsuccessful antibiotic therapy. The first patient was a 76-year-old woman who developed recurrent biliary sepsis (*Escherichia coli*) 4 years after right hepatic trisectorectomy for cholangiocarcinoma with intra- and extrahepatic recurrence 6 months previously. The second patient was a 70-year-old man who also experienced recurrent episodes of biliary sepsis (*Acinetobacter*, *Enterococcus*) 16 months after surgery for cholangiocarcinoma (extended right hemihepatectomy) with peritoneal carcinomatosis 1 year later.

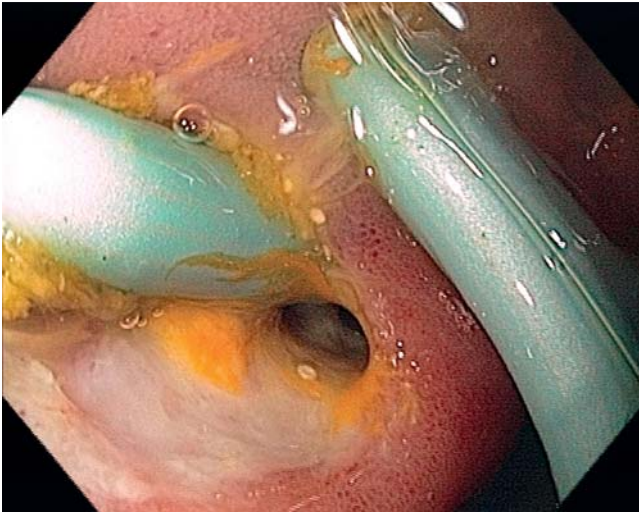
An anastomotic stricture was excluded by endoscopic ultrasound (EUS) in both patients, while the dilated efferent jejunal loop (30 mm and 33 mm [Fig. 1], respectively) showed broad contact with the duodenal bulb. Mechanical obstruction of this loop was confirmed by EUS-guided contrast injection under fluoroscopy (Fig. 2 and Fig. 3) and was followed by transduodenal 10-Fr double pigtail drainage (Fig. 4). This was carried out in a stepwise fashion in patient 1 involving EUS-guided needle puncture (19G; Cook Medical, Limerick, Ireland), insertion of a 0.35-mm guide wire, and dilation with a Soehendra Retriever (Cook Medical, Limerick, Ireland). In patient 2, a single-step procedure utilizing a prototype drainage set (cystostome+double pigtail stent; MTW, Wesel, Germany) was carried out (Fig. 5). Bile flow immediately after the procedure indicated successful treatment and both patients underwent rapid clinical recovery.

By using EUS and EUS-guided contrast injection, we were able to identify obstruction of the efferent jejunal loop as cause of biliary sepsis and subsequently relieve the blockage with EUS-guided jejunal loop drainage. The standard treatment is either percutaneous drainage or surgery. A sophisticated EUS approach that has been previously reported involves insertion of a transesophageal transhepatic metal stent to bridge stenosis of the anastomotic jejunal loop [1]. Our minimally invasive procedure may be helpful in patients with dysfunction of the efferent loop after hepaticojejunostomy.

Endoscopy\_UCTN\_Code\_TTT\_1AS\_2AD



**Fig. 4** Fluoroscopic view after successful placement of the transduodenal double pigtail drainage in patient 1.



**Fig. 5** Endoscopic view of the transduodenal drainage 3 days after placement in patient 2.

**Competing interests:** None

**C. Jürgensen, R. Wentrup, M. Zeitz**

Department of Gastroenterology,  
Charité University Medicine Berlin, Berlin,  
Germany

#### References

- 1 Will U, Meyer F, Schmitt W et al. Endoscopic ultrasound-guided transesophageal cholangiodrainage and consecutive endoscopic transhepatic Wallstent insertion into a jejunal stenosis. *Scand J Gastroenterol* 2007; 42: 412–415

#### Bibliography

**DOI** <http://dx.doi.org/10.1055/s-0032-1325891>  
Endoscopy 2013; 45: E40–E41  
© Georg Thieme Verlag KG  
Stuttgart · New York  
ISSN 0013-726X

#### Corresponding author

**C. Jürgensen**

Charité Universitaetsmedizin Berlin  
Medical Department, Division of Gastroenterology,  
Rheumatology, and Infectious Diseases  
Charitéplatz 1  
10117 Berlin  
Germany  
Fax: +49-30-450514923  
Christian.Juergensen@charite.de