

A novel traction system for esophageal endoscopic submucosal dissection

Recently, endoscopic submucosal dissection (ESD) has been used increasingly in Japan for the treatment of superficial esophageal carcinomas, as it provides a higher en bloc resection rate and lower incidence of recurrence than endoscopic mucosal resection (EMR), regardless of the size and shape of the targeted lesion [1]. However, compared with EMR, ESD is more time-consuming, more technically demanding, and associated with higher rates of complications such as bleeding and perforation [2]. In particular, submucosal dissection rather than the circumferential mucosal incision is challenging, as careful precoagulation of the vessels and adjusting of the depth of dissection are essential to avoid unnecessary bleeding and perforation [3]. We have therefore modified a novel traction system which can lift the submucosal layer to facilitate safer and faster submucosal dissection.

First, using red vinyl tape, we mounted a long straw tube on a commercially available overtube (20 Double Type Slim; TOP, Tokyo, Japan) to create an accessory working channel (● Fig. 1). Next, we modified a biopsy forceps (FB-230K; Olympus, Tokyo, Japan) to be straight when closed and curved when opened (● Fig. 2 and ● Fig. 3). This modified grasping forceps can be inserted in the accessory channel on the overtube to grasp the edge of the targeted lesion during submucosal dissection (● Fig. 4, ● Video 1).

These devices provide better countertraction of the submucosal layer and facilitate safer ESD, as we can visualize the submucosal layer easily and precisely during submucosal dissection. We can also rotate the overtube to grasp different parts of the targeted lesion repeatedly, easily, and effectively if necessary.

This traction system is simple, effective, and ready to use, therefore we have begun conducting a randomized controlled trial in an animal model to evaluate its efficacy.

Video 1

The technique of endoscopic submucosal dissection (ESD) using this new traction system (modified grasping forceps inserted in long straw tube mounted on overtube) in a porcine model.




Fig. 1 A long straw tube is mounted on an overtube with red vinyl tape.




Fig. 2 Biopsy forceps are used as grasping forceps which can be inserted in the long straw tube. The grasping forceps were modified to be straight when closed.




Fig. 3 The grasping forceps were modified to be curved in shape when opened, for grasping the edges of the targeted lesion to be dissected.

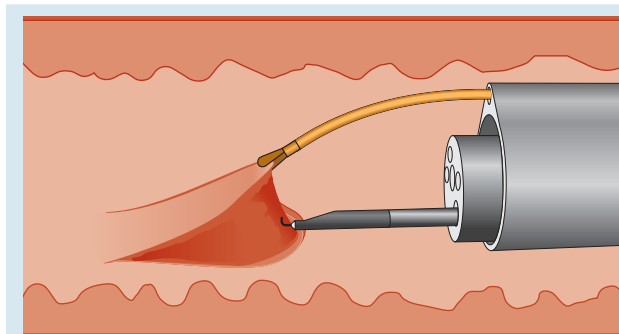


Fig. 4 Schema of esophageal endoscopic submucosal dissection (ESD) using the traction devices (modified grasping forceps inserted in long straw tube mounted on overtube).

Endoscopy_UCTN_Code_TTT_1AO_2AG

Competing interests: None

**K. Ohata¹, K. Fu², M. Shouzushima¹,
J. Hamanaka¹, A. Ono¹, T. Ito¹, Y. Tsuji¹,
H. Chiba³, N. Matsuhashi¹**

¹ Division of Gastroenterology,
NTT Medical Center, Tokyo, Japan

² Department of Gastroenterology,
Juntendo University Nerima Hospital,
Tokyo, Japan

³ Department of Gastroenterology, Omori
Red Cross Hospital, Ota-ku, Japan

References

- 1 *Takahashi H, Arimura Y, Masao H* et al. Endoscopic submucosal dissection is superior to conventional endoscopic resection as a curative treatment for early squamous cell carcinoma of the esophagus (with video). *Gastrointest Endosc* 2010; 72: 255–264
- 2 *Cao Y, Liao C, Tan A* et al. Meta-analysis of endoscopic submucosal dissection versus endoscopic mucosal resection for tumors of the gastrointestinal tract. *Endoscopy* 2009; 41: 751–757
- 3 *Yamamoto S, Uedo N, Ishihara R* et al. Endoscopic submucosal dissection for early gastric cancer performed by supervised residents: assessment of feasibility and learning curve. *Endoscopy* 2009; 41: 923–928

Bibliography

DOI <http://dx.doi.org/10.1055/s-0032-1325735>
Endoscopy 2012; 44: E410–E411
© Georg Thieme Verlag KG
Stuttgart · New York
ISSN 0013-726X

Corresponding author

K. Ohata, MD
Division of Gastroenterology
NTT Medical Center Tokyo
5-9-22 Higashi-gotanda
Shinagawa-ku
Tokyo 141-8625
Japan
Fax: +81-3-34486541
ken.ohata1974@gmail.com