

Guidelines and Good Clinical Practice Recommendations for Contrast Enhanced Ultrasound (CEUS) in the Liver – Update 2012

A WFUMB-EFSUMB Initiative in Cooperation With Representatives of AFSUMB, AIUM, ASUM, FLAUS and ICUS

Authors

M. Claudon^{1*}, C. F. Dietrich^{2*}, B. I. Choi³, D. O. Cosgrove⁴, M. Kudo⁵, C. P. Nolsoe⁶, F. Piscaglia⁷, S. R. Wilson⁸, R. G. Barr⁹, M. C. Chammas¹⁰, N. G. Chaubal¹¹, M.-H. Chen¹², D. A. Clevert¹³, J. M. Correas¹⁴, H. Ding¹⁵, F. Forsberg¹⁶, J. B. Fowlkes¹⁷, R. N. Gibson¹⁸, B. B. Goldberg¹⁹, N. Lassau²⁰, E. L. S. Leen²¹, R. F. Mattrey²², F. Moriyasu²³, L. Solbiati²⁴, H.-P. Weskott²⁵, H.-X. Xu²⁶

Affiliations

Affiliation addresses are listed at the end of the article.

Key words

- diagnosis
- metastases
- hepatocellular carcinoma
- focal nodular hyperplasia
- hemangioma
- microbubble

Abstract

Initially, a set of guidelines for the use of ultrasound contrast agents was published in 2004 dealing only with liver applications. A second edition of the guidelines in 2008 reflected changes in the available contrast agents and updated the guidelines for the liver, as well as implementing some non-liver applications. Time has moved on, and the need for international guidelines on the use of CEUS in the liver has become apparent. The present document describes the third iteration of recommendations for the hepatic use of contrast enhanced ultrasound (CEUS) using contrast specific imaging techniques. This joint WFUMB-EFSUMB initiative has implicated experts from major leading ultrasound societies worldwide. These liver CEUS guidelines are simultaneously published in the official journals of both organizing federations (i.e., *Ultrasound in Medicine and Biology* for WFUMB and *Ultraschall in der Medizin/European Journal of Ultrasound* for EFSUMB). These guidelines and recommendations provide general advice on the use of all currently clinically available ultrasound contrast agents (UCA). They are intended to create standard protocols for the use and administration of UCA in liver applications on an international basis and improve the management of patients worldwide.

Bibliography

DOI <http://dx.doi.org/10.1055/s-0032-1325499>
 Published online: November 5, 2012
Ultraschall in Med 2013; 34: 11–29 © Georg Thieme Verlag KG Stuttgart · New York · ISSN 0172-4614

Correspondence

Prof. Dr. med.
Christoph F. Dietrich
 Caritas Krankenhaus
 Bad Mergentheim,
 Med. Klinik 2
 Uhlandstr. 7
 97980 Bad Mergentheim
 Germany
christoph.dietrich@ckbm.de

Content

| Section | Responsibility |
|--|--|
| Preamble | Michel Claudon Christian P. Nolsoe |
| 1. General considerations (technical aspects) | David O. Cosgrove Barry B. Goldberg |
| 2. CEUS for characterization of focal liver lesions | |
| 2.1. Characterization of FLL in the noncirrhotic liver | Christoph F. Dietrich Fuminori Moriyasu |
| 2.2. Characterization of FLL in the cirrhotic liver | Fabio Piscaglia Masatoshi Kudo |
| 2.3. Characterization of portal vein thrombosis | Stephanie R. Wilson Hong Ding |
| 2.4. CEUS for biopsy planning in cirrhotic and normal livers | Min Hua Chen |
| 3. Detection of malignant FLL: transabdominal approach | Hans-Peter Weskott Byung Ihn Choi |
| 4. Intraoperative contrast enhanced ultrasound | Edward L. S. Leen J. Brian Fowlkes |
| 5. Monitoring ablation treatment | Luígi Solbiati Robert F. Mattrey |
| 6. Liver transplantation | Dirk André Clevert |
| 7. Contrast quantification and monitoring systemic treatment of malignancies | Nathalie Lassau Flemming Forsberg |

List of abbreviations

| | |
|--------|--|
| AASLD | American Association for the Study of Liver Diseases |
| AFSUMB | Asian Federation of Societies for Ultrasound in Medicine and Biology |
| AIUM | American Institute of Ultrasound in Medicine |
| ASUM | Australasian Society for Ultrasound in Medicine |

* Both authors equally contributed to the manuscript (as co-first authors).

| | |
|---------|---|
| AUC | area under the curve |
| AUWI | area under the wash in |
| AUWO | area under the wash out |
| CCC | cholangiocellular carcinoma |
| CT | computed tomography |
| CECT | contrast enhanced computed tomography |
| CEMRI | contrast enhanced magnetic resonance imaging |
| CEUS | contrast enhanced ultrasound |
| DCE-US | dynamic contrast enhanced ultrasound |
| ECC | electrocardiogram |
| EMA | European Medicines Agency |
| EFSUMB | European Federation of Societies for Ultrasound in Medicine and Biology |
| FLAUS | Latin-American Federation of Societies for Ultrasound in Medicine and Biology |
| FLL | focal liver lesion(s) |
| FNH | focal nodular hyperplasia |
| HA | hepatic artery |
| HCA | hepatocellular adenoma |
| HCC | hepatocellular carcinoma |
| ICU | intensive care unit |
| ICUS | International Contrast Ultrasound Society |
| IO-CEUS | intraoperative contrast enhanced ultrasound |
| IOUS | intraoperative ultrasound |
| IVC | inferior vena cava |
| MI | mechanical index |
| MIP | maximum intensity projection |
| MRI | magnetic resonance imaging |
| MTT | mean transit time (TIC parameter) |
| PI | peak intensity |
| PV | portal vein (portal venous) |
| RECIST | response evaluation criteria in solid tumors |
| RF | radio-frequency |
| SPIO | superparamagnetic iron oxide |
| SWI | slope of the wash in (TIC parameter) |
| TIC | time intensity curve(s) |
| TPI | time to peak intensity (TIC parameter) |
| UCA | ultrasound contrast agent(s) |
| US | ultrasound or ultrasonography |
| USA-FDA | United States of America Food and Drug Administration |
| WFUMB | World Federation for Ultrasound in Medicine and Biology |
| WHO | World Health Organization |

Preamble

The present document describes the third iteration of recommendations for the hepatic use of contrast enhanced ultrasound (CEUS) and contrast specific imaging techniques introduced ten years ago in Europe and Canada.

Initially, a set of guidelines for the use of ultrasound contrast agents (UCA) was published in the 2004 edition of *Ultraschall in der Medizin* (European Journal of Ultrasound) dealing only with liver applications [5]. Subsequently, CEUS was introduced into other important guidelines and recommendations for the diagnostic strategy of focal liver lesions (FLL) in cirrhosis, including the guidelines of the American Association for the Study of Liver Diseases (AASLD) 2005 [14], the Asian Pacific Association for the Study of the Liver consensus recommendations on hepatocellular carcinoma (HCC) [111] and the recommendations of the Japan

Society of Hepatology [79]. A second edition of the guidelines in 2008 reflected changes in the available contrast agents and updated the guidelines for the liver [31]. CEUS has also been recommended in guidelines for several non-liver applications, which have recently been updated under the auspices of European Federation of Societies for Ultrasound in Medicine and Biology (EFSUMB) as non-liver guidelines [116].

Time has moved on, and the need for worldwide guidelines on the use of CEUS in the liver has become apparent. World Federation for Ultrasound in Medicine and Biology (WFUMB) and EFSUMB initiated further discussions in 2010, in conjunction with the Asian Federation of Societies for Ultrasound in Medicine and Biology (AFSUMB), American Institute of Ultrasound in Medicine (AIUM), Australasian Society for Ultrasound in Medicine (ASUM) and International Contrast Ultrasound Society (ICUS) to bring the 2008 liver guidelines up-to-date, recognizing the fact that contrast agents are now licensed in many parts of the world, including Australasia, Brazil, Canada, China, Europe, India, Japan and Korea.

This joint WFUMB-EFSUMB venture has resulted in a liver CEUS simultaneous duplicate on liver CEUS in the official journals of WFUMB and EFSUMB (i.e., *Ultrasound in Medicine and Biology* and *Ultraschall in der Medizin/European Journal of Ultrasound*).

To produce the new CEUS liver guidelines and recommendations, a meeting of representatives from 36 European (France, Denmark, Germany, Italy and the UK), North American (Canada and the USA), Asian (China, India, Japan and Korea) and Australian experts was held in Chicago in December 2010. While a significant portion of the work was accomplished at the meeting, the group continued to meet via conference calls and at local meetings.

As before, these guidelines are based on comprehensive literature surveys, including results from prospective clinical trials. On topics where no significant study data were available, evidence was obtained from expert committee reports or was based on the consensus of experts in the field of ultrasound (US) and CEUS during the consensus conferences. During the meeting of experts in Chicago, many additional new developments were discussed and included. Others were believed to be too early in their development to be included in the current recommendations.

These guidelines and recommendations provide general advice on the use of UCA. They are intended to create standard protocols for the use and administration of UCA in liver applications on an international basis and improve the management of patients. Individual cases must be managed on the basis of all clinical data available.

1. General Considerations (Technical Aspects)

1.1. Introduction

The development of microbubble ultrasound contrast agents has overcome some of the limitations of conventional B-mode and Doppler ultrasound techniques for the liver and enabled the display of the parenchymal microvasculature [31]. The enhancement patterns of lesions can be studied during all vascular phases (arterial, portal venous, late and postvascular phases), in a similar fashion to contrast enhanced computed tomography (CECT) and contrast enhanced magnetic resonance imaging (CEMRI) but in real time and under full control of the ultrasound operator. UCA have different pharmacokinetics from commonly used contrast agents for computed tomography (CT) and magnetic resonance imaging (MRI) in that they are confined to the vas-

cular space whereas the majority of contrast agents for CT and MRI are rapidly cleared from the blood pool into the extravascular space [37]. In addition, some UCA have a late or a postvascular phase during which they are retained in the liver (and in the spleen) [37].

An inherent advantage of CEUS is the opportunity to assess the contrast enhancement patterns in real time, with a much higher temporal resolution than is possible with other imaging modalities, so that the enhancement dynamics of lesions can be studied. There is no need to predefine scan time points or to perform bolus tracking. Furthermore, the excellent tolerance and safety profiles of UCA allow for their repeated administrations in the same session when needed. Regrettably, UCA studies are subject to the same limitations as other types of ultrasound imaging: as a general rule, if the baseline ultrasound is suboptimal, CEUS may be disappointing.

There are limitations in the use of CEUS in the liver:

- ▶ Limitations of resolution of CEUS or particular scanning conditions mean that the smallest detectable lesions range between 3 and 5 mm in diameter [92].
- ▶ Very small FLL may be overlooked.
- ▶ Subdiaphragmatic lesions, especially those in segment VIII, may not be accessible to conventional US or CEUS. Intercostal scanning and positioning the patient in the left decubitus position can help reduce this limitation.
- ▶ Since CEUS has limited penetration, especially in steatosis, deep-seated lesions may not be accessible. Again, scanning in the left lateral decubitus position brings the liver forward and closer to the transducer and can help to reduce this limitation; it should be part of the routine survey.
- ▶ The falciform ligament and surrounding fat can cause an enhancement defect that may be confused with a FLL.

1.2. Commercially available UCA for the liver

The UCA currently used in diagnostic US of the liver are microbubbles consisting of gas bubbles stabilized by a shell [31]. Three are in common use today as follows:

- ▶ SonoVue® (sulfur hexafluoride with a phospholipid shell) Bracco SpA, Milan, Italy, introduced in 2001. Licensed in Europe, China, India, Korea, Hong Kong, New Zealand, Singapore and Brazil.
- ▶ Definity®/Luminy® (octafluoropropane [perflutren] with a lipid shell) Lantheus Medical, Billerica, MA, USA, introduced in 2001. Licensed in Canada and Australia.
- ▶ Sonazoid® (perfluorobutane with a phospholipid shell: hydrogenated egg phosphatidyl serine). Daiichi-Sankyo, GE Tokyo, Japan, introduced in 2007. Licensed in Japan and now South Korea.

There are several other UCA which may be useful in liver studies but they are either not licensed for the liver in any country or, in the case of Levovist® (Bayer Schering AG, Germany), production has ceased.

For product information regarding handling, composition, packaging, storage, indications and contraindications of these agents, contact the manufacturing company.

1.3. Background on UCA and contrast specific modes

UCA strongly increase the backscatter of US regardless of whether the microbubbles are flowing or stationary. The low solubility of the gases in currently licensed UCA improves their stability and provides good resonance behavior at low acoustic pressures. This allows minimally disruptive contrast-specific imaging and

enables effective investigation over several minutes to visualize their dynamic enhancement patterns in real time.

Because of their physical size (equal to or smaller than red blood cells), UCA act as blood pool agents and allow depiction of both the macrovasculature and the microvasculature [34]. Despite their varied physicochemical composition, all UCA have similar behaviors for CEUS imaging, rapidly enhancing the vascular pool after intravenous injection, with slow dissipation over about 5 min. An exception to this behavior occurs with Sonazoid®, which has an extended late phase, herein termed the “postvascular phase” in which it persists for several hours in the liver and spleen, long after it has disappeared from the detectable vascular pool. Sonazoid® is phagocytosed by Kupffer cells and this undoubtedly contributes to its persistence in the liver. This postvascular phase is often referred to as “the Kupffer phase” [153].

Contrast-specific US modes cancel the linear US signals from tissue and utilize the nonlinear responses from the microbubbles to form images [31]. This nonlinear microbubble response can be produced by two different mechanisms:

- ▶ Stable nonlinear oscillations at low acoustic pressure, which is nowadays the standard modality for most CEUS examinations.
- ▶ Disruption at higher acoustic pressures to give broadband nonlinear responses.

Nonlinear harmonic US signals also arise from tissue because the sound waves become distorted during their propagation. These “tissues harmonics” increase with increasing acoustic pressure, which is roughly indicated by the mechanical index (MI), (see section 1.8) [7, 132, 138, 140]. However, a low MI is usually chosen for continuous real-time imaging, and for minimizing microbubble destruction. MI is considered as “low” when ≤ 0.3 but most systems work optimally with MI far below 0.3 (as low as 0.05).

Current contrast specific imaging enables effective tissue cancellation to generate almost pure microbubble images. Each manufacturer has developed proprietary techniques for this and adequate cancellation is indicated by near-disappearance of the ultrasound parenchymal liver structures (the screen goes black), though strong reflectors, such as vascular structures and the diaphragm/lung interface, remain barely visible. Correct settings on the ultrasound scanner and the scanning mode are important to avoid artifacts [41]. Inappropriately high MI and gain are the two most common causes of tissue signals being wrongly displayed.

1.4. Intermodality comparison

For characterization of FLL, the enhancement patterns observed during the arterial, portal venous and late phases are generally similar among CEUS, CECT and CEMRI. The real-time nature of US allows depiction of early arterial phase enhancement which is sometimes missed on CT and MRI because they have lower frame rates. Discordance has also been shown in some lesions during the portal venous and late phases when CT and MRI contrast materials diffuse into the tumor interstitium and may conceal wash out [148]. On the other hand, postvascular phase imaging with Sonazoid® shows patterns similar to those described with superparamagnetic iron oxide (SPIO)-MRI [75].

1.5. Equipment and contrast signal detection

See companies' websites for references and specification.

1.6. Clinical practitioner training

Investigators wishing to perform CEUS examinations are recommended to gain experience by observing contrast studies being

performed by experts in this field. EFSUMB has defined three levels of training in its minimal training requirements (EFSUMB 2006) [1] and recommends that CEUS should be performed by operators at a competence level higher than level 1 (EFSUMB 2010: Appendix 14) [3].

They should also ensure that their equipment is optimized for CEUS by discussion with their equipment manufacturer. In addition, a sufficient volume and variety of pathology are essential to acquire and maintain an adequate level of skill. Practitioners need competence in the intravenous administration of contrast agents, familiarity with any contraindications and ability to deal with any possible adverse effects within the medical and legal framework of their country.

1.7. Safety considerations

In general, UCA are safe with a very low incidence of side effects. There are no cardio-, hepato- or nephrotoxic effects. Therefore, it is not necessary to perform laboratory tests to assess liver or kidney function before their administration.

The incidence of severe hypersensitivity events is lower than with current X-ray contrast agents and is comparable to those encountered with MRI contrast agents. Life-threatening anaphylactoid reactions in abdominal applications have been reported with a rate of 0.001%, with no deaths in a series of >23 000 patients [113]. Nonetheless, investigators should be trained in resuscitation and have the appropriate facilities available.

Deaths in critically ill patients who have undergone contrast echocardiography examinations have been reported but with no evidence of a causal relationship [101]. Contraindications for the use of SonoVue® were defined by the European Medicines Agency (EMA) in 2004. In 2007, the United States of America Food and Drug Administration (US-FDA) issued contraindications for the use of Definity® and Optison® (GE Healthcare, licensed for cardiac use) in patients with severe cardiopulmonary disease, and imposed echocardiogram (ECG) monitoring for 30 min after injection (US-FDA Alert 10/2007). The contraindications were downgraded to warnings in May 2008 following review of recent studies on contrast reactions and postmarketing studies supplied by the manufacturers at the request of the FDA [48]; in 2011, the requirement to observe the patient for 30 min after injection was removed. Numerous subsequent studies have been conducted to examine adverse reactions to UCA in cardiac applications [71] and these have indicated an excellent safety profile. One study [81] demonstrated the positive impact of the use of UCA in cardiac examinations: additional procedures were avoided or therapy changed in over 35% of patients. Another large study reported better survival in acute cardiac disorders undergoing UCA administration in comparison to those receiving echocardiography without UCA [102].

Although there is a theoretical possibility that the interaction of diagnostic ultrasound and UCA could produce bioeffects, there is no clinical evidence for adverse effects on the human liver. Cellular effects that have been observed in vitro include sonoporation, hemolysis and cell death [133]. Data from small animal models suggest that microvascular disruption can occur when microbubbles are insonated [133]. Thus, in general, low MI should be preferred for CEUS of the liver. Where diagnostic information can only be obtained using high MI sequences, the benefits vs. the risks of the procedure should be assessed and the mode selected for the benefit of the patient.

There is limited data on the use of UCA in pregnancy, during breastfeeding or in pediatrics [117]. The implied contraindications can be overridden according to clinical judgment and with dedicated informed consent in case of need.

All administration decisions and procedures for the use of UCA should be made with the local regulatory restrictions in mind.

Some general recommendations include:

- ▶ As in all diagnostic ultrasound procedures, the operator should be mindful of the desirability of keeping the displayed MI low and of avoiding unduly long exposure times.
- ▶ Caution should be exercised when using UCA in patients with severe coronary artery disease.
- ▶ As with all contrast agents, resuscitation facilities must be available.
- ▶ The use of UCA should be avoided 24 h prior to extracorporeal shock wave therapy.

1.8. Terminology

The appearance of a lesion or region-of-interest in the liver should be described in terms of the degree and timing (phase) of enhancement.

Degree of enhancement: describing the region in terms of vascularity (e.g., hypervascular, hypovascular) may be incorrect from a histologic point of view and describing the degree of enhancement is preferred.

- ▶ Enhancement refers to the intensity of the signal relative to that of the adjacent parenchyma: either equal to, iso-enhancing; greater than, hyperenhancing; or less than, hypo-enhancing.
- ▶ Sustained enhancement usually refers to continuance of enhancement in the lesion over time.
- ▶ Complete absence of enhancement can be described as non-enhancing. When a region is nonenhancing in the postvascular phase with Sonazoid®, the term “enhancement defect” is often used in clinical practice.

Phase of enhancement

- ▶ The enhancement pattern should be described separately for the different phases, which for the liver comprise the arterial, the portal venous, the late phases and, in case of Sonazoid®, also the postvascular phase. Conventional, but imprecise time points, separate these different phases (see section 2.1.1).
- ▶ “Wash in” used for both qualitative and quantitative analysis, refers to the period of progressive enhancement within a region of interest from the arrival of microbubbles in the field of view to “peak enhancement” and “wash out phase” refers to the period of reduction in enhancement which follows peak enhancement.

Mechanical index

MI refers to the mechanical index of an ultrasound system, which is an estimate of the maximum amplitude of the pressure pulse in tissue, reflecting the power of the system. In very simple terms, higher MI tends to correspond to higher acoustic pressure emission and consequently to more rapid disruption of microbubbles. In physical terms, the MI is defined as:

$$MI = \frac{PNP}{\sqrt{F_c}}$$

where PNP is the peak negative pressure of the ultrasound wave (in MPa and derated for modeled attenuation) and F_c is the center frequency of the ultrasound wave (MHz).

Data types

Different types of data have been used in CEUS studies [138]:

- ▶ RF data refers to the radiofrequency information after the beam former.
- ▶ Raw data refers to the data after the phase information in the RF data has been removed.
- ▶ Linear data refers to the RF or Raw data, before compression.
- ▶ Video data refers to the data after log (or quasi log) compression for video display.

2. CEUS for Characterization of Focal Liver Lesions

CEUS should be performed with knowledge of all prior imaging, the patient's demographics and the clinical history, exactly as for a conventional ultrasound examination. This is particularly important for lesion characterization because the range of tumor types differs between cirrhotic and noncirrhotic livers. Accordingly, in these guidelines the characterization of FLL is described separately for patients with and without cirrhosis.

2.1. Characterization of FLL in the noncirrhotic liver

2.1.1. Background

The dual blood supply of the liver from the hepatic artery (25–30%) and the portal vein (70–75%) gives rise to three overlapping vascular phases on CEUS study (Table 1):

- ▶ The arterial phase provides information on the degree and pattern of the arterial vascular supply. Depending on the individual's circulatory status, the hepatic arterial phase generally starts within 20 s after injection and continues to 30–45 s. This phase may occur very rapidly and the real-time nature of CEUS is needed to capture them, often best seen in a slow replay of a stored cine loop.
- ▶ The portal venous phase usually lasts until 2 min after injection. These two early phases are very similar between the different available UCA (SonoVue®, Definity®, Sonazoid®).
- ▶ The late phase lasts until the clearance of the UCA from the circulation and is limited to 4–6 min.

The additional postvascular (or Kupffer) phase for Sonazoid® begins 10 min after injection and lasts for an hour or more. To ensure that there is no overlap with the late phase, postvascular phase scanning should not be performed sooner than 10 min after injection.

All of these times may be shortened by microbubble disruption if the liver is imaged continuously, even at a low MI.

Late and postvascular phase enhancement provide important information regarding the character of a lesion as most malignant lesions are hypoenhancing while the majority of solid benign lesions are iso- or hyperenhancing [9, 31, 127, 128, 136, 143, 147].

Table 1 Vascular phases in CEUS of the liver (visualization postinjection time).

| phase | start (s) | end (s) |
|--------------------|-----------|--|
| arterial | 10–20 | 30–45 |
| portal venous (PV) | 30–45 | 120 |
| late | > 120 | bubble disappearance (approx. 4–6 min) |

The portal and late phases start at the end of the preceding one. Individual hemodynamic and other factors (e. g., site of injection) may influence their time of onset.

2.1.2. Study procedure

Low MI contrast-specific techniques allow dynamic evaluation of the three vascular phases for all UCA and also of the postvascular phase for Sonazoid®:

- ▶ Any investigation should start with conventional B-mode and Doppler techniques.
- ▶ After identification of the target lesion, the transducer is held still while the scanner is switched to low MI contrast-specific imaging.
- ▶ A dual screen format showing a low MI B-mode image alongside the contrast-only display aids anatomic guidance. This is useful for small lesions to ensure that the target is kept within the field of view during CEUS. A difficulty with the split screen method is that a low MI is used for both panels and this means that the gray scale display is noisy so that smaller and low contrast lesions may be difficult to image. On some scanners, conventional and CEUS images are not split onto two screens but overlaid with different color scales.
- ▶ UCA is administered as a bolus injection followed by a flush of normal saline 0.9%.
- ▶ Ideally, the diameter of the venous line should not be smaller than 20 G to avoid destruction of microbubbles during injection. Central line and port systems can be used as long as there is no filter requiring a high injection pressure but contrast arrival time will be shorter.
- ▶ A stop clock should be started at the time of UCA injection.
- ▶ Because of the dynamic nature of real-time CEUS, essential clips for each vascular phase should be recorded.
- ▶ Assessment of the arterial and portal venous phases should be carried out without interruption. For the late phase, intermittent scanning may be used until the disappearance of the UCA from the liver's microvasculature. Under some circumstances, especially for HCC, the examination may need to be continued for up to 5 min because wash out may be delayed [109].
- ▶ Injection can be repeated when a lesion has been detected in the portal venous phase or in the late/postvascular phase to study the arterial phase and in the case of multiple FLL. Re-injection should be postponed until most microbubbles have vanished and the CEUS screen is almost black again, which can be expected after 6–10 min using SonoVue® and Definity®.

2.1.3. Image interpretation and differentiation of benign from malignant lesions

CEUS can often establish a definitive diagnosis or otherwise facilitate the clinical decision as to whether a sonographically detected liver lesion needs further investigation.

2.1.4. Benign liver lesions

Sustained enhancement in the portal and late phases is typically observed in almost all solid benign liver lesions. They can be further characterized by their enhancement patterns during the arterial phase, (e. g., enhancement of the whole lesion [typical of focal nodular hyperplasia] or initial peripheral globular/nodular enhancement [in hemangiomas]).

The enhancement patterns are summarized in Table 2.

Hemangioma

CEUS has markedly improved the accurate diagnosis of hemangiomas, which is now possible in about 95% of cases [136]. The typical CEUS features of a hemangioma are peripheral nodular enhancement in the arterial phase, progressing in a centripetal

| lesion | arterial phase | portal venous phase | late phase |
|-----------------------------------|---|---|---|
| A. noncirrhotic liver | | | |
| hemangioma | | | |
| typical features | peripheral nodular enhancement | partial/complete centripetal fill in | complete enhancement |
| additional features | small lesion: complete, rapid centripetal enhancement | | nonenhancing regions |
| FNH | | | |
| typical features | hyperenhancing from the center, complete, early | hyperenhancing | iso/hyperenhancing |
| additional features | spoke-wheel arteries feeding artery | unenhanced central scar | unenhanced central scar |
| hepatocellular adenoma | | | |
| typical features | hyperenhancing, complete | isoenhancing | isoenhancing |
| additional features | nonenhancing regions | hyperenhancing nonenhancing regions | slightly hypoenhancing nonenhancing regions |
| focal fatty infiltration | | | |
| typical features | isoenhancing | isoenhancing | isoenhancing |
| focal fatty sparing | | | |
| typical features | isoenhancing | isoenhancing | isoenhancing |
| abscess | | | |
| typical features | peripheral enhancement, no central enhancement | hyper-/isoenhancing rim, no central enhancement | hypoenhancing rim, no central enhancement |
| additional features | | hypoenhancing rim | |
| | enhanced septa | enhanced septa | |
| | hyperenhanced liver segment | hyperenhanced liver segment | |
| simple cyst | | | |
| typical features | nonenhancing | nonenhancing | nonenhancing |
| B. cirrhotic liver | | | |
| regenerative nodule (±dysplastic) | | | |
| typical features (not diagnostic) | isoenhancing | isoenhancing | isoenhancing |
| additional features | hypoenhancing | | |

In cirrhotic liver simple cysts, hemangiomas and abscesses may also be found and show the same enhancement pattern as in noncirrhotic livers. All other entities are rare findings in cirrhotic livers.

direction to partial or complete fill-in. The filling lasts from seconds to minutes and is more rapid in smaller lesions. Enhancement is sustained through the late and postvascular phases. High flow (or shunt) hemangiomas show rapid homogeneous hyperenhancement in the arterial phase and can be confused with focal nodular hyperplasia (FNH), or rarely with hepatocellular adenomas or carcinomas. Thrombosed hemangiomas can be confused with malignancies because of the lack of enhancement in the thrombosed portions, which may be misinterpreted as wash out [43].

Focal nodular hyperplasia

FNH is a benign hepatic lesion that is usually discovered incidentally. It can be managed conservatively in most patients. Color Doppler techniques are helpful to visualize the spoke-wheel vascular pattern which strongly supports the diagnosis of FNH [44, 115] more sensitively shown on CEUS, especially with maximum intensity projection (MIP) technique. On CEUS, FNH typically appears as a hyperenhancing homogeneous lesion in all phases. Hyperenhancement is obvious and usually marked in the arterial phase, with a rapid fill-in from the center outwards (70%) or with an eccentric vascular supply (30%) [44]. During the portal venous and late phases, FNH may remain slightly hyperenhancing or become isoenhancing [115] and a centrally loca-

ted scar may be seen, hypoenhancing in the late phase. In small or deeply located lesions, it can be helpful to switch to color Doppler techniques after the CEUS study and use the remaining circulating microbubbles to enhance the Doppler signals for improved recognition of the typical spoke-wheel vascular pattern. Postvascular phase imaging (Sonazoid®) shows iso- or hyperenhancement [61].

Hepatocellular adenoma

Hepatocellular adenoma (HCA) is a benign estrogen-dependent tumor, which is often discovered incidentally [44]. HCA is an indication for surgery, particularly when larger than 5 cm (risk of hemorrhage and possible malignant transformation). On CEUS, HCA exhibit arterial hyperenhancement, usually initially at the periphery with subsequent very rapid centripetal filling, the opposite direction to that seen in FNH. However, this arterial enhancement pattern can also be encountered in HCC and hyperenhancing metastases and is not pathognomonic of HCA. The transition from the arterial hyperenhancing to the isoenhancing appearance occurs at the beginning of the portal venous phase, usually earlier than in FNH [44, 115]. In most cases, the enhancement patterns of HCA may suggest malignancy when wash out occurs in the late phase, one of the few causes of false positives on CEUS.

Table 2 Enhancement patterns of benign focal liver lesions in the non cirrhotic and cirrhotic liver.

| lesion | arterial phase | portal venous phase | late phase |
|-----------------------|--|--------------------------------------|---|
| A. noncirrhotic liver | | | |
| metastasis | | | |
| typical features | rim-enhancement | hypoenhancing | hypo/nonenhancing |
| additional features | complete enhancement hyperenhancement nonenhancing regions | nonenhancing regions | nonenhancing regions |
| HCC | | | |
| typical features | hyperenhancing | isoenhancing | hypo/nonenhancing |
| additional features | nonenhancing regions | nonenhancing regions | nonenhancing regions |
| cholangiocarcinoma | | | |
| typical features | rim-like hyperenhancement, central hypoenhancement | hypoenhancing | nonenhancing |
| additional features | nonenhancing regions inhomogeneous hyperenhancement | nonenhancing regions | nonenhancing regions |
| B. cirrhotic liver | | | |
| HCC | | | |
| typical features | hyperenhancing, complete nonenhancing areas (if large) | isoenhancing nonenhancing regions | hypoenhancing (slightly or moderately) |
| additional features | basket pattern, chaotic vessels enhancing tumor thrombus | | isoenhancing |
| | hypo/nonenhancing | nonenhancing | nonenhancing |

Table 3 Enhancement patterns of malignant focal liver lesions in the noncirrhotic and cirrhotic liver.

Explanation: Other malignancies in cirrhosis have the same patterns as in noncirrhotic livers.

Focal fatty change

Focal fatty change, either fat infiltration or fatty sparing, may simulate masses on conventional B-mode US. Differential diagnosis is important, especially in patients with underlying malignant disease or with an atypical location of suspected focal fatty changes. Focal fatty change shows exactly the same enhancement patterns as the adjacent liver parenchyma in all phases [62].

Infection

Phlegmonous inflammation has variable and sometimes confusing CEUS appearances, which change as they evolve, early lesions being hyperenhancing, while mature lesions develop hypo-enhancing foci as liquefaction progresses.

Mature abscesses typically show marginal enhancement in the arterial phase, sometimes with enhancement of septae followed by venous hypoenhancement. Lack of enhancement in the liquefied portions is the most prominent feature [19, 20, 95].

The appearances of granulomas and focal tuberculosis on CEUS are variable but the majority show peripheral enhancement in the arterial phase with wash out in the portal and late phases, which may be difficult or impossible to differentiate from malignancies. The clinical history is important and the diagnosis is usually obtained on histopathology or microbiology [18, 95].

Other benign lesions

Active hemorrhage demonstrates contrast extravasation whereas hematomas show no enhancement.

Cysts show no contrast enhancement at all. CEUS is not needed for simple cysts but is useful to evaluate complicated or atypical cysts.

Inflammatory pseudotumor is a rare disease whose definite diagnosis is usually only made at surgery. It may show arterial enhancement and late phase hypoenhancement, falsely suggesting malignancy [43].

Hepatic angiomyolipoma is a rare benign mesenchymal tumor with heterogeneous echogenicity on baseline ultrasound. CEUS shows arterial hyperenhancement [145].

Cholangiocellular adenomas (CCA or bile duct adenoma) are rare lesions that are usually small (90% < 1 cm). CEUS may show strong arterial enhancement and early wash out in the portal and late phases (they lack portal veins), falsely suggesting malignancy [65].

2.1.5. Malignant liver lesions

Hypo-enhancement of solid lesions in the late and postvascular phases, corresponding to the wash out phenomenon characterizes malignancies. Almost all metastases show this feature, regardless of their enhancement pattern in the arterial phase. Very few exceptions to this rule have been reported, mainly in atypical HCC (Table 3).

HCC in the noncirrhotic liver

HCC are usually hyperenhancing in the arterial phase, typically with a chaotic vascular pattern. In the portal venous and late phases, HCC usually shows hypoenhancement apart from well-differentiated HCC that may be isoenhancing. Hyperenhancement in the arterial phase is believed to be homogeneous with fill from the periphery. However, this information is based only on expert opinion. The fibrolamellar variant of HCC has nonspecific appearances on B-mode. According to expert opinion and a single case report, they show rapid hyperenhancement with a heterogeneous pattern in the arterial phase and rapid wash out [103].

Cholangiocarcinoma (intrahepatic cholangiocellular carcinoma)

Intrahepatic cholangiocarcinomas have a variety of patterns in the arterial phase but all show late phase wash out, in contrast to the late enhancement on CECT or CEMRI [24, 25, 152]. The typical pattern of malignancy is better displayed by CEUS than by CECT or CEMRI. Peripheral cholangiocarcinoma may also be sus-

pected on baseline US as surface retraction is a characteristic feature.

Metastases

Liver metastases can be detected and characterized reliably as hypoechoic lesions during the portal venous and late phases, with very few exceptions. Wash out starts early, usually in the portal venous phase, and is marked. Thus, they appear as punched-out “black foci” against the background of the uniformly enhanced normal liver. Larger traversing vessels can sometimes be seen as enhancing lines within the lesion but these are not tumor tissue and, thus, have the hemodynamics of the vascular tree, disappearing in parallel with the main liver vessels rather than being retained, as occurs in the normal liver parenchyma. In the late phase, very small metastases may be conspicuous and lesions that were occult on B-mode ultrasound can be detected [42].

Metastases usually show at least some contrast enhancement in the arterial phase and sometimes this is marked and often it is chaotic. Rim or halo enhancement is often seen. Only a few false positive results have been observed, mainly from abscesses or necrosis, old fibrous FNH, granulomas and inflammatory pseudotumors [40, 45, 126].

Benign lesions such as cysts, calcifications, hemangiomas, FNH and adenomas are found with the same frequency (5–20%) in the metastatic liver as in a healthy population. Thus, the possibility of a benign FLL must be kept in mind when the liver is first staged after the diagnosis of a cancer, especially with lesions < 2 cm.

Lymphoma

Lymphoma shows variable arterial enhancement but characteristic wash out in the portal venous and late phases, predictive of malignancy [57].

2.1.6. Recommended uses and indications

CEUS should be performed and interpreted with knowledge of the patient's clinical history and investigations findings. When the enhancement patterns are typical (in appropriate clinical settings) hemangiomas, FNH, focal fatty change and malignancies can all be characterized with confidence. FLL with atypical enhancement patterns or studies that are technically suboptimal require further investigation, mainly with CECT and/or CEMRI. CEUS is indicated for lesion characterization in the following clinical situations:

- ▶ Incidental findings on routine ultrasound.
- ▶ Lesion(s) or suspected lesion(s) detected with US in patients with a known history of a malignancy, as an alternative to CT or MRI.
- ▶ Need for a contrast study when CT and MRI contrast are contraindicated.
- ▶ Inconclusive MRI/CT.
- ▶ Inconclusive cytology/histology results.

Specificity and sensitivity are reduced in moderately or markedly fatty livers and with deeply positioned lesions.

2.2. Characterization of FLL in the cirrhotic liver

2.2.1. Background

Types of FLL in cirrhosis

The FLL that occur in the cirrhotic liver are hepatocellular lesions (>95% of cases), peripheral cholangiocellular carcinomas (CCC), lymphomas and hemangiomas. Other diagnoses may be considered, but they are very rare, for unknown reasons.

B-mode ultrasound may detect features of malignancy (such as infiltration of adjacent structures, including vessels) but these features are usually only seen in large nodules (>5 cm) and do not help characterize smaller nodules.

Carcinogenic mechanism in HCC

The development of HCC is thought to occur through a multistep pathway in about 90% of cases (International Consensus Group for Hepatocellular Neoplasia 2009) [2] in the following sequence:

- ▶ Large regenerative nodule.
- ▶ Low- or high-grade dysplastic nodule.
- ▶ Dysplastic nodule with a focus of HCC.
- ▶ Well differentiated HCC.
- ▶ Moderately to poorly differentiated HCC.

Progression along this pathway is accompanied by a decrease in both normal arterial and portal blood flow and a concurrent disappearance of normal intranodular vessels [105]. Simultaneous with this decline in normal vascularity, there is a progressive increase in arterial flow from newly formed tumor vessels (neoangiogenesis). Therefore, hyperenhancement in the arterial phase can be seen in HCC of all stages of differentiation [105]. These changes are key elements for the characterization of hepatocellular nodules in cirrhosis during the vascular phases of contrast enhancement.

Beside the vascular changes, HCC nodules tend to be devoid of reticuloendothelial cells (Kupffer cells), particularly with progressive dedifferentiation from well to moderately and poorly differentiated grades. This has become of particular importance with the introduction of contrast agents with a postvascular phase, where HCC shows as an enhancement defect.

The probability of HCC increases with nodule size. Nodules < 1 cm are rarely malignant and ultrasound follow up (at 3-month intervals) is sufficient, according to the AASLD guidelines [15]. Further investigations should be started when the nodule enlarges to over 1 cm. The rate of HCC is 66% in nodules 1–2 cm [55, 64], increasing to about 80% in nodules of 2–3 cm in size [11] and is above 92–95% for nodules larger than 3 cm. The most challenging situation for imaging techniques is, therefore, the diagnosis of nodules of 1–3 cm in diameter.

2.2.2. Study procedure

General recommendations for the study of FLL are summarized above (see section 2.1.2). In addition, if the liver is cirrhotic, the following points should be kept in mind.

Since the arterial phase is the most important in the setting of cirrhosis, good visualization of the nodule during normal breathing is desirable. If this is impossible, it is important to practice cooperation with the patient so that the nodule can be visualized during a breath hold, best taken about 10 s after contrast injection and maintained for 15–30 s.

As microbubbles are disrupted despite the use of a low mechanical index, acoustic output power should be reduced as much as possible, while maintaining sufficient signal intensity, to allow contrast persistence until the very late phase (beyond 3–4 min), which is often critical for the diagnosis of HCC. Furthermore, when the arterial phase is over, the lesion should be scanned intermittently, not continuously, to minimize bubble disruption that may cause difficulties in interpretation of subtle wash out.

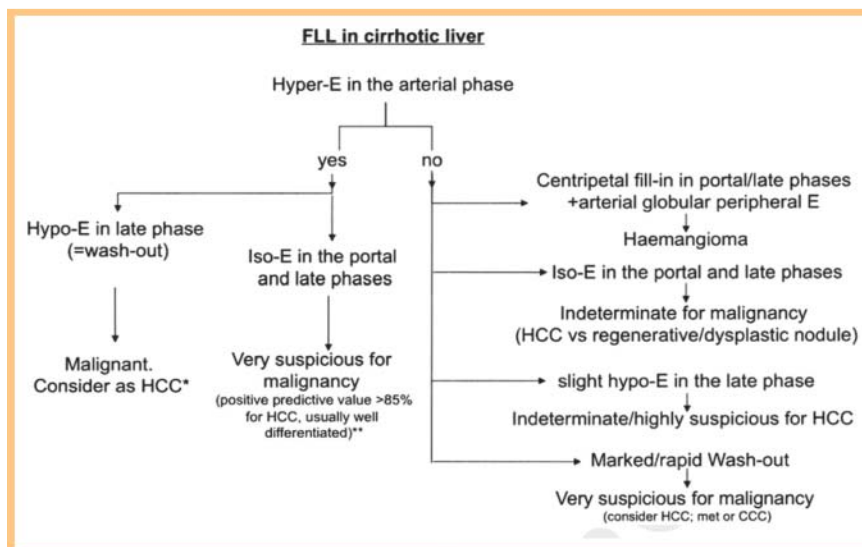


Fig. 1 *In cases with marked and rapid wash out in portal/late phase, consider the possibility of peripheral cholangiocarcinoma, especially if the pattern with MRI or CT does not confirm late wash out, or (exceptionally) metastasis or lymphoma. CEUS alone with a typical pattern is enough to establish a diagnosis of malignancy in nodules > 1 cm, but a panoramic imaging technique (CT or MRI) is required to stage the patient before treatment. **When Sonazoid is used, the postvascular phase may allow diagnosis of malignancy if the lesion becomes hypoenhancing in the postvascular phase, even though it appeared isoenhancing in the portal/late phases. E = enhancement; HCC = hepatocellular carcinoma; CCC = cholangiocellular carcinoma; met = metastasis.

2.2.3. Image interpretation and evaluation CEUS pattern and diagnosis of HCC (Table 3)

The key feature for the diagnosis of HCC in liver cirrhosis is hyper-enhancement in the arterial phase, followed by wash out in the late phase [15]. This pattern corresponds to HCC in more than 97% of cases [12, 49, 57, 144]. However, it has also been reported in peripheral CCC and hepatic lymphoma, which comprise the remaining 1–3% of cases. The timing and intensity of wash out in the latter lesions have not yet been described precisely [12, 49, 57, 144].

Arterial hyperenhancement is usually homogeneous and intense in HCC, but may be inhomogeneous in larger nodules (> 5 cm), which contain regions of necrosis. Rim enhancement is atypical for HCC.

Wash out is observed overall in about half the cases of HCC but more rarely in very small nodules (20–30% in those 1–2 cm, 40–60% in those 2–3 cm) [55, 92, 122]. Wash out is observed more frequently in HCC with poorer grades of differentiation than in well-differentiated HCC, which tend to be isoechoic in the late phase [12, 49, 64, 68].

The hypoenhancement in the late phase is usually less marked in HCC than in other primary tumors or in liver metastases. Furthermore, the wash out tends to start later in HCC, usually not before 60 s after injection and, in up to 25% of cases, appearing only after 180 s [12, 26]; consequently it is important to observe nodules in cirrhosis until very late (> 4 min) to increase sensitivity for the diagnosis of HCC. Early wash out (< 60 s) has been reported to occur in poorly differentiated HCC or to suggest a nonhepatocellular malignancy [12, 26, 49, 68], most often a peripheral CCC. Wash out in HCC is observed less often with CEUS compared with MRI or CT because of their different contrast pharmacokinetics [55, 92, 122, 135].

Arterial hyperenhancement not followed by wash out is also highly suspicious for HCC, mainly for the well-differentiated variants but is not definitive [11, 12, 49, 64, 68].

An inconclusive CEUS pattern does not rule out malignancy and should prompt other imaging (CT or MRI) and, if these are also inconclusive, biopsy is needed. If this is negative, the nodule should be followed up every 3 months (at least for the first 2 years) and, if it enlarges or the enhancement pattern changes, diagnostic investigations must be resumed. If arterial enhancement is present

on any imaging technique, repeated biopsy should be considered even in the absence of changes in size or enhancement. Hemangioma has the same CEUS pattern in cirrhosis as in the noncirrhotic liver but an additional MRI scan is preferable to confirm the diagnosis in this clinical setting. Abscesses may occur in cirrhosis, usually as a complication of interventional procedures. CEUS shows typical findings of malignancy in CCC, whereas the enhancement pattern at MRI and CT may be inconclusive [144].

Staging of cirrhotic patients with HCC and the role of CEUS

Examining the entire liver during the arterial phase to look for hyperenhancing nodules is difficult or impossible with CEUS, so CECT or CEMRI must be used to stage patients with HCC [15]. For Sonazoid®, the postvascular phase may improve staging of the disease.

A diagnostic flowchart for CEUS of nodules in cirrhosis is given in **Fig. 1**.

2.2.4. Recommended uses, indications and limitations

CEUS is recommended:

- ▶ To characterize all nodules found on surveillance and routine US.
- ▶ To characterize nodules in cirrhosis and establish a diagnosis of HCC. It is a strong belief of the expert panel that CEUS is extremely useful, especially when performed immediately after nodule detection, to make a rapid diagnosis. However, CT or MRI are needed (unless contraindicated) to stage the disease before the treatment strategy is decided.
- ▶ Whether CEUS has a role as first line investigation at the same level as CT or MRI is variably accepted in national and international guidelines. For example, CEUS is part of the Japanese guidelines on HCC [79, 80] but has been removed from the American guidelines [15]. This was partly justified by the fact that no UCA is licensed for the liver in the USA and additionally because of the risk of misdiagnosing CCC for HCC when CEUS is used alone (1–2%). In practice, the likelihood of misdiagnosis is minimal when CEUS is performed by skilled operators [8].
- ▶ When CT or MRI is inconclusive, especially in nodules not suitable for biopsy.
- ▶ To contribute to the selection of nodule(s) for biopsy when they are multiple or have different contrast patterns.

- ▶ To monitor changes in size and enhancement patterns over time when a nodule is not diagnostic for HCC and is being followed.
- ▶ After inconclusive histology.

2.2.5. CEUS with postvascular phase agents in cirrhotic liver nodules

Technical aspects and diagnostic features

Sonazoid® is different from pure blood-pool ultrasound contrast agents in that, in addition to the arterial and portal venous phases, there is a postvascular phase starting from 10 minutes after injection. Sonazoid® is taken up by the reticuloendothelial cells, particularly the Kupffer cells, similarly to SPIO MRI contrast agents [75]. The microbubbles can be detected even when located within cells.

The mesenchymal meshwork of malignant lesions usually does not harbor reticuloendothelial (Kupffer) cells, at variance from normal and cirrhotic liver parenchyma and from most solid benign liver lesions. The absence of Kupffer cells causes a defect in Sonazoid® uptake in the postvascular phase [61, 66], which is, thus, a molecular imaging modality. The diagnostic capability of CEUS with Sonazoid® in the postvascular phase is similar to that of MRI with an SPIO [75] and has been endorsed in the Japanese guidelines for the management of HCC [79].

Study procedures specific to postvascular phase agents

- ▶ After intravenous injection of Sonazoid®, continuous scanning for 30–60 s is recommended to assess the arterial and portal venous phases.
- ▶ The late vascular phase is deemed less relevant by Japanese authors, as this is replaced by the postvascular phase. For assessment of the postvascular (Kupffer) phase, scanning is begun not earlier than 10 min postinjection of Sonazoid® to allow clearance of contrast from the blood pool [78].
- ▶ After the end of the portal venous phase, insonation of the liver should be stopped to limit acoustic disruption of microbubbles before the postvascular phase.
- ▶ The postvascular phase lasts until the microbubbles have disappeared; thus, there is usually enough time for a thorough assessment of the whole liver to detect enhancement defects that suggest malignant nodules.
- ▶ When an enhancement defect is identified in the postvascular phase, a repeat contrast injection can be performed, superimposed on the original enhancement, to assess the arterial phase in this region. This procedure is termed “defect reperfusion imaging” or “defect reinjection technique” [78].

Image interpretation

Image interpretation in the postvascular phase with Sonazoid® is reported in **Table 4**. A contrast defect, corresponding to hypoenhancement in the postvascular phase should be regarded as highly suggestive of malignancy in the setting of nodules in cirrhosis [61]. Very well differentiated, early HCC, are iso-enhancing in both the arterial and the postvascular phases in approximately 70% of cases [6]. Nodule characterization cannot be performed in the postvascular phase alone, for which arterial phase assessment remains the cornerstone.

Recommended uses and indications

CEUS with Sonazoid® is recommended:

- ▶ To characterize nodules in cirrhosis, allowing assessment of both the vascular and postvascular phases. CEUS has been adopted in the Japanese guidelines for the management of HCC [76, 79, 80] to search for nodules seen on CT or MRI but unidentifiable on B-mode ultrasound.
- ▶ To screen for HCC in a cirrhotic liver [77]; however, there is no evidence to date that this procedure is cost-effective.
- ▶ To stage HCC in livers in which US imaging is satisfactory; however, there is no evidence to date that CEUS can replace CT or MRI.

2.2.6. Tips for all contrast agents

- ▶ When a nodule is deeply located (>8 cm) and suboptimally visualized with conventional B-mode ultrasound, its evaluation can become even worse during CEUS because of attenuation by contrast microbubbles. Use of greater amounts of contrast increases the signals both from nodules and from superficial tissues, usually failing to improve or even worsening target evaluation. Irrespective of the contrast agent used, high doses should be avoided because this limits CEUS penetration in all phases.
- ▶ When the liver parenchyma is coarse on B-mode ultrasound, it may be extremely difficult to detect small nodules making it difficult to choose the region to be scanned during CEUS in the arterial phase.
- ▶ In case of liver nodules in patients with complete portal thrombosis, perfusion of the parenchyma depends on the arterial supply. Reducing the contrast dose (half the usual dose or less) can reduce signal saturation and improve tumor conspicuity.

Table 4 Enhancement patterns of focal liver lesions in liver cirrhosis during the postvascular phase (Kupffer phase) with Sonazoid®.

| lesion | post-vascular phase with Sonazoid® (Kupffer phase) |
|--|--|
| cyst | nonenhancing |
| hemangioma | nonenhancing |
| FNH | iso to hyperenhancing |
| regenerative nodule | |
| typical features (but not diagnostic) | isoenhancing |
| additional features (but not diagnostic) | slightly hypo- or hyperenhancing |
| dysplastic nodule | isoenhancing |
| HCC | |
| typical features | nonenhancing or hypoenhancing |
| additional features | isoenhancing (well differentiated HCC) |
| cholangiocarcinoma | |
| typical features | nonenhancing or hypoenhancing |
| additional features | not reported |
| metastasis | |
| typical features | nonenhancing or hypoenhancing |
| additional features | not reported |

The arterial and portal venous phases are the same as for other agents. Cholangiocarcinoma may mimic metastasis and poorly differentiated HCC. Metastasis may mimic cholangiocarcinoma and poorly differentiated HCC.

2.3. Characterization of portal vein thrombosis

2.3.1. Definition

Portal vein thrombosis refers to the development of solid material within the lumen of any portion of the portal vein. The thrombus may be occlusive or nonocclusive and may involve the entire portal venous system or any segment. There are two main forms [115]:

- ▶ Bland (appositional) thrombosis refers to the presence of a simple clot within the vein. It is often silent and may be clinically inapparent.
- ▶ Malignant (neoplastic) thrombosis occurs almost always as a complication of HCC in the liver. Its identification is of prognostic significance as it negatively alters therapy options and upstages disease.

2.3.2 Imaging of portal vein thrombosis

Baseline ultrasound and Doppler techniques

The thrombosed portal vein may look normal and yet be filled with thrombus. However, more often the thrombus has variable echogenicity, making the lumen appear hypoechoic rather than anechoic. The baseline scan should include color and spectral Doppler interrogation of the portal veins. Complete thrombosis shows no detectable signal from the portal vein, even when optimized for slow flow. The presence of intrathrombus signal with an arterial waveform on Doppler spectral examination is a highly specific sign of malignancy but its sensitivity is only moderate.

CEUS

Bland thrombus is avascular and shows as a void within the enhancing liver in all phases of CEUS but best visualized during the portal venous phase. A malignant thrombus has the same enhancement characteristics as the tumor from which it originated, including rapid arterial phase hyperenhancement [115, 121, 134]. While slow and weak portal venous wash out may be seen, the wash out is usually more rapid.

To perform the scans, the suspect thrombus within the vein should be studied during the wash in of the UCA, as the vascularization of the clot should parallel the arrival of the microbubbles within the hepatic artery in the liver in case of neoplastic thrombus. Sweeping through the liver in sagittal and axial planes in the portal venous phase will often depict the washed out tumor within the portal vein branches optimally.

The tumor source of a malignant portal vein thrombus may be obvious or it may be invisible on ultrasound, even with the assistance of CEUS. Sweeping through the liver in both the arterial and the portal venous phases of enhancement may be enlightening. Washed out regions of the liver should undergo reinjection with arterial phase imaging to show their arterial enhancement. A suspicious clot within the portal vein may be amenable to biopsy with US guidance, targeting, whenever possible, enhancing regions within the thrombus [134].

2.4. CEUS for biopsy planning in cirrhotic and normal livers

CEUS prior to biopsy procedures can increase the diagnostic yield by 10% and decrease the false negative rate especially in large tumors with areas of necrosis. CEUS can localize the site for biopsy more accurately by demonstrating regions of vascularized viable tumor, which should be targeted, and regions of necrosis, which should be avoided [150]. These two entities cannot be distinguished by conventional ultrasound alone. CEUS may also locate occult lesions on nonenhanced US [125].

3. Detection of Malignant FLL: Transabdominal Approach



3.1. Background

Conventional US is the most frequently used modality for the primary imaging of abdominal organs, including the liver but is less sensitive in the detection of liver lesions than CECT, CEMRI or intraoperative US. The main reasons for this are difficulties in detecting small and isoechoic lesions, especially when they are deep or in difficult anatomic locations.

The published literature [17, 22, 42, 66, 74, 84, 114, 119] provides strong evidence that CEUS significantly improves the detection of metastases compared with conventional US. The most important CEUS feature for detecting a malignant liver lesion is the identification of a focal region of wash out occurring as early as the late arterial phase but mostly during the portal venous and late or postvascular phases.

3.2. Study procedures

The study procedure is similar to the study procedure described in section 2.1.2 but the following points should be borne in mind:

- ▶ With all agents, lesion detection requires an examination time of at least 3 – 4 min, which is the useful persistence of most microbubbles.
- ▶ With agents presenting a postvascular phase (Sonazoid®), it is possible to detect lesions that wash out very late [61, 108].
- ▶ A second administration (reinjection technique) can be used to confirm the metastatic nature of any detected contrast defect by demonstrating arterial enhancement followed by wash out (see section 2.2.6).

3.3. Detection of metastatic lesions

The typical and almost invariable appearance of metastases is focal hypoenhancement in the portal venous, late and postvascular phases. The enhancement patterns observed during the arterial phase are variable and help to characterize lesions but aid only minimally in their detection (see section 2.1.3).

With vascular phase agents (SonoVue®, Definity®), several studies have shown that the accuracy in the detection of liver metastases is comparable to that of CECT and CEMRI, when scanning conditions allow a complete investigation of all liver segments [84].

3.4. Detection of HCC and CCC

With all agents (SonoVue®, Definity®, Sonazoid®), most HCC show increased enhancement in the arterial phase but the short duration of this phase makes adequate assessment of the whole liver impossible, at least with current technology. The late phase lasts long enough for thorough exploration, but the appearances of HCC are variable, as described in section 2.2.3, and, importantly, not all HCC wash out in the late phase, limiting the sensitivity of CEUS for the detection of HCC. Consequently, routine use of UCA in the detection of HCC with vascular phase agents cannot be recommended.

With agents presenting a postvascular phase (Sonazoid®), scanning the entire liver at 10 min or later after injection helps to detect malignant nodules since typical HCC show as an enhancement defect [60, 104, 108]. However, postvascular defects are not specific findings and demonstration of homogeneous arterial enhancement requires a second administration of Sonazoid® to confirm the diagnosis of HCC. Moreover, approximately half of

well differentiated HCC do not show enhancement defects in the postvascular phase [6].

Depiction of local tumor recurrence and residual tumor after ablation using B-mode alone is difficult. With vascular phase agents, scanning in the arterial phase with repeated injections demonstrates the hypervascularity in the recurrence, which usually lies adjacent to the previously ablated tumor. The same technique is useful for demonstrating new HCC and, in both cases, helps identify the target and guide treatment (see section 5.1).

Cholangiocarcinomas behave in the same way as metastases, washing out rapidly and appearing as defects in the late phase, regardless of the appearance in the arterial phase [151]. This pattern may facilitate detection of satellite nodules adjacent to a larger lesion that were not visualized on conventional US.

3.5. Recommended uses, indications and limitations

Use of CEUS is recommended for the following indications:

- ▶ To characterize indeterminate (usually small) lesions shown on either CECT or CEMRI.
- ▶ To “rule out” liver metastases or abscesses, unless conventional ultrasound shows typical findings.
- ▶ For treatment planning in selected cases to assess the number and location of liver metastases, either alone or as complementary to CECT and/or CEMRI.
- ▶ Surveillance of oncology patients where CEUS has been useful previously. Recommended to replace unenhanced US with CEUS for the evaluation of liver metastases in colorectal cancer after chemotherapy [73].
- ▶ CEUS with vascular phase agents is not indicated for the detection and staging of HCC. With the use of Sonazoid® and postvascular phase scanning, CEUS may be used to stage HCC in the liver where imaging is good. However, there is no evidence to date that CEUS can replace CT or MRI.
- ▶ A potential pitfall is that small cysts, which were not seen on unenhanced US, are sometimes detected in late or postvascular phase scanning. Careful re-evaluation with conventional US may help to show their cystic nature. In doubtful situations, a second contrast agent injection is recommended, looking for arterial phase enhancement, which indicates viable tumor tissue.

4. Intraoperative Contrast Enhanced Ultrasound



4.1. Background

Standard preoperative imaging remains limited in selecting patients who may benefit from liver surgery [47, 106]. Intraoperative ultrasound (IOUS) is recognized as the gold standard, which ultimately dictates the surgical management of those undergoing resection [21, 23, 33, 69]. Patients with early stage HCC are offered transplantation or resection [16], which can be curative procedures. Similarly, for patients with colorectal liver metastases, resection is the treatment of choice, with 5-year survival rates of up to 60% [54, 124]. However, 75% of patients who undergo resection develop recurrences (50% in the liver). The majority of recurrences appear within 2 years [4, 51, 124]. Thus, more accurate imaging is required.

Recent studies of intraoperative contrast enhanced ultrasound (IO-CEUS) with different contrast agents have shown that it is more sensitive, specific and accurate than IOUS, CT or MRI in defining whether tumor resection (metastases or HCC) is appropri-

ate. Furthermore, surgical management is altered in up to 30% of cases [52, 90, 110, 118, 141, 142]. It is now recognized that the more aggressive the surgical approach adopted, the higher the impact of IO-CEUS becomes [90].

4.2. IO-CEUS technique

Dedicated high frequency intraoperative probes with contrast specific capability are needed. Covering the transducer and cable with a long sterile sheath containing coupling gel, and the control panel with a large sterile membrane ensures sterility. Some ultrasound systems provide intraoperative transducers that can be sterilized by gas and, thus, need no cover.

At surgery, all patients undergo a manual abdominal and pelvic exploration for extra-hepatic disease followed by mobilization of the liver from the diaphragm to improve sonographic access. Bimanual palpation of the liver is then performed, followed by systematic IOUS of the entire liver, looking for previously diagnosed as well as for new lesions and to identify involvement of major vessels or bile ducts.

With vascular phase agents (SonoVue® and Definity®) CEUS is used as explained for the transabdominal approach (see section 2.1.2). The duration of enhancement in normal liver in the late phase is shorter than with percutaneous US. Injections may be repeated for global assessment, or to assess the arterial phase enhancement of identified lesions for their characterization. Irrespective of the contrast agent used, high doses should be avoided because this limits US penetration in all phases.

With postvascular phase agents (Sonazoid®), detection of malignant FLL starts 10 min postinjection [61, 108]. A second injection can be used to confirm the metastatic nature of a lesion by demonstrating arterial enhancement (see section 2.1.6).

4.3. Image interpretation

Image interpretation is the same as for the transabdominal approach reported in section 2.1.5.

4.4. Recommended use and limitations

IO-CEUS is recommended for:

- ▶ The detection of liver metastases in all patients undergoing liver resection.
- ▶ The characterization of focal liver nodules in cirrhotic patients undergoing liver resection for HCC, especially of new nodules detected at IOUS [142].
- ▶ The targeting of occult lesions for ablation therapy for patients undergoing combined liver resection and ablative therapy.

The shorter duration of contrast enhancement is a limitation of IO-CEUS.

5. Monitoring Ablation Treatment



5.1. Monitoring local ablation treatment

5.1.1. Background

Locoregional therapies, which conventionally include ablation, whatever the modality used, and transarterial chemo/radioembolization, play a key role in the management of patients with liver malignancies, both HCC and metastases [58, 98].

Unenhanced US is commonly used to guide ablation. It is easy to use and widely available but, even when combined with Doppler, it does not provide useful information on the extent of the ablation. Assessment of tissue perfusion is crucial to differentiate necrotic from viable residual tumor.

The addition of CEUS can provide important information in each of the following procedures [30, 107]:

- ▶ Assessment of the lesions to be treated by ablation (number and size and homogeneity of enhancement of the lesions, and the presence of feeding vessels) to define the eligibility of the patient for treatment and the best ablation strategy.
- ▶ Depict previously undetectable lesions with the support of fusion imaging, enabling needle/probe guidance.
- ▶ Detecting viable tumor persistence following locoregional treatment (either ablation or chemo/radioembolization).

5.1.2. Study procedures (see also section 2.1.2)

Pretreatment CEUS

Particularly for metastases, assessment of size must include the perilesional hypervascular halo with wash out. Tumor margins are better detected by CEUS than unenhanced US [28] because definition of its relationships with surrounding structures is improved, thus, helping develop appropriate treatment strategies and reducing the risks of complications [27, 28].

Accurate pretreatment planning can be improved by real-time fusion imaging with CT, MRI or CEUS, which provides an accurate volumetric map of the tumor and graphically depicts the number and sites of the ablation volumes needed to cover the whole mass and achieve an adequate perilesion “safety margin” [29, 97].

Pretreatment CEUS is very helpful for comparison of the patterns before and after treatment.

The field depth, selected scan plane, acoustic gain and MI used for the pretreatment CEUS study of each lesion must be predefined. Images and/or video clips should be stored for precise comparison with immediate postablation studies.

Positioning of ablation device

The ablation device is inserted when the target is optimally depicted. When lesion targeting is particularly difficult (e.g., small lesion size, difficult location), fusion imaging with CT/MRI may allow “targeted” CEUS in some instances [36] and consequent improvement of ablation needle/probe guidance. Depiction of a “virtual needle” during CEUS provided by fusion imaging may facilitate the procedure.

5.1.3. Image interpretation – definition of complete treatment response

The Response Evaluation Criteria in Solid Tumors (RECIST) guidelines [139] for the assessment of tumor response are no longer considered adequate for locoregional treatment because of the poor relationship between necrosis and tumor size. After thermal ablations, completely necrotic tumors may remain unchanged in size, whereas tumors that shrink may still be partially viable.

Accordingly, the RECIST criteria have been amended, at least for HCC [91], to stress that the imaging indicator of complete ablation is the disappearance of any previously visualized intralésional enhancement on CEUS. This must be assessed throughout the whole volume of each tumor which has undergone ablation [30, 130]. The volume of the necrosis achieved should be compared with the pretreatment volume of the tumor(s). Simultaneous display of tissue and contrast is of particular value for follow-up of treated lesions. The volume of necrosis achieved can be compared with the pretreatment volume of the same lesion on CECT or CEMRI using real-time fusion imaging [72].

Completeness of treatment of hypoenhancing lesions (mostly liver metastases) can be assessed by comparing the volume and lo-

cation of pretreatment lesions with those of the ablated region. This also determines whether a sufficient safety margin around the lesion has been achieved. The frequent occurrence of satellite nodules around small HCC (5–10 mm from the main tumor [123]), dictates that the thickness of the safety margin following ablation should be assessed not only for liver metastases but also for HCC.

5.2. Periprocedural assessment of treatment response

Unenhanced US is used to monitor the reduction of the hyperechoic “cloud” of gas caused by heating immediately after ablation. This usually takes 5–15 min to dissipate.

For each treated lesion, the same system settings and scan planes must be used as for the preablation assessment. Images and/or video clips should be stored for comparison with previously stored preablation images. If additional probe/needle insertions are performed, repeated doses of UCA can be given.

5.2.1. Follow-up investigation to assess tumor recurrence

It is often difficult to depict local tumor recurrence after ablation using B-mode alone. Here, scanning in the late or postvascular phase, with subsequent reinjection to confirm tumor enhancement in any suspicious region is useful to identify the viable tumor adjacent to the ablated volume. This can be used to guide biopsy and additional treatment. While CEUS may be extremely useful to define local recurrence in a treated nodule, CT and MRI provide a better overview of the liver to detect distant intra- and extrahepatic tumor and cannot be replaced by CEUS.

In the early postablative evaluation (within the first 30 days), a thin, uniform enhancing rim can be visible along the periphery of the necrotic region, similar to the findings on CECT. Misinterpretation of this perilesional hyperemic halo as residual viable tumor can be avoided by comparing postablation images with preablation scans.

5.2.2. Recommended uses and indications

- ▶ As a complement to CECT and/or CEMRI for pretreatment staging and assessment of target lesion vascularity.
- ▶ Facilitation of needle positioning in cases of incomplete or poor lesion delineation on unenhanced US.
- ▶ Evaluation of the immediate treatment effect after ablation and guidance for immediate re-treatment of residual unablated tumor. Using this strategy, the rate of incomplete ablation in the first session is reported to decrease from 16 to 6% [29].
- ▶ Assessment of local tumor progression when follow-up CECT or CEMRI are contraindicated or not conclusive. In addition to CECT and/or CEMRI, CEUS may be used in follow-up protocols.

6. Liver Transplantation



6.1. Background

Liver transplantation is currently an established first-line treatment for patients with end-stage acute or chronic liver disease but postoperative complications may limit its long-term success and their early detection is extremely important for graft and patient survival. Hepatic artery (HA) thrombosis, which is the most common and severe vascular complication, occurs in 3–8% of transplants in adults [67, 129]. Acute HA thrombosis almost invariably leads to graft loss from infarction and eventual abscess formation. Hepatic artery stenosis may proceed to thrombosis and may cause ischemic liver and biliary injuries if not promptly

corrected. Although portal vein (PV) and hepatic vein or caval thrombosis are less frequent, they are also serious complications that may lead to graft loss [83]. Clinical signs of vascular complications are often nonspecific, and the diagnosis, best made at the presymptomatic stage, depends on imaging. Ultrasound is usually used first to detect vascular complications as well as for long-term follow-up [46, 53, 83].

Though Doppler is useful, it may be not sensitive enough to depict slow flow in a patent HA, particularly in patients with postoperative edema, inaccessible hepatic arteries, or inability to cooperate [131]. When flow cannot be identified in the HA, CECT or angiography, with their attendant risks, were hitherto required to obtain a definitive answer; CEUS can be used instead and is often able to overcome the limitations of Doppler.

6.2. Study procedure

The study procedure is as described in section 2.1.2. The intrahepatic arterial tree is well visualized at the time of its enhancement in the early arterial phase, before arrival of contrast microbubbles in the portal system. The right hepatic artery is usually visible anteriorly alongside the right portal branch through a right intercostal scan and the left hepatic artery at the bifurcation of the left portal branch, optimally seen with a supine epigastric approach. The portal vein and its branches are visualized in the portal venous phase, following which the enhancement of the parenchyma can be studied looking for infarcts, which appear as nonenhancing regions. Later the hepatic veins fill and can be studied. When only the vessels are to be explored, a reduced amount of injected contrast may improve their visualization by preventing signal saturation.

6.3. Image interpretation

Lack of visualization of the arterial tree, expected to be seen before portal enhancement, indicates complete arterial thrombosis with very high positive predictive values [10, 32, 99, 131]. Identification of the arterial branches when conventional Doppler has failed [131], may allow subsequent targeted Doppler reassessment, which is needed to distinguish thrombosis from slow flow caused by vasoconstriction or splenic steal from post-thrombotic/stenotic recanalization, tasks not achievable using CEUS alone. When the main hepatic artery is visible, CEUS depicts the shape of the lumen and its course, possibly identifying stenoses, which usually occur at the site of the surgical anastomosis [154]. CEUS may also allow study of the shape and patency of the caval and portal anastomoses.

6.4. Recommended Indications and Limitations

6.4.1. Indications

Before liver transplantation, CEUS is indicated to assess portal vein thrombosis and characterize focal liver lesions in cirrhosis. After liver transplantation, CEUS can be performed at the bedside or in the intensive care unit, avoiding most of the risks associated with CECT or angiography [10, 32, 63, 100, 154]. CEUS is indicated for:

- ▶ Confirmation of occlusion of the intrahepatic hepatic arteries, portal veins, hepatic veins or inferior vena cava (IVC) after an inconclusive Doppler evaluation of the liver vasculature. The extrahepatic arterial tree cannot always be studied in its entirety and complete patency cannot be confirmed with certainty without the addition of the finding of normal flow tracings from the intrahepatic arteries on Doppler US. In the late phase, the ultrasound can be switched to Doppler to exploit

the remaining microbubbles to enhance the Doppler signals and investigate small vessels missed without contrast.

- ▶ Confirmation of the presence and assessment of the nature of fluid collections and, in case of recent hematomas, to search for active bleeding.
- ▶ Exclusion of perfusion defects when infarction is suspected.
- ▶ For monitoring the success of thrombolysis in the intensive care unit (ICU) after interventions for hepatic artery occlusion.

6.4.2. Limitations

- ▶ In the early postoperative period, wounds and surgical dressings or subcutaneous emphysema, may limit examination windows.
- ▶ In patients with split liver transplantation or after living donor liver transplantation, the examination may be more difficult because of the complex anatomy.
- ▶ Imaging the prehepatic portions of the hepatic artery and portal vein may be precluded by the surgical wound or intervening bowel gas.

6.4.3. Tips and tricks

- ▶ When a side-to-side caval (piggyback) anastomosis is used, the distal part of the donor cava may thrombose and simulate a small subcapsular hematoma.
- ▶ Ascites may collect alongside the ligament teres and may simulate a complex cyst on follow-up examinations.
- ▶ Knowledge of the surgical procedures including the presence of jump grafts, difficult anastomoses and the status of the donor liver may be helpful to interpretation.
- ▶ While CEUS shows the morphology of the vessel lumen, integration with Doppler US is required to confirm the presence of a hemodynamically significant stenosis.

7. Contrast Quantification and Monitoring Systemic Treatment of Malignancies



7.1. Background

Neovascularization is a key stage in the growth of malignancies beyond 2–3 mm³. This neoangiogenesis is an important target for novel anticancer treatments and many new antiangiogenesis or antivascular treatments aim at destroying or limiting the growth of tumor vessels [50, 70]. A new area of clinical utility for dynamic contrast enhanced ultrasound (DCE-US) has emerged for monitoring the response to these drugs. Initially, such monitoring relied on qualitative analyses only. More recently, robust and quantitative features have been developed. To achieve successful results, standardization and strict control of scanner settings are needed [39].

7.2. Methodology and equipment for quantification

7.2.1. Data acquisition

Contrast specific imaging is used to distinguish microbubble signals from tissue. The best temporal and spatial resolution is provided by nonlinear gray scale modes (see section 1.3). Conventional Doppler imaging techniques cannot visualize vessels smaller than approximately 100 μm but CEUS can detect signals from vessels up to 40 μm [56] and, thus, provides a better assessment of the extent of angiogenesis.

7.2.2. Quantification software

Early measurements of contrast kinetics (i.e., time-intensity curves, TIC) were performed using video data because it was readily available. Background subtraction was necessary to compensate for attenuation effects [13] and extract reliable time-based features, such as time to peak intensity, mean transit time, etc. However, the nonlinear compression applied to the original signals (required to display them on video monitors) distorts amplitude-based TIC features (e.g., peak intensity and area under the curve) [112].

The majority of reports have used uncompressed, post beam formed data (radio-frequency data are not required since the phase information is not essential). TIC based on such raw data sets allow for accurate assessment of both time-based and amplitude-dependent features. All manufacturers that supply built-in analysis packages on their scanners use this type of data but off-line software packages are also available [35].

7.3. Administration of UCA and quantitative analysis

7.3.1. Bolus injection

Functional ultrasound studies are based on measuring the time sequence of signal enhancement, typically over the initial 1–3 min after an intravenous bolus injection, either across a large region-of-interest such as an entire tumor or on a pixel-by-pixel basis. The resulting TIC follows the wash in and wash out of the contrast agent and features linked to blood flow and blood volume can be extracted from them. Quantitative analyses of the TIC can be performed to determine functional features that characterize the TIC with or without curve fitting. Several functional features can be studied [87]:

- ▶ Related to fractional blood volume: peak intensity (PI); area under the curve (AUC) [32]; area under the wash in (AUWI); under the wash out (AUWO).
- ▶ Related to blood flow: time to peak intensity (TPI); slope of the wash in (SWI).
- ▶ Related to transit time: mean transit time (MTT).

It is also possible to map the changes in TIC features over time and show these as colorized functional images.

7.3.2. The disruption-replenishment or reperfusion method

In this method, originally described for the heart [146], a high intensity diagnostic series of pulses is transmitted to a tissue slice filled with microbubbles following bolus or infusion injection, to destroy the bubbles within it. The scanner then switches to a low MI and the refill of the slice with microbubbles is monitored with a contrast-specific imaging mode. The refill takes the form of a rising exponential curve whose slope, β , relates to the velocity of blood inflow while the maximum enhancement, A , relates to the fractional blood volume. Their product forms an estimate of tissue perfusion [59].

The advantage of an infusion of UCA is that a concentration equilibrium can be achieved, which makes it easier to compare different tissue regions directly [96, 137]. With the destruction-reperfusion method only the wash in phase can be assessed, which may limit its utility.

7.3.3. Hepatic vein transit times

The arrival times of a UCA bolus in the hepatic artery, portal vein and hepatic veins can be measured and transit times calculated. Shortening of the transit time between the hepatic artery/portal vein and the hepatic veins occurs in the presence of liver malignancies, presumably because of intrahepatic shunting. However, this also occurs in cirrhosis [93, 94], resulting in a nonspecific finding which limits its use in liver malignancy. Its use to stage chronic hepatitis is also limited by the substantial overlap between different stages despite statistically significant differences among groups [120].

7.4. Assessment of antiangiogenic treatment

Since antiangiogenic treatment frequently induces necrosis without causing tumor shrinkage, functional imaging techniques are particularly suitable for the early assessment of response, a task for which both the RECIST and World Health Organization (WHO) size criteria [139, 149] are unsatisfactory [91]. Studies of various types of tumors treated with antiangiogenic therapies have confirmed that DCE-US may enable early prediction of response to treatment [38, 82, 85, 86, 88, 89].

Affiliations

- ¹ Department of Pediatric Radiology, INSERM U947, Centre Hospitalier Universitaire de Nancy and Université de Lorraine, Vandoeuvre, France
- ² Medizinische Klinik 2, Caritas-Krankenhaus Bad Mergentheim, Germany
- ³ Department of Radiology, Seoul National University Hospital, Seoul, Korea
- ⁴ Imaging Sciences Department, Imperial College, Hammersmith Hospital, London, United Kingdom
- ⁵ Department of Gastroenterology and Hepatology, Kinki University School of Medicine, Osaka, Japan
- ⁶ Ultrasound Section, Division of Surgery, Department of Gastroenterology, Herlev Hospital, University of Copenhagen, Copenhagen, Denmark
- ⁷ Division of Internal Medicine, University of Bologna, Bologna, Italy
- ⁸ Division of Gastroenterology, University of Calgary, Calgary, Alberta, Canada
- ⁹ Northeastern Ohio Medical University, Rootstown, Ohio, United States of America
- ¹⁰ Institute of Radiology, School of Medicine, University of São Paulo, São Paulo, Brazil
- ¹¹ Thane Ultrasound Centre, Jaslok Hospital, Mumbai, India
- ¹² Peking University Cancer Hospital, Peking, China
- ¹³ Interdisciplinary Ultrasound Center, Department of Clinical Radiology, University of Munich-Grosshadern Campus, Munich, Germany
- ¹⁴ Service de Radiologie Adultes, Hôpital Necker, Université Paris Descartes, Paris, France
- ¹⁵ Department of Ultrasound, Zhongshan Hospital, Fudan University, Shanghai, China
- ¹⁶ Department of Radiology, Thomas Jefferson University, Philadelphia, Philadelphia, United States of America
- ¹⁷ Department of Radiology, University of Michigan, Ann Arbor, Michigan, United States of America
- ¹⁸ Department of Radiology, Royal Melbourne Hospital, University of Melbourne, Melbourne, Australia
- ¹⁹ Division of Diagnostic Ultrasound, Department of Radiology, Thomas Jefferson University Hospital, Philadelphia, Pennsylvania, United States of America
- ²⁰ Integrated Research Cancer Institute in Villejuif, Gustave Roussy Institute, Villejuif, France
- ²¹ Imaging Department, Imperial College, London, United Kingdom
- ²² MRI Institute, University of California San Diego, San Diego, California, United States of America
- ²³ Department of Gastroenterology and Hepatology, Tokyo Medical University, Tokyo, Japan
- ²⁴ Department of Interventional Oncologic Radiology, General Hospital of Busto Arsizio, Busto Arsizio, Italy
- ²⁵ Central Ultrasound Department, Klinikum Siloah, Klinikum Region Hannover, Hannover, Germany
- ²⁶ Department of Medical Ultrasound, Tenth People's Hospital of Tongji University, Shanghai, China

Acknowledgments

▼ The authors acknowledge the educational contributions provided by the following companies: Bracco; GE Healthcare; Hitachi Medical Systems; Lantheus Medical Imaging; Medison; Philips Medical Systems; Siemens Healthcare; Toshiba Medical Systems;

and Supersonic Imagine. The authors gratefully acknowledge Glynis Harvey from the WFUMB office for her efficient management.

References

- 1 EFSUMB (European Federation of Societies for Ultrasound in Medicine and Biology). Minimum training recommendations for the practice of medical ultrasound. *Ultraschall in Med* 2006; 27: 79–105
- 2 International Consensus Group for Hepatocellular Neoplasia. Pathologic diagnosis of early hepatocellular carcinoma: a report of the international consensus group for hepatocellular neoplasia. *Hepatology* 2009; 49: 658–664
- 3 EFSUMB (European Federation of Societies for Ultrasound in Medicine and Biology). Minimum training requirements for the practice of Medical Ultrasound in Europe. *Ultraschall in Med* 2010; 31: 426–427
- 4 Adam R, Bismuth H, Castaing D *et al.* Repeat hepatectomy for colorectal liver metastases. *Ann Surg* 1997; 225: 51–60, discussion 62
- 5 Albrecht T, Blomley M, Bolondi L *et al.* Guidelines for the use of contrast agents in ultrasound. January 2004. *Ultraschall in Med* 2004; 25: 249–256
- 6 Arita J, Hasegawa K, Takahashi M *et al.* Correlation between contrast-enhanced intraoperative ultrasound using Sonazoid and histologic grade of resected hepatocellular carcinoma. *Am J Roentgenol* 2011; 196: 1314–1321
- 7 Averkiou M, Powers J, Skyba D *et al.* Ultrasound contrast imaging research. *Ultrasound Q* 2003; 19: 27–37
- 8 Barreiros AP, Piscaglia F, Dietrich CF. Contrast enhanced ultrasound for the diagnosis of hepatocellular carcinoma (HCC): Comments on AASLD guidelines. *J Hepatol* 2012; 57: 930–932
- 9 Bernatik T, Seitz K, Blank W *et al.* Unclear focal liver lesions in contrast-enhanced ultrasonography – lessons to be learned from the DEGUM multicenter study for the characterization of liver tumors. *Ultraschall in Med* 2010; 31: 577–581
- 10 Berstad AE, Brabrand K, Foss A. Clinical utility of microbubble contrast-enhanced ultrasound in the diagnosis of hepatic artery occlusion after liver transplantation. *Transpl Int* 2009; 22: 954–960
- 11 Bolondi L, Gaiani S, Celli N *et al.* Characterization of small nodules in cirrhosis by assessment of vascularity: the problem of hypovascular hepatocellular carcinoma. *Hepatology* 2005; 42: 27–34
- 12 Boozari B, Soudah B, Rifai K *et al.* Grading of hypervascular hepatocellular carcinoma using late phase of contrast enhanced sonography – a prospective study. *Dig Liver Dis* 2011; 43: 484–490
- 13 Bos LJ, Piek JJ, Spaan JA. Background subtraction from time-intensity curves in videodensitometry: a pitfall in flow assessment using contrast echocardiography. *Ultrasound Med Biol* 1995; 21: 1211–1218
- 14 Bruix J, Sherman M. Management of hepatocellular carcinoma. *Hepatology* 2005; 42: 1208–1236
- 15 Bruix J, Sherman M. Management of hepatocellular carcinoma: an update. *Hepatology* 2011; 53: 1020–1022
- 16 Bruix J, Sherman M, Llovet JM *et al.* Clinical management of hepatocellular carcinoma. Conclusions of the Barcelona-2000 EASL conference. European Association for the Study of the Liver. *J Hepatol* 2001; 35: 421–430
- 17 Cantisani V, Ricci P, Erturk M *et al.* Detection of hepatic metastases from colorectal cancer: prospective evaluation of gray scale US versus SonoVue(R) low mechanical index real time-enhanced US as compared with multidetector-CT or Gd-BOPTA-MRI. *Ultraschall in Med* 2010; 31: 500–505
- 18 Cao BS, Li XL, Li N *et al.* The nodular form of hepatic tuberculosis: contrast-enhanced ultrasonographic findings with pathologic correlation. *J Ultrasound Med* 2010; 29: 881–888
- 19 Catalano O, Sandomenico F, Nunziata A *et al.* Transient hepatic echogenicity difference on contrast-enhanced ultrasonography: sonographic sign and pitfall. *J Ultrasound Med* 2007; 26: 337–345
- 20 Catalano O, Sandomenico F, Raso MM *et al.* Low mechanical index contrast-enhanced sonographic findings of pyogenic hepatic abscesses. *Am J Roentgenol* 2004; 182: 447–450
- 21 Cervone A, Sardi A, Conaway GL. Intraoperative ultrasound (IOUS) is essential in the management of metastatic colorectal liver lesions. *Am Surg* 2000; 66: 611–615
- 22 Chami L, Lassau N, Malka D *et al.* Benefits of contrast-enhanced sonography for the detection of liver lesions: comparison with histologic findings. *Am J Roentgenol* 2008; 190: 683–690
- 23 Charnley RM, Morris DL, Dennison AR *et al.* Detection of colorectal liver metastases using intraoperative ultrasonography. *Br J Surg* 1991; 78: 45–48
- 24 Chen LD, Xu HX, Xie XY *et al.* Enhancement patterns of intrahepatic cholangiocarcinoma: comparison between contrast-enhanced ultrasound and contrast-enhanced CT. *Br J Radiol* 2008; 81: 881–889
- 25 Chen LD, Xu HX, Xie XY *et al.* Intrahepatic cholangiocarcinoma and hepatocellular carcinoma: differential diagnosis with contrast-enhanced ultrasound. *Eur Radiol* 2010; 20: 743–753
- 26 Chen MH, Dai Y, Yan K *et al.* The role of contrast-enhanced ultrasound on the diagnosis of small hepatocellular carcinoma (≤ 3 cm) in patients with cirrhosis. *Hepatol Res* 2006a; 35: 281–288
- 27 Chen MH, Wei Y, Yan K *et al.* Treatment strategy to optimize radiofrequency ablation for liver malignancies. *J Vasc Interv Radiol* 2006b; 17: 671–683
- 28 Chen MH, Yang W, Yan K *et al.* The role of contrast-enhanced ultrasound in planning treatment protocols for hepatocellular carcinoma before radiofrequency ablation. *Clin Radiol* 2007; 62: 752–760
- 29 Chen MH, Yang W, Yan K *et al.* Large liver tumors: protocol for radiofrequency ablation and its clinical application in 110 patients – mathematic model, overlapping mode, and electrode placement process. *Radiology* 2004; 232: 260–271
- 30 Choi D, Lim HK, Lee WJ *et al.* Early assessment of the therapeutic response to radio frequency ablation for hepatocellular carcinoma: utility of gray scale harmonic ultrasonography with a microbubble contrast agent. *J Ultrasound Med* 2003; 22: 1163–1172
- 31 Claudon M, Cosgrove D, Albrecht T *et al.* Guidelines and good clinical practice recommendations for contrast enhanced ultrasound (CEUS) – update 2008. *Ultraschall in Med* 2008; 29: 28–44
- 32 Clevert DA, Stickel M, Minaifar N *et al.* Contrast-enhanced ultrasound in liver transplant: first results and potential for complications in the postoperative period. *Clin Hemorheol Microcirc* 2009; 43: 83–94
- 33 Conlon R, Jacobs M, Dasgupta D *et al.* The value of intraoperative ultrasound during hepatic resection compared with improved preoperative magnetic resonance imaging. *Eur J Ultrasound* 2003; 16: 211–216
- 34 Cosgrove D, Harvey C. Clinical uses of microbubbles in diagnosis and treatment. *Med Biol Eng Comput* 2009; 47: 813–826
- 35 Cosgrove D, Lassau N. Imaging of perfusion using ultrasound. *Eur J Nucl Med Mol Imaging* 2010; 37 (Suppl 1): S65–S85
- 36 Crocetti L, Lencioni R, Debeni S *et al.* Targeting liver lesions for radiofrequency ablation: an experimental feasibility study using a CT-US fusion imaging system. *Invest Radiol* 2008; 43: 33–39
- 37 Dawson P, Cosgrove D, Grainger R. *Textbook of contrast media*. Oxford: ISIS Medical Media; 1999
- 38 De Giorgi U, Aliberti C, Benea G *et al.* Effect of angiosonography to monitor response during imatinib treatment in patients with metastatic gastrointestinal stromal tumors. *Clin Cancer Res* 2005; 11: 6171–6176
- 39 Dietrich CF, Averkiou MA, Correas JM *et al.* An EFSUMB introduction into dynamic contrast-enhanced ultrasound (DCE-US) for quantification of tumour perfusion. *Ultraschall in Med* 2012; 33: 344–351
- 40 Dietrich CF, Braden B, Hocke M *et al.* Improved characterisation of solitary solid pancreatic tumours using contrast enhanced transabdominal ultrasound. *J Cancer Res Clin Oncol* 2008; 134: 635–643
- 41 Dietrich CF, Ignee A, Hocke M *et al.* Pitfalls and artefacts using contrast enhanced ultrasound. *Z Gastroenterol* 2011; 49: 350–356
- 42 Dietrich CF, Kratzer W, Strobe D *et al.* Assessment of metastatic liver disease in patients with primary extrahepatic tumors by contrast-enhanced sonography versus CT and MRI. *World J Gastroenterol* 2006; 12: 1699–1705
- 43 Dietrich CF, Mertens JC, Braden B *et al.* Contrast-enhanced ultrasound of histologically proven liver hemangiomas. *Hepatology* 2007b; 45: 1139–1145
- 44 Dietrich CF, Schuessler G, Trojan J *et al.* Differentiation of focal nodular hyperplasia and hepatocellular adenoma by contrast-enhanced ultrasound. *Br J Radiol* 2005; 78: 704–707
- 45 Ding H, Wang WP, Huang BJ *et al.* Imaging of focal liver lesions: low-mechanical-index real-time ultrasonography with SonoVue. *J Ultrasound Med* 2005; 24: 285–297
- 46 Dodd GD 3rd, Memel DS, Zajko AB *et al.* Hepatic artery stenosis and thrombosis in transplant recipients: Doppler diagnosis with resistive index and systolic acceleration time. *Radiology* 1994; 192: 657–661
- 47 Ellsmere J, Kane R, Grinbaum R *et al.* Intraoperative ultrasonography during planned liver resections: why are we still performing it? *Surg Endosc* 2007; 21: 1280–1283

- 48 *Exuzides A, Main ML, Colby C et al.* A retrospective comparison of mortality in critically ill hospitalized patients undergoing echocardiography with and without an ultrasound contrast agent. *JACC Cardiovasc Imaging* 2010; 3: 578–585
- 49 *Fan ZH, Chen MH, Dai Y et al.* Evaluation of primary malignancies of the liver using contrast-enhanced sonography: correlation with pathology. *Am J Roentgenol* 2006; 186: 1512–1519
- 50 *Ferrara N, Kerbel RS.* Angiogenesis as a therapeutic target. *Nature* 2005; 438: 967–974
- 51 *Finlay IG, Meek D, Brunton F et al.* Growth rate of hepatic metastases in colorectal carcinoma. *Br J Surg* 1988; 75: 641–644
- 52 *Fioole B, de Haas RJ, Wicherts DA et al.* Additional value of contrast-enhanced intraoperative ultrasound for colorectal liver metastases. *Eur J Radiol* 2008; 67: 169–176
- 53 *Flint EW, Sumkin JH, Zajko AB et al.* Duplex sonography of hepatic artery thrombosis after liver transplantation. *Am J Roentgenol* 1988; 151: 481–483
- 54 *Fong Y.* Hepatic colorectal metastasis: current surgical therapy, selection criteria for hepatectomy, and role for adjuvant therapy. *Adv Surg* 2000; 34: 351–381
- 55 *Forner A, Vilana R, Ayuso C et al.* Diagnosis of hepatic nodules 20 mm or smaller in cirrhosis: Prospective validation of the noninvasive diagnostic criteria for hepatocellular carcinoma. *Hepatology* 2008; 47: 97–104
- 56 *Forsberg F, Kuruvilla B, Pascua MB et al.* Comparing contrast-enhanced color flow imaging and pathological measures of breast lesion vascularity. *Ultrasound Med Biol* 2008; 34: 1365–1372
- 57 *Foschi FG, Dall'Aglio AC, Marano G et al.* Role of contrast-enhanced ultrasonography in primary hepatic lymphoma. *J Ultrasound Med* 2010; 29: 1353–1356
- 58 *Gillams AR, Lees WR.* Five-year survival in 309 patients with colorectal liver metastases treated with radiofrequency ablation. *Eur Radiol* 2009; 19: 1206–1213
- 59 *Guibal A, Taillade L, Mule S et al.* Noninvasive contrast-enhanced US quantitative assessment of tumor microcirculation in a murine model: effect of discontinuing anti-VEGF therapy. *Radiology* 2010; 254: 420–429
- 60 *Hatanaka K, Kudo M, Minami Y et al.* Sonazoid-enhanced ultrasonography for diagnosis of hepatic malignancies: comparison with contrast-enhanced CT. *Oncology* 2008a; 75 (Suppl 1): 42–47
- 61 *Hatanaka K, Kudo M, Minami Y et al.* Differential diagnosis of hepatic tumors: value of contrast-enhanced harmonic sonography using the newly developed contrast agent. Sonazoid. *Intervirolgy* 2008b; 51 (Suppl 1): 61–69
- 62 *Hirche TO, Ignee A, Hirche H et al.* Evaluation of hepatic steatosis by ultrasound in patients with chronic hepatitis C virus infection. *Liver Int* 2007; 27: 748–757
- 63 *Huang D, Chen Y, Li K et al.* Hemodynamic changes on color Doppler flow imaging and intravenous contrast-enhanced ultrasound for assessing transplanted liver and early diagnosis of complications. *J Huazhong Univ Sci Technol Med Sci* 2008; 28: 284–286
- 64 *Iavarone M, Sangiovanni A, Forzenigo LV et al.* Diagnosis of hepatocellular carcinoma in cirrhosis by dynamic contrast imaging: the importance of tumor cell differentiation. *Hepatology* 2010; 52: 1723–1730
- 65 *Ignee A, Piscaglia F, Ott M et al.* A benign tumour of the liver mimicking malignant liver disease – cholangiocellular adenoma. *Scand J Gastroenterol* 2009; 44: 633–636
- 66 *Imoue T, Kudo M, Hatanaka K et al.* Imaging of hepatocellular carcinoma: qualitative and quantitative analysis of postvascular phase contrast-enhanced ultrasonography with sonazoid. Comparison with superparamagnetic iron oxide magnetic resonance images. *Oncology* 2008; 75 (Suppl 1): 48–54
- 67 *Jain A, Reyes J, Kashyap R et al.* Long-term survival after liver transplantation in 4,000 consecutive patients at a single center. *Ann Surg* 2000; 232: 490–500
- 68 *Jang HJ, Kim TK, Burns PN et al.* Enhancement patterns of hepatocellular carcinoma at contrast-enhanced US: comparison with histologic differentiation. *Radiology* 2007; 244: 898–906
- 69 *Jarnagin WR, Bach AM, Winston CB et al.* What is the yield of intraoperative ultrasonography during partial hepatectomy for malignant disease? *J Am Coll Surg* 2001; 192: 577–583
- 70 *Kessler T, Bayer M, Schwoppe C et al.* Compounds in clinical Phase III and beyond. *Recent Results Cancer Res* 2010; 180: 137–163
- 71 *Khawaja OA, Shaikh KA, Al-Mallah MH.* Meta-analysis of adverse cardiovascular events associated with echocardiographic contrast agents. *Am J Cardiol* 2010; 106: 742–747
- 72 *Kisaka Y, Hirooka M, Kumagi T et al.* Usefulness of contrast-enhanced ultrasonography with abdominal virtual ultrasonography in assessing therapeutic response in hepatocellular carcinoma treated with radiofrequency ablation. *Liver Int* 2006; 26: 1241–1247
- 73 *Konopke R, Bunk A, Kersting S.* Contrast-enhanced ultrasonography in patients with colorectal liver metastases after chemotherapy. *Ultraschall in Med* 2008; 29 (Suppl 4): S203–S209
- 74 *Konopke R, Kersting S, Bergert H et al.* Contrast-enhanced ultrasonography to detect liver metastases: A prospective trial to compare transcutaneous unenhanced and contrast-enhanced ultrasonography in patients undergoing laparotomy. *Int J Colorectal Dis* 2007; 22: 201–207
- 75 *Korenaga K, Korenaga M, Furukawa M et al.* Usefulness of Sonazoid contrast-enhanced ultrasonography for hepatocellular carcinoma: comparison with pathological diagnosis and superparamagnetic iron oxide magnetic resonance images. *J Gastroenterol* 2009; 44: 733–741
- 76 *Kudo M.* The 2008 Okuda lecture: Management of hepatocellular carcinoma: from surveillance to molecular targeted therapy. *J Gastroenterol Hepatol* 2010; 25: 439–452
- 77 *Kudo M, Hatanaka K, Kumada T et al.* Double-contrast ultrasound: a novel surveillance tool for hepatocellular carcinoma. *Am J Gastroenterol* 2011a; 106: 368–370
- 78 *Kudo M, Hatanaka K, Maekawa K.* Newly developed novel ultrasound technique, defect reperfusion ultrasound imaging, using sonazoid in the management of hepatocellular carcinoma. *Oncology* 2010; 78 (Suppl 1): 40–45
- 79 *Kudo M, Izumi N, Kokudo N et al.* Management of hepatocellular carcinoma in Japan: Consensus-Based Clinical Practice Guidelines proposed by the Japan Society of Hepatology (JSH) 2010 updated version. *Dig Dis* 2011b; 29: 339–364
- 80 *Kudo M, Okanoue T.* Management of hepatocellular carcinoma in Japan: consensus-based clinical practice manual proposed by the Japan Society of Hepatology. *Oncology* 2007; 72 (Suppl 1): 2–15
- 81 *Kurt M, Shaikh KA, Peterson L et al.* Impact of contrast echocardiography on evaluation of ventricular function and clinical management in a large prospective cohort. *J Am Coll Cardiol* 2009; 53: 802–810
- 82 *Lamuraglia M, Escudier B, Chami L et al.* To predict progression-free survival and overall survival in metastatic renal cancer treated with sorafenib: pilot study using dynamic contrast-enhanced Doppler ultrasound. *Eur J Cancer* 2006; 42: 2472–2479
- 83 *Langnas AN, Marujo W, Stratta RJ et al.* Vascular complications after orthotopic liver transplantation. *Am J Surg* 1991; 161: 76–82; discussion 83
- 84 *Larsen LP, Rosenkilde M, Christensen H et al.* The value of contrast-enhanced ultrasonography in detection of liver metastases from colorectal cancer: a prospective double-blinded study. *Eur J Radiol* 2007; 62: 302–307
- 85 *Lassau N, Chami L, Chebil M et al.* Dynamic contrast-enhanced ultrasonography (DCE-US) and anti-angiogenic treatments. *Discov Med* 2011; 11: 18–24
- 86 *Lassau N, Chami L, Koscielny S et al.* Quantitative functional imaging by Dynamic Contrast Enhanced Ultrasonography (DCE-US) in GIST patients treated with masatinib. *Invest New Drugs* 2012; 30: 765–771
- 87 *Lassau N, Koscielny S, Albiges L et al.* Metastatic renal cell carcinoma treated with sunitinib: early evaluation of treatment response using dynamic contrast-enhanced ultrasonography. *Clin Cancer Res* 2010a; 16: 1216–1225
- 88 *Lassau N, Koscielny S, Chami L et al.* Advanced Hepatocellular Carcinoma: Early Evaluation of Response to Bevacizumab Therapy at Dynamic Contrast-enhanced US with Quantification—Preliminary Results. *Radiology* 2010b; 258: 291–300
- 89 *Lassau N, Lamuraglia M, Chami L et al.* Gastrointestinal stromal tumors treated with imatinib: monitoring response with contrast-enhanced sonography. *Am J Roentgenol* 2006; 187: 1267–1273
- 90 *Leen E, Ceccotti P, Moug SJ et al.* Potential value of contrast-enhanced intraoperative ultrasonography during partial hepatectomy for metastases: an essential investigation before resection? *Ann Surg* 2006; 243: 236–240
- 91 *Lencioni R, Llovet JM.* Modified RECIST (mRECIST) assessment for hepatocellular carcinoma. *Semin Liver Dis* 2010; 30: 52–60
- 92 *Leoni S, Piscaglia F, Golfieri R et al.* The impact of vascular and nonvascular findings on the noninvasive diagnosis of small hepatocellular

- carcinoma based on the EASL and AASLD criteria. *Am J Gastroenterol* 2010; 105: 599–609
- 93 Li N, Ding H, Fan P et al. Intrahepatic transit time predicts liver fibrosis in patients with chronic hepatitis B: quantitative assessment with contrast-enhanced ultrasonography. *Ultrasound Med Biol* 2010; 36: 1066–1075
 - 94 Lim AK, Taylor-Robinson SD, Patel N et al. Hepatic vein transit times using a microbubble agent can predict disease severity non-invasively in patients with hepatitis C. *Gut* 2005; 54: 128–133
 - 95 Liu GJ, Lu MD, Xie XY et al. Real-time contrast-enhanced ultrasound imaging of infected focal liver lesions. *J Ultrasound Med* 2008a; 27: 657–666
 - 96 Liu JB, Wansaicheong G, Merton DA et al. Canine prostate: contrast-enhanced US-guided radiofrequency ablation with urethral and neurovascular cooling—initial experience. *Radiology* 2008b; 247: 717–725
 - 97 Liu Z, Lobo SM, Humphries S et al. Radiofrequency tumor ablation: insight into improved efficacy using computer modeling. *Am J Roentgenol* 2005; 184: 1347–1352
 - 98 Livraghi T, Goldberg SN, Lazzaroni S et al. Hepatocellular carcinoma: radio-frequency ablation of medium and large lesions. *Radiology* 2000; 214: 761–768
 - 99 Lu Q, Zhong XF, Huang ZX et al. Role of contrast-enhanced ultrasound in decision support for diagnosis and treatment of hepatic artery thrombosis after liver transplantation. *Eur J Radiol* 2012; 81: e338–e343
 - 100 Luo Y, Fan YT, Lu Q et al. CEUS: a new imaging approach for post-operative vascular complications after right-lobe LDLT. *World J Gastroenterol* 2009; 15: 3670–3675
 - 101 Main ML, Goldman JH, Grayburn PA. Ultrasound contrast agents: balancing safety versus efficacy. *Expert Opin Drug Saf* 2009; 8: 49–56
 - 102 Main ML, Ryan AC, Davis TE et al. Acute mortality in hospitalized patients undergoing echocardiography with and without an ultrasound contrast agent (multicenter registry results in 4,300,966 consecutive patients). *Am J Cardiol* 2008; 102: 1742–1746
 - 103 Mandry D, Bressenot A, Galloy MA et al. Contrast-enhanced ultrasound in fibro-lamellar hepatocellular carcinoma: a case report. *Ultraschall in Med* 2007; 28: 547–552
 - 104 Maruyama H, Takahashi M, Ishibashi H et al. Ultrasound-guided treatments under low acoustic power contrast harmonic imaging for hepatocellular carcinomas undetected by B-mode ultrasonography. *Liver Int* 2009; 29: 708–714
 - 105 Matsui O. Detection and characterization of hepatocellular carcinoma by imaging. *Clin Gastroenterol Hepatol* 2005; 3: S136–S140
 - 106 Mazzoni G, Napoli A, Mandetta S et al. Intra-operative ultrasound for detection of liver metastases from colorectal cancer. *Liver Int* 2008; 28: 88–94
 - 107 Minami Y, Kudo M, Chung H et al. Contrast harmonic sonography-guided radiofrequency ablation therapy versus B-mode sonography in hepatocellular carcinoma: prospective randomized controlled trial. *Am J Roentgenol* 2007; 188: 489–494
 - 108 Moriyasu F, Itoh K. Efficacy of perflubutane microbubble-enhanced ultrasound in the characterization and detection of focal liver lesions: phase 3 multicenter clinical trial. *Am J Roentgenol* 2009; 193: 86–95
 - 109 Mork H, Ignee A, Schuessler G et al. Analysis of neuroendocrine tumour metastases in the liver using contrast enhanced ultrasonography. *Scand J Gastroenterol* 2007; 42: 652–662
 - 110 Nakano H, Ishida Y, Hatakeyama T et al. Contrast-enhanced intraoperative ultrasonography equipped with late Kupffer-phase image obtained by sonazoid in patients with colorectal liver metastases. *World J Gastroenterol* 2008; 14: 3207–3211
 - 111 Omata M, Lesmana LA, Tateishi R et al. Asian Pacific Association for the Study of the Liver consensus recommendations on hepatocellular carcinoma. *Hepatol Int* 2010; 4: 439–474
 - 112 Peronneau P, Lassau N, Leguerney I et al. Contrast ultrasonography: necessity of linear data processing for the quantification of tumor vascularization. *Ultraschall in Med* 2010; 31: 370–378
 - 113 Piscaglia F, Bolondi L. The safety of SonoVue in abdominal applications: retrospective analysis of 23188 investigations. *Ultrasound Med Biol* 2006; 32: 1369–1375
 - 114 Piscaglia F, Corradi F, Mancini M et al. Real time contrast enhanced ultrasonography in detection of liver metastases from gastrointestinal cancer. *BMC Cancer* 2007; 7: 171
 - 115 Piscaglia F, Gianstefani A, Ravaoli M et al. Criteria for diagnosing benign portal vein thrombosis in the assessment of patients with cirrhosis and hepatocellular carcinoma for liver transplantation. *Liver Transpl* 2010; 16: 658–667
 - 116 Piscaglia F, Nolsoe C, Dietrich CF et al. The EFSUMB Guidelines and Recommendations on the Clinical Practice of Contrast Enhanced Ultrasound (CEUS): update 2011 on non-hepatic applications. *Ultraschall in Med* 2011; 33: 33–59
 - 117 Piskunowicz M, Kosiak W, Irga N. Primum non nocere? Why can't we use second generation ultrasound contrast agents for the examination of children? *Ultraschall in Med* 2011; 32: 83–86
 - 118 Qiang L, Yan L, Chao-Xin Y et al. Value of contrast enhanced intraoperative ultrasound for cirrhotic patients with hepatocellular carcinoma. A report of 20 cases. *World J Gastroenterol* 2008; 14: 4005–4010
 - 119 Quaiá E, D'Onofrio M, Palumbo A et al. Comparison of contrast-enhanced ultrasonography versus baseline ultrasound and contrast-enhanced computed tomography in metastatic disease of the liver: diagnostic performance and confidence. *Eur Radiol* 2006; 16: 1599–1609
 - 120 Ridolfi F, Abbattista T, Marini F et al. Contrast-enhanced ultrasound to evaluate the severity of chronic hepatitis C. *Dig Liver Dis* 2007; 39: 929–935
 - 121 Rossi S, Rosa L, Ravetta V et al. Contrast-enhanced versus conventional and color Doppler sonography for the detection of thrombosis of the portal and hepatic venous systems. *Am J Roentgenol* 2006; 186: 763–773
 - 122 Sangiovanni A, Manini MA, Iavarone M et al. The diagnostic and economic impact of contrast imaging techniques in the diagnosis of small hepatocellular carcinoma in cirrhosis. *Gut* 2010; 59: 638–644
 - 123 Sasaki A, Kai S, Iwashita Y et al. Microsatellite distribution and indication for locoregional therapy in small hepatocellular carcinoma. *Cancer* 2005; 103: 299–306
 - 124 Scheele J, Stang R, Altendorf-Hofmann A et al. Resection of colorectal liver metastases. *World J Surg* 1995; 19: 59–71
 - 125 Schlottmann K, Klebl F, Zorger N et al. Contrast-enhanced ultrasound allows for interventions of hepatic lesions which are invisible on conventional B-mode. *Z Gastroenterol* 2004; 42: 303–310
 - 126 Schuessler G, Fellbaum C, Fauth F et al. The inflammatory pseudotumour – an unusual liver tumour. *Ultraschall in Med* 2006; 27: 273–279
 - 127 Seitz K, Bernatik T, Strobel D et al. Contrast-enhanced ultrasound (CEUS) for the characterization of focal liver lesions in clinical practice (DEGUM Multicenter Trial): CEUS vs. MRI – a prospective comparison in 269 patients. *Ultraschall in Med* 2010; 31: 492–499
 - 128 Seitz K, Greis C, Schuler A et al. Frequency of tumor entities among liver tumors of unclear etiology initially detected by sonography in the noncirrhotic or cirrhotic livers of 1349 patients. Results of the DEGUM multicenter study. *Ultraschall in Med* 2011; 32: 598–603
 - 129 Shaw AS, Ryan SM, Beese RC et al. Ultrasound of non-vascular complications in the post liver transplant patient. *Clin Radiol* 2003; 58: 672–680
 - 130 Shiozawa K, Watanabe M, Takayama R et al. Evaluation of local recurrence after treatment for hepatocellular carcinoma by contrast-enhanced ultrasonography using Sonazoid: comparison with dynamic computed tomography. *J Clin Ultrasound* 2010; 38: 182–189
 - 131 Sidhu PS, Shaw AS, Ellis SM et al. Microbubble ultrasound contrast in the assessment of hepatic artery patency following liver transplantation: role in reducing frequency of hepatic artery arteriography. *Eur Radiol* 2004; 14: 21–30
 - 132 Simpson DH, Chin CT, Burns PN. Pulse inversion Doppler: a new method for detecting nonlinear echoes from microbubble contrast agents. *IEEE Trans on Ultrasonics, Ferroelectrics, and Freq Control* 1999; 46: 372–382
 - 133 Skyba DM, Price RJ, Linka AZ et al. Direct in vivo visualization of intravascular destruction of microbubbles by ultrasound and its local effects on tissue. *Circulation* 1998; 98: 290–293
 - 134 Sorrentino P, D'Angelo S, Tarantino L et al. Contrast-enhanced sonography versus biopsy for the differential diagnosis of thrombosis in hepatocellular carcinoma patients. *World J Gastroenterol* 2009; 15: 2245–2251
 - 135 Strobel D, Kleinecke C, Hansler J et al. Contrast-enhanced sonography for the characterisation of hepatocellular carcinomas—correlation with histological differentiation. *Ultraschall in Med* 2005; 26: 270–276
 - 136 Strobel D, Seitz K, Blank W et al. Contrast-enhanced ultrasound for the characterization of focal liver lesions—diagnostic accuracy in clinical practice (DEGUM multicenter trial). *Ultraschall in Med* 2008; 29: 499–505

- 137 *Su HL, Qian YQ, Wei ZR et al.* Real-time myocardial contrast echocardiography in rat: infusion versus bolus administration. *Ultrasound Med Biol* 2009; 35: 748–755
- 138 *Szabo T.* Diagnostic Ultrasound Imaging. Insite Out (Biomedical Engineering) ISBN 0125801452. Ed./Academic Press 2004
- 139 *Therasse P, Arbuck SG, Eisenhauer EA et al.* New guidelines to evaluate the response to treatment in solid tumors. European Organization for Research and Treatment of Cancer, National Cancer Institute of the United States, National Cancer Institute of Canada. *J Natl Cancer Inst* 2000; 92: 205–216
- 140 *Tiemann K, Lohmeier S, Kuntz S et al.* Real-time contrast echo assessment of myocardial perfusion at low emission power: First experimental and clinical results using power pulse inversion imaging. *Echocardiography* 1999; 16: 799–809
- 141 *Torzilli G, Del Fabbro D, Palmisano A et al.* Contrast-enhanced intraoperative ultrasonography during hepatectomies for colorectal cancer liver metastases. *J Gastrointest Surg* 2005; 9: 1148–1153; discussion 53–54
- 142 *Torzilli G, Del Fabbro D, Palmisano A et al.* Contrast-enhanced intraoperative ultrasonography: a valuable and not any more monocentric diagnostic technique performed in different ways. *Ann Surg* 2007; 245: 152–153; author reply 153.
- 143 *Trillaud H, Bruel JM, Valette PJ et al.* Characterization of focal liver lesions with SonoVue-enhanced sonography: international multicenter-study in comparison to CT and MRI. *World J Gastroenterol* 2009; 15: 3748–3756
- 144 *Vilana R, Forner A, Bianchi L et al.* Intrahepatic peripheral cholangiocarcinoma in cirrhosis patients may display a vascular pattern similar to hepatocellular carcinoma on contrast-enhanced ultrasound. *Hepatology* 2010; 51: 2020–2029
- 145 *Wang Z, Xu HX, Xie XY et al.* Imaging features of hepatic angiomyolipomas on real-time contrast-enhanced ultrasound. *Br J Radiol* 2010; 83: 411–418
- 146 *Wei K, Jayaweera AR, Firoozan S et al.* Quantification of myocardial blood flow with ultrasound-induced destruction of microbubbles administered as a constant venous infusion. *Circulation* 1998; 97: 473–483
- 147 *Wilson SR, Burns PN.* An algorithm for the diagnosis of focal liver masses using microbubble contrast-enhanced pulse-inversion sonography. *Am J Roentgenol* 2006; 186: 1401–1412
- 148 *Wilson SR, Kim TK, Jang HJ et al.* Enhancement patterns of focal liver masses: discordance between contrast-enhanced sonography and contrast-enhanced CT and MRI. *Am J Roentgenol* 2007; 189: W7–W12
- 149 World Health Organisation Offset Publication. WHO Handbook for Reporting Results of Cancer Treatment. Geneva, Switzerland: ISBN 92 4 170048 3. Ed World Health Organisation, 1979.
- 150 *Wu W, Chen MH, Yin SS et al.* The role of contrast-enhanced sonography of focal liver lesions before percutaneous biopsy. *Am J Roentgenol* 2006; 187: 752–761
- 151 *Xu HX, Liu GJ, Lu MD et al.* Characterization of small focal liver lesions using real-time contrast-enhanced sonography: diagnostic performance analysis in 200 patients. *J Ultrasound Med* 2006a; 25: 349–361
- 152 *Xu HX, Lu MD, Liu GJ et al.* Imaging of peripheral cholangiocarcinoma with low-mechanical index contrast-enhanced sonography and SonoVue: initial experience. *J Ultrasound Med* 2006b; 25: 23–33
- 153 *Yanagisawa K, Moriyasu F, Miyahara T et al.* Phagocytosis of ultrasound contrast agent microbubbles by Kupffer cells. *Ultrasound Med Biol* 2007; 33: 318–325
- 154 *Zheng RQ, Mao R, Ren J et al.* Contrast-enhanced ultrasound for the evaluation of hepatic artery stenosis after liver transplantation: potential role in changing the clinical algorithm. *Liver Transpl* 2010; 16: 729–735