Large-bowel obstruction caused by pancreatic tail cancer

A 60-year-old man presented to our hospital with abdominal pain. Enhanced abdominal computed tomography (CT) revealed a well-demarcated, low-density tumor in the tail of the pancreas (**Fig. 1**). ^{18}F-fluorodeoxyglucose positron emission tomography (FDG-PET) showed high uptake in the tumor (standardized uptake value 17) (**Fig. 2**). Colonoscopy revealed a mass in the descending colon causing marked stenosis (**Fig. 3**). Consistent with this finding, the colonoscope could not pass through the obstructed segment. CT colonography revealed an apple-core lesion in the descending colon (**Fig. 4**), and histological examination of the biopsy samples revealed poorly differentiated adenocarcinoma. A few days later, the patient was admitted with abdominal pain due to acute large-bowel obstruction. Emergency distal pancreatectomy, left hemicolectomy, and partial adrenalectomy and lymph node dissection were carried out. Gross examination of the resected specimen showed a submucosal tumor of the colon with the majority of the tumor residing in the pancreas (**Fig. 5**). The patient was diagnosed as having anaplastic pancreatic cancer with osteoclast-like giant cells. Postoperative follow-up at 2 years showed no recurrence.

High accumulation of FDG in FDG-PET is somewhat rare in pancreatic ductal adenocarcinoma due to the scattered distribution of cancer cells [1]. Thus, pancreatic tumors with high uptake should be considered atypical. Anaplastic pancreatic carcinoma is a solid-type tumor with poor prognosis; however, the presence of osteoclast-like giant cells is associated with relatively good prognosis [2]. Acute abdominal pain due to large-bowel obstruction is a rare symptom of pancreatic cancer, and only four cases have been reported to date [3], all of whom died within several months. Thus, extended resection is not recommended in patients with pancreatic cancer presenting with large-bowel obstruction. However, in patients with colonic obstruction due to pancreatic cancer and atypical radiological findings, aggressive surgery should be considered to improve prognosis.

Fig. 1 Abdominal enhanced computed tomography (CT) view of a well-demarcated, low-density tumor, about 4.5 cm in diameter, in the tail of the pancreas in a 60-year-old man with abdominal pain.

Fig. 2 ^{18}F-fluorodeoxyglucose positron emission tomography (FDG-PET) image showing high uptake in the tumor in the pancreatic tail.

Endoscopy_UCTN_Code_CCL_1AD_2AJ

Competing interests: None

This document was downloaded for personal use only. Unauthorized distribution is strictly prohibited.

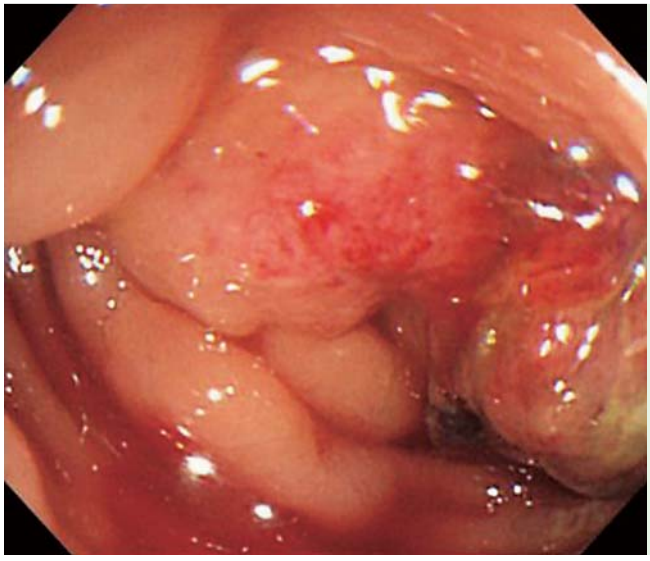

Fig. 3 Colonoscopic view showing tumorous obstruction in the descending colon.

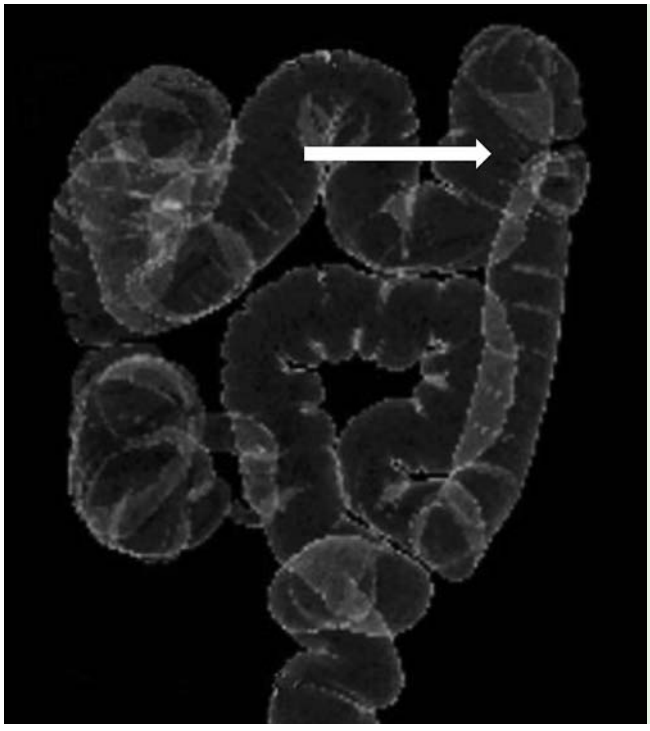

Fig. 4 Computed tomography (CT) colonography showing severe stenosis in the descending colon.

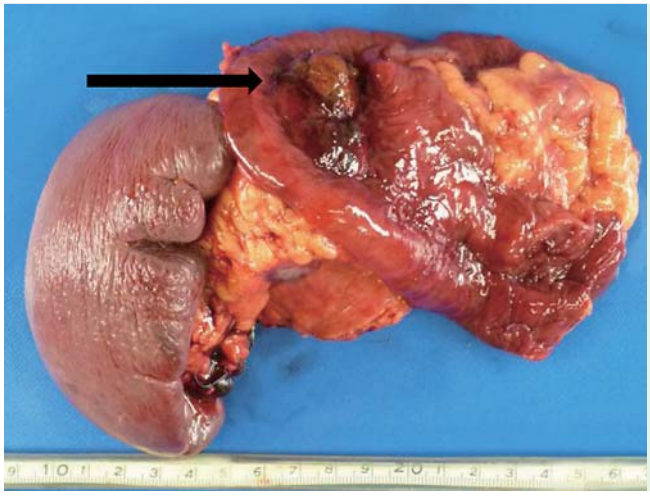

Fig. 5 Resected specimen showing a submucosal tumor of the colon with the majority of the tumor residing in the pancreas.

K. Izuishi[1], T. Sano[1], Y. Okamoto[1], H. Mori[2], M. Oryu[2], T. Maeta[2], K. Ebara[1]

[1] Department of Gastroenterological Surgery, Federation of Public Services and Affiliated Personnel Aid Associations, Takamatsu Hospital, Takamatsu, Kagawa, Japan

[2] Department of Internal Medicine of Gastroenterology, Federation of Public Services and Affiliated Personnel Aid Associations, Takamatsu Hospital, Takamatsu, Kagawa, Japan

References

1 *Izuishi K, Yamamoto Y, Sano T* et al. Impact of 18-fluorodeoxyglucose positron emission tomography on the management of pancreatic cancer. J Gastrointest Surg 2010; 14: 1151 – 1158

2 *Strobel O, Hartwig W, Bergmann F* et al. Anaplastic pancreatic cancer: Presentation, surgical management, and outcome. Surgery 2011; 149: 200 – 208

3 *Griffin R, Villas B, Davis C* et al. Carcinoma of the tail of the pancreas presenting as acute abdomen. JOP 2012; 13: 58 – 60

Bibliography

DOI http://dx.doi.org/10.1055/s-0032-1310075
Endoscopy 2012; 44: E368–E369
© Georg Thieme Verlag KG
Stuttgart · New York
ISSN 0013-726X

Corresponding author

K. Izuishi
Department of Gastroenterological Surgery
Federation of Public Services and Affiliated Personnel Aid Associations
Takamatsu Hospital
4-18 Tenjinmae
Takamatsu
Kagawa 760-0018
Japan
Fax: +81-87-8350793
izuishi@kkr-ta-hp.gr.jp

This document was downloaded for personal use only. Unauthorized distribution is strictly prohibited.