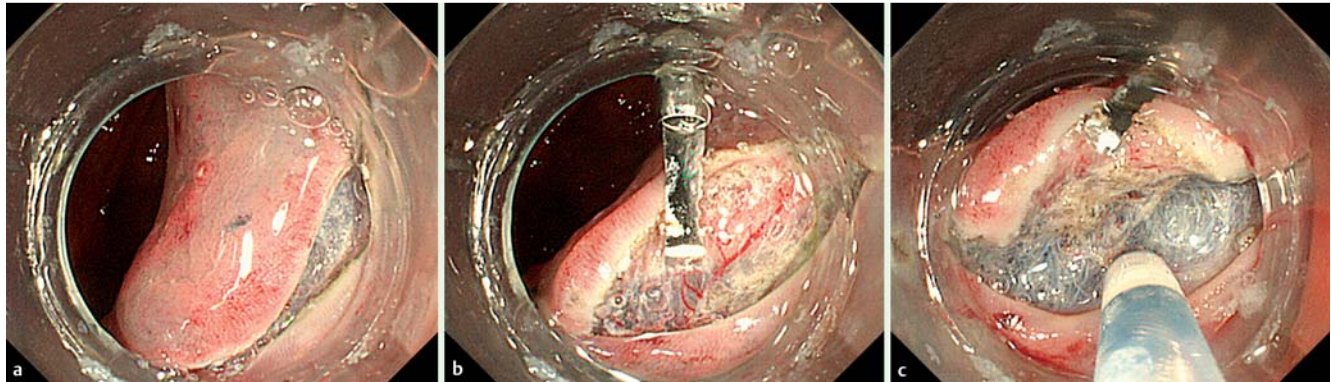


## Endoscopic submucosal dissection using endoclips to assist in mucosal flap formation (novel technique: “clip flap method”)



**Fig. 1** a The mucosa around the neoplasm was partially incised and the submucosa cut deeply after injection of saline or diluted sodium hyaluronate into the submucosal layer. b, c The attachment fitted to the distal end of the endoscope was slipped under the endoclip, and then the mucosa and submucosa were lifted by the endoclip.

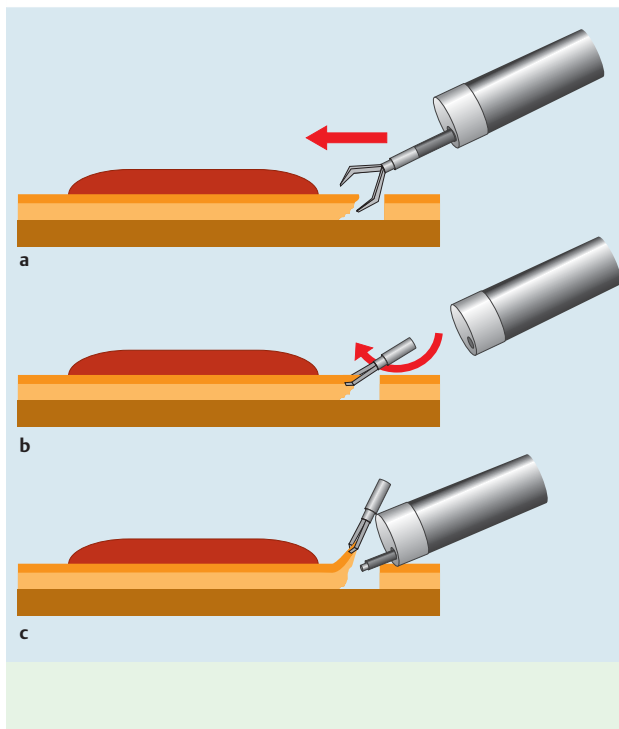
Endoscopic submucosal dissection (ESD) requires a high skill level due to poor visualization and instability in the cutting area. Mucosal flap formation after beginning submucosal dissection is the most difficult part of the procedure but improves visibility in the cutting area and allows for easier dissection, because the mucosal flap can be lifted with an attachment fitted to the endoscope. Although

traction systems for ESD were recently reported [1–5], these methods are complicated and not widely employed. We designed a simple “clip flap method” using the endoclip as a substitute for the mucosal flap until it is formed.

ESD was performed for 51 cases of superficial gastrointestinal neoplasms (24 colorectal neoplasms, 23 gastric neoplasms, 4 esophageal neoplasms) in our hospital, as

follows. After circumferential incision of the mucosa (● Fig. 1 a) was performed, the edge of the exfoliated mucosa was clipped with one or more endoclips (Olympus, Tokyo, Japan) (● Fig. 2 a, b), attached in an upright manner, so that the endoscope attachment could easily pass underneath. The endoscope attachment was slipped under the endoclip as well as under the mucosal flap then the mucosa and submucosa were pulled up by the endoclip (● Fig. 1 b). As a result, the cutting area was clearly visualized, allowing the submucosal layer to be dissected more safely and efficiently by countertraction using the endoclip (● Fig. 1 c and ● Fig. 2 c). The mucosal flap could then be formed more quickly. All tumors were resected en bloc, without perforation or severe uncontrollable bleeding. Respiratory fluctuation in the cutting area was reduced and the visual field stabilized, because the attachment was fixed by the endoclip.

The clip flap method was quite effective for most cases and especially effective for colorectal neoplasms, for which it is often difficult to form a mucosal flap when incising (● Video 1). The endoclip weight could be used for countertraction, and the direction of gravity controlled by a postural change. The clip flap method is simple and very effectively enables formation of the mucosal flap.



**Fig. 2** a The edge of the exfoliated mucosa is clipped with the endoclip from the diagonal top. b, c The attachment fitted to the distal end of the endoscope is slipped under the endoclip, and then the mucosa and submucosa are lifted by the endoclip. This allows for clear visualization of the submucosal layer and easier and safer dissection with the endoknife. (If at first the endoscope attachment cannot be easily slipped under the endoclip, this can be done after the endoclip is lifted with the endoknife, or the tail end of the endoclip falls towards the intestinal lumen following a postural change.).

**Video 1**

The “clip flap method” in use in dissection of a superficial colorectal tumor (laterally spreading tumor, granular type, nodular mixed type – LST-G-NM – located in the cecum).

Endoscopy\_UCTN\_Code\_TTT\_1AO\_2AG

**Competing interests:** None

**K. Yamamoto, S. Hayashi, T. Nakabori, M. Shibuya, M. Ichiba, M. Inada**

Department of Gastroenterology,  
Toyonaka Municipal Hospital, Osaka, Japan

**References**

- 1 *Saito Y, Emura F, Matsuda T et al.* A new sinker-assisted endoscopic submucosal dissection for colorectal cancer. *Gastrointestinal Endosc* 2005; 62: 297–301
- 2 *Sakamoto N, Osada T, Shibuya T et al.* The facilitation of a new traction device (S-O clip) assisting endoscopic submucosal dissection for superficial colorectal neoplasms. *Endoscopy* 2008; 40: E94–E95
- 3 *Gotoda T, Oda I, Tamakawa K et al.* Prospective clinical trial of magnetic anchor-guided endoscopic submucosal dissection for large early gastric cancer (with videos). *Gastrointestinal Endosc* 2009; 69: 10–15
- 4 *Ueki M, Ikebuchi Y, Matsuoka H et al.* Endoscopic submucosal dissection assisted by novel “clip fishing method” (with video). *Endoscopy* 2010; 42: E277–E278
- 5 *Tomiki Y, Ishiyama S, Sugimoto K et al.* Colorectal endoscopic submucosal dissection by using latex-band traction. *Endoscopy* 2011; 43: E250–E251

**Bibliography**

**DOI** <http://dx.doi.org/10.1055/s-0032-1309860>  
*Endoscopy* 2012; 44: E334–E335  
 © Georg Thieme Verlag KG  
 Stuttgart · New York  
 ISSN 0013-726X

**Corresponding author**

**K. Yamamoto, MD, PhD**  
 Toyonaka Municipal Hospital  
 4-14-1 Shibahara-cho  
 Toyonaka  
 Osaka 560-8565  
 Japan  
 Fax: +81-6-68583531  
[yamamotok@chp.toyonaka.osaka.jp](mailto:yamamotok@chp.toyonaka.osaka.jp)