Esophageal natural killer (NK)/T cell lymphoma of true natural killer cell origin

A 53-year-old man with no prior medical history was transferred to our hospital because of a 2-month history of dysphagia with throat pain.

A complete blood count showed hemoglobin 14.2 g/dL, and white blood cell count 11 890/mL, and other laboratory findings were within normal limits. An enhanced computed tomography (CT) scan showed diffuse thickening of the esophageal wall without regional lymphadenopathy. An endoscopic examination revealed several well defined, variable-sized erosions and ulcers on the proximal esophagus (**Fig. 1 a**) and distal esophagus (**Fig. 1 b**). Endoscopic ultrasound (EUS) was performed to evaluate the esophageal wall. EUS showed a hypoechoic and homogeneous thickness along the entire length of the esophagus (**Fig. 2**). Endoscopic biopsy specimens revealed many neoplastic cells in the extensive necrotic tissue (**Fig. 3**) that showed positivity for CD3 (**Fig. 4**), CD56 (**Fig. 5**), and UCHL-1, and were negative for CD4, CD5, CD8, CD20, CD79a, and EBER-1. These findings were consistent with esophageal involvement by extranodal natural killer (NK)/T cell lymphoma of true natural killer cell origin.

The patient received two cycles of systemic chemotherapy with concurrent radiotherapy. However, his general condition gradually became worse and he died 4 months after admission.

The esophagus is the least commonly involved gastrointestinal organ, accounting for less than 1% of patients with primary gastrointestinal lymphoma [1]. Extranodal natural killer (NK)/T cell lymphoma of true natural killer cell origin is extremely rare, with only a few case reports in the literature [2,3]. In this case, the endoscopic picture showed mucosal erythema, a mass with ulceration, and wall thickness, similarly to previous reports of esophageal lymphoma. In a previous study, esophageal lymphoma showed lymphomatous involvement of the gastrointestinal wall to produce a typical hypoechoic transmural thickening [4], such as in this case. However, another report described imaging of a submucosal, heterogeneous, mainly hyperechoic mass [2].

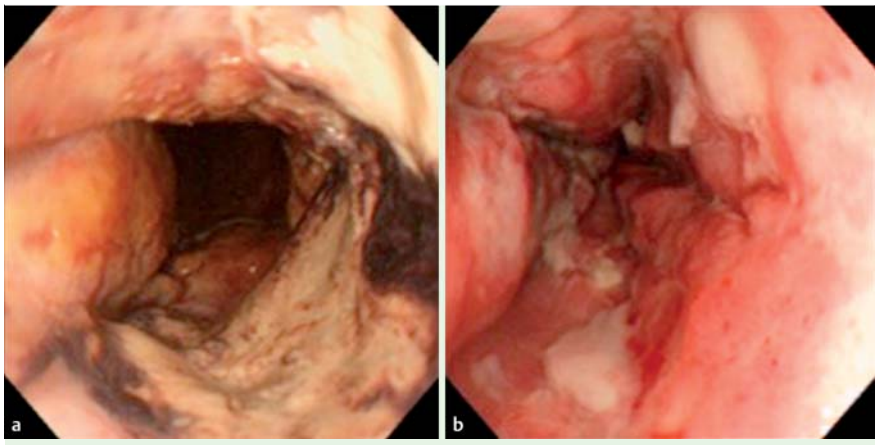

Fig. 1 Endoscopic findings of esophageal lymphoma. An endoscopic examination revealed several well defined, variable-sized ulcers with white exudate in the esophagus: **a** proximal; **b** distal.

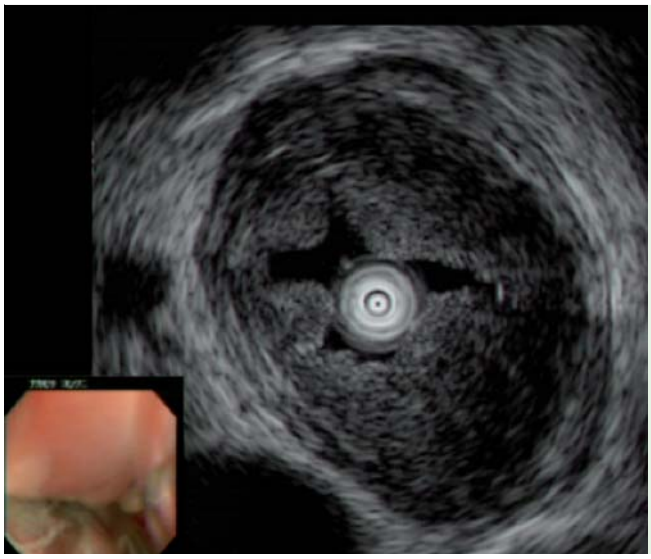

Fig. 2 Endoscopic ultrasound showing a transmural thickening of the esophageal wall, and heterogeneous, mainly hypoechoic, submucosal lesions.

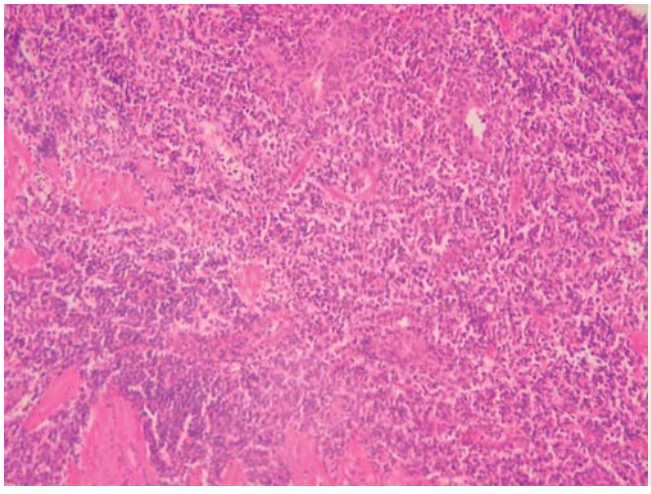

Fig. 3 Histopathological findings for endoscopic biopsy specimens.

This document was downloaded for personal use only. Unauthorized distribution is strictly prohibited.

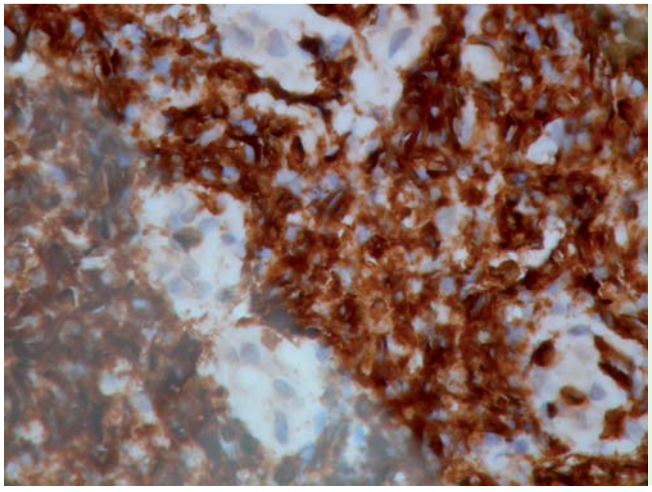

Fig. 4 Expression of CD3 antigen by lymphoid cells.

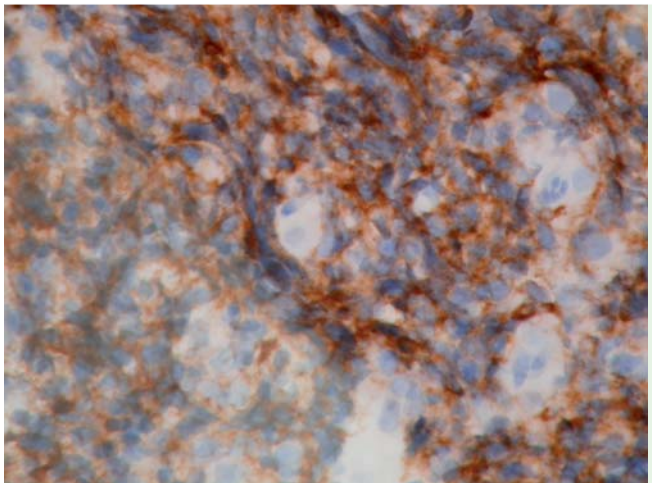

Fig. 5 Expression of CD56 antigen by lymphoid cells.

Endoscopy_UCTN_Code_CCL_1AB_2AC_3AB

Competing interests: None

S. Fujihara, H. Mori, H. Kobara, N. Nishiyama, M. Kobayashi, T. Masaki

Department of Gastroenterology and Neurology, Kagawa University, Faculty of Medicine, Kagawa, Japan

References

1 *Oğuzkurt L, Karabulut N, Cakmakci E* et al. Primary non-Hodgkin's lymphoma of the esophagus. Abdom Imaging 1997; 22: 8 – 10
2 *Kalogeropoulos IV, Chalazonitis AN, Tsolaki S* et al. A case of primary isolated non-Hodgkin's lymphoma of the esophagus in an immunocompetent patient. World J Gastroenterol 2009; 15: 1901 – 1903
3 *Totonchi KF, Engel G, Weisenberg E* et al. Testicular natural killer/t-cell lymphoma, nasal type, of true natural killer-cell origin. Arch Pathol Lab Med 2002; 126: 1527 – 1529
4 *Luigi B, Roberto DG, Vittorio S* et al. Primary non-Hodgkin's T-cell lymphoma of the esophagus. Dig Dis Science 1990; 35: 1426 – 1430

Bibliography

DOI http://dx.doi.org/10.1055/s-0032-1309852
Endoscopy 2014; 46: E77–E78
© Georg Thieme Verlag KG
Stuttgart · New York
ISSN 0013-726X

Corresponding author

S. Fujihara, MD
Department of Gastroenterology and Neurology
Faculty of Medicine
Kagawa University
1750-1 Ikenobe
Miki-cho, Kita-gun
Kagawa 761-0793
Japan
Fax: +81-87-8912158
sannai@kms.ac.jp

This document was downloaded for personal use only. Unauthorized distribution is strictly prohibited.