A peculiar case of autoimmune pancreatitis and sclerosing cholangitis

A 65-year-old man presented with recurrent abdominal pain and slight weight loss. Computed tomography (CT) and endoscopic ultrasound (EUS) revealed a hypodense, partially cystic mass located in the pancreatic body and tail that raised the suspicion of pancreatic cancer (**Fig. 1**). No distant metastases were detected and the patient underwent surgical resection of the mass and splenectomy, which was complicated by a bleeding splenic artery aneurysm. Surprisingly, only massive inflammation of the pancreas was found on histological examination of the resected specimen.

The patient re-presented 1 year later with jaundice for the first time. EUS demonstrated a pseudocyst within the head of the pancreas. Endoscopic retrograde cholangiopancreatography (ERCP) revealed an isolated stenosis of the distal common bile duct (**Fig. 2a**). This was successfully treated with regularly exchanged endoprotheses, leading to a complete normalization of laboratory parameters.

The patient returned 2 years later with fever and jaundice. This time ERCP showed a purulent cholangitis with a stricture of the biliary bifurcation as well as several stenotic intrahepatic bile ducts (**Fig. 2b**). Brush cytology raised a suspicion of cholangiocarcinoma. Serum IgG4 levels, antinuclear antibody (ANA), antineutrophil cytoplasmic antibody (ANCA), anticarbonic anhydrase II and antilactoferrin antibodies were all within the normal range; however, there was peripheral eosinophilia, which can be associated with autoimmune pancreatitis (AIP) [1]. Histological re-examination of the surgical specimen revealed an impressive lymphoplasmacytic infiltration of the resected pancreas with IgG4-positive cells (**Fig. 3a, b**). This led finally to the correct diagnosis of AIP type 1 with metachronous autoimmune cholangitis. The patient was treated according to the recently published diagnostic algorithms [2–4] with long-term, slowly tapered prednisone, with resulting improvement in his clinical symptoms, biliary strictures (**Fig. 2c**), blood eosinophilia, and laboratory parameters.

In summary, distinguishing AIP from pancreatic cancer remains a pitfall for clinicians; in some cases, surgical resection remains the treatment of choice because IgG4 levels can be elevated in 10% of pancreatic cancers [5].

Endoscopy_UCTN_Code_CCL_1AZ_2AG

Competing interests: None

Fig. 1 Preoperative computed tomography (CT) scan taken 40 seconds after intravenous injection of contrast medium showing a hypodense mass located in the pancreatic body and tail, which is highly suspicious for pancreatic cancer. (Arrow indicates the transition from the pathologic to the normal parenchyma.)

H.-M. Curth[1], U. Drebber[2], D. Stippel[3], C. Bangard[4], U. Töx[1], H.-M. Steffen[1]

[1] Department of Gastroenterology and Hepatology, University of Cologne, Germany
[2] Institute of Pathology, University of Cologne, Germany
[3] Department of General, Visceral and Cancer Surgery, University of Cologne, Germany
[4] Department of Radiology, University of Cologne, Germany

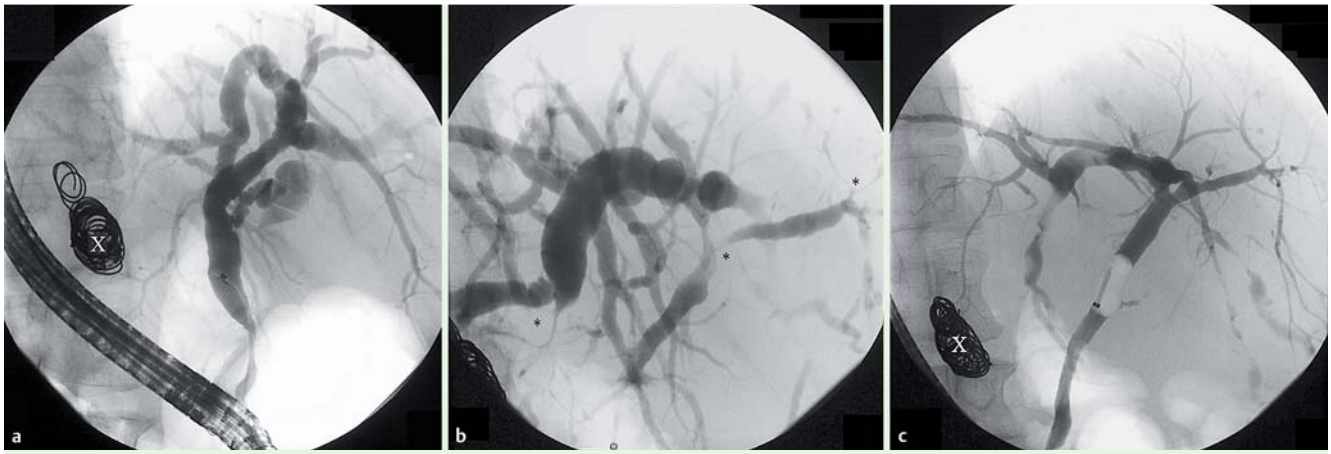

Fig. 2 Images during endoscopic retrograde cholangiopancreatography (ERCP). **a** A stenosis of the distal common bile duct is shown 1 year after surgical resection of the pancreatic mass. **b** A hilar stenosis and several intrahepatic bile duct stenoses (*) are seen 2 years later. **c** Significant improvement of the stenoses is seen following corticosteroid therapy. (X indicates coils within a splenic artery aneurysm.)

This document was downloaded for personal use only. Unauthorized distribution is strictly prohibited.

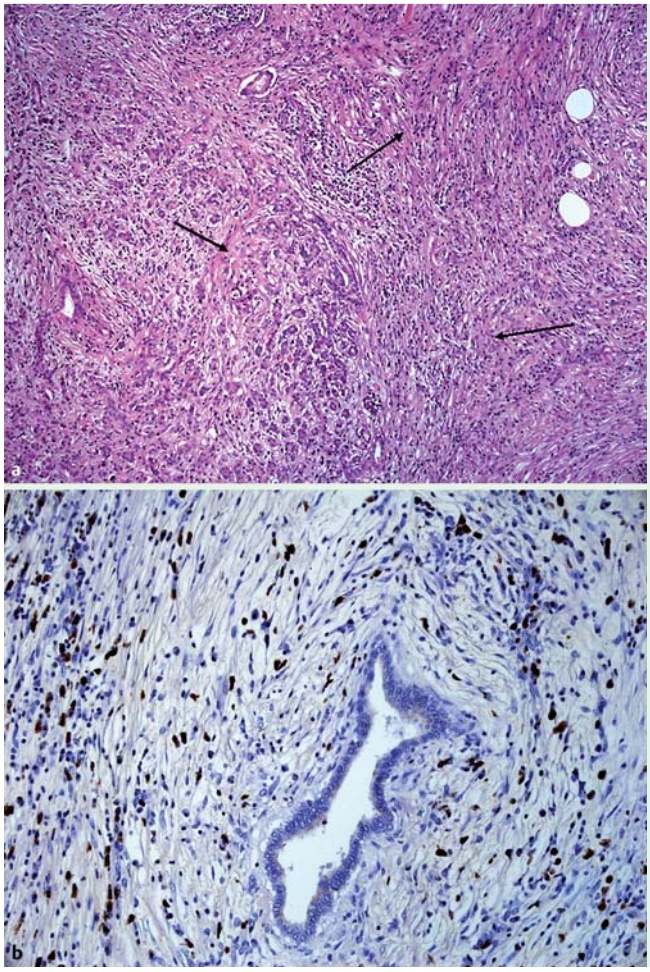

Fig. 3 Histological re-examination of the surgical specimen showing: **a** typical signs of autoimmune pancreatitis including lymphoplasmacytic infiltration with storiform fibrosis (arrows) on hematoxylin and eosin (H&E) staining; **b** cells that are positive for IgG4 (dark brown staining).

References

1 *Sah RP, Pannala R, Zhang L* et al. Eosinophilia and allergic disorders in autoimmune pancreatitis. Am J Gastroenterol 2010; 105: 2485 – 2491
2 *Otsuki M, Chung JB, Okazaki K* et al. Asian diagnostic criteria for autoimmune pancreatitis: consensus of the Japan-Korea Symposium on Autoimmune Pancreatitis. J Gastroenterol 2008; 43: 403 – 408
3 *Chari ST, Smyrk TC, Levy MJ* et al. Diagnosis of autoimmune pancreatitis: the Mayo Clinic experience. Clin Gastroenterol Hepatol 2006; 4: 1010 – 1016
4 *Maillette de Buy Wenninger L, Rauws EA, Beuers U.* What an endoscopist should know about immunoglobulin-G4-associated disease of the pancreas and biliary tree. Endoscopy 2012; 44: 66 – 73
5 *Ghazale A, Chari ST, Smyrk TC* et al. Value of serum IgG4 in the diagnosis of autoimmune pancreatitis and in distinguishing it from pancreatic cancer. Am J Gastroenterol 2007; 102: 1646 – 1653

Bibliography

DOI http://dx.doi.org/10.1055/s-0032-1309350
Endoscopy 2012; 44: E226–E227

© Georg Thieme Verlag KG

Stuttgart · New York
ISSN 0013-726X

Corresponding author

H.-M. Curth, MD
Department of Gastroenterology and Hepatology
University of Cologne
Kerpener Str. 62
50924 Cologne
Germany
Fax: +49-221-4786758
harald-morten.curth@uk-koeln.de

This document was downloaded for personal use only. Unauthorized distribution is strictly prohibited.